



National Comprehensive
Cancer Network®

NCCN Clinical Practice Guidelines in Oncology (NCCN Guidelines®)

Neuroendocrine and Adrenal Tumors

Version 4.2021 — December 14, 2021

NCCN.org

NCCN Guidelines for Patients® available at www.nccn.org/patients

Continue



National
Comprehensive
Cancer
Network®

NCCN Guidelines Version 4.2021

Neuroendocrine and Adrenal Tumors

[NCCN Guidelines Index](#)
[Table of Contents](#)
[Discussion](#)

***Manisha H. Shah, MD/Chair †**
The Ohio State University Comprehensive
Cancer Center - James Cancer Hospital
and Solove Research Institute

***Whitney S. Goldner, MD/Vice Chair ♂**
Fred & Pamela Buffett Cancer Center

***Al B. Benson, III, MD †**
Robert H. Lurie Comprehensive Cancer
Center of Northwestern University

***Emily Bergsland, MD †**
UCSF Helen Diller Family
Comprehensive Cancer Center

Lawrence S. Blaszkowsky, MD ‡
Massachusetts General Hospital
Cancer Center

***Pamela Brock, MS D**
Ohio State University Comprehensive
Cancer Center - James Cancer Hospital
and Solove Research Institute

***Jennifer Chan, MD †**
Dana-Farber/Brigham and Women's
Cancer Center

***Satya Das MD, MSCI †**
Vanderbilt-Ingram Cancer Center

Paxton V. Dickson, MD ¶
St. Jude Children's Research Hospital/
The University of Tennessee Health
Science Center

Paul Fanta, MD ‡ †
UC San Diego Moores Cancer Center

Thomas Giordano, MD, PhD ≠
University of Michigan
Rogel Cancer Center

***Thorvardur R. Halfdanarson, MD ‡ † ‡**
Mayo Clinic Cancer Center

***Daniel Halperin, MD ¶**
The University of Texas
MD Anderson Cancer Center

***Jin He, MD, PhD ¶**
The Sidney Kimmel Comprehensive Cancer
Center at Johns Hopkins

***Anthony Heaney, MD, PhD ♂**
UCLA Jonsson Comprehensive
Cancer Center

Fouad Kandeel, MD, PhD ♂
City of Hope National Medical Center

Arash Kardan, MD ϕ
Case Comprehensive Cancer Center/
University Hospitals Seidman Cancer Center
and Cleveland Clinic Taussig Cancer Institute

Syed M. Kazmi, MD †
UT Southwestern Simmons Comprehensive
Cancer Center

Sajid A. Khan, MD ¶
Yale Cancer Center/Smilow
Cancer Hospital

Edward J. Kim, MD, PhD †
UC Davis Comprehensive Cancer Center

Boris W. Kuvshinov, II, MD, MBA ¶
Roswell Park Comprehensive
Cancer Center

Christopher Lieu, MD †
University of Colorado Cancer Center

Kimberly Miller, RN ≠
Fred & Pamela Buffett Cancer Center

Diane Reidy, MD †
Memorial Sloan Kettering Cancer Center

J. Bart Rose, MD ¶
O'Neal Comprehensive Cancer Center at UAB

***Shagufta Shaheen, MD †**
Stanford Cancer Institute

Heloisa P. Soares, MD, PhD †
Huntsman Cancer Institute
at the University of Utah

***Michael C. Soulen, MD ∩**
Abramson Cancer Center at the
University of Pennsylvania

Jonathan R. Strosberg, MD †
Moffitt Cancer Center

Craig R. Sussman, MD ♂ †
Vanderbilt-Ingram Cancer Center

***Nikolaos A. Trikalinos, MD ‡ †**
Siteman Cancer Center at Barnes-Jewish
Hospital and Washington University School of
Medicine

Nataliya A. Uboha, MD, PhD †
University of Wisconsin
Carbone Cancer Center

Namrata Vijayvergia, MD †
Fox Chase Cancer Center

***Terence Wong, MD, PhD ϕ †**
Duke Cancer Institute

David B. Zhen, MD
Fred Hutchinson Cancer Research Center/
Seattle Cancer Care Alliance

NCCN
Beth McCullough, RN, BS
Cindy Hochstetler, PhD

△ Cancer genetics	† Medical oncology
⊕ Diagnostic radiology	ϕ Nuclear medicine
♂ Endocrinology	≠ Patient advocacy
‡ Hematology/Hematology oncology	≠ Pathology
‡ Internal medicine	¶ Surgery/Surgical oncology
∩ Interventional radiology	* Discussion section committee member

Continue

[NCCN Guidelines Panel Disclosures](#)



National
Comprehensive
Cancer
Network®

NCCN Guidelines Version 4.2021

Neuroendocrine and Adrenal Tumors

[NCCN Guidelines Index](#)
[Table of Contents](#)
[Discussion](#)

[NCCN Neuroendocrine Tumors Panel Members](#)
[Summary of the Guidelines Updates](#)

[Clinical Presentations and Diagnosis \(CP-1\)](#)

[Neuroendocrine Tumors of the Gastrointestinal Tract \(Well-Differentiated Grade 1/2\),
Lung, and Thymus \(NET-1\)](#)

[Neuroendocrine Tumors of the Pancreas \(Well-Differentiated Grade 1/2\) \(PanNET-1\)](#)

[Neuroendocrine Tumors of Unknown Primary \(Well-Differentiated Grade 1/2\) \(NUP-1\)](#)

[Well-Differentiated, Grade 3 Neuroendocrine Tumors \(WDG3-1\)](#)

[Poorly Differentiated Neuroendocrine Carcinoma/Large or Small Cell \(other than lung\) \(PDNEC-1\)](#)

[Adrenal Gland Tumors \(AGT-1\)](#)

[Pheochromocytoma/Paraganglioma \(PHEO-1\)](#)

[Multiple Endocrine Neoplasia, Type 1 \(MEN1-1\)](#)

[Multiple Endocrine Neoplasia, Type 2 \(MEN2-1\)](#)

[Principles of Pathology for Diagnosis and Reporting of Neuroendocrine Tumors \(NE-A\)](#)

[Principles of Imaging \(NE-B\)](#)

[Principles of Biochemical Testing \(NE-C\)](#)

[Surgical Principles for Management of Neuroendocrine Tumors \(NE-D\)](#)

[Principles of Genetic Risk Assessment and Counseling: Hereditary Endocrine Neoplasias \(NE-E\)](#)

[Principles of Systemic Anti-Tumor Therapy \(NE-F\)](#)

[Principles of Peptide Receptor Radionuclide Therapy \(PRRT\) with 177Lu-dotatate \(NE-G\)](#)

[Principles of Liver-Directed Therapy for Neuroendocrine Tumor Metastases \(NE-H\)](#)

[Principles of Hormone Control \(NE-I\)](#)

[Staging \(ST-1\)](#)

Clinical Trials: NCCN believes that the best management for any patient with cancer is in a clinical trial. Participation in clinical trials is especially encouraged.

Find an NCCN Member Institution:
<https://www.nccn.org/home/member-institutions>.

NCCN Categories of Evidence and Consensus: All recommendations are category 2A unless otherwise indicated.

See [NCCN Categories of Evidence and Consensus](#).

NCCN Categories of Preference: All recommendations are considered appropriate.

See [NCCN Categories of Preference](#).

The NCCN Guidelines® are a statement of evidence and consensus of the authors regarding their views of currently accepted approaches to treatment. Any clinician seeking to apply or consult the NCCN Guidelines is expected to use independent medical judgment in the context of individual clinical circumstances to determine any patient's care or treatment. The National Comprehensive Cancer Network® (NCCN®) makes no representations or warranties of any kind regarding their content, use or application and disclaims any responsibility for their application or use in any way. The NCCN Guidelines are copyrighted by National Comprehensive Cancer Network®. All rights reserved. The NCCN Guidelines and the illustrations herein may not be reproduced in any form without the express written permission of NCCN. ©2021.



NCCN Guidelines Version 4.2021

Neuroendocrine and Adrenal Tumors

Updates in Version 4.2021 of the NCCN Guidelines for Neuroendocrine and Adrenal Tumors from Version 3.2021 include:

[PanNET-7](#)

- Last column, new option added: Consider belzutifan in the setting of germline *VHL* alteration in patients with progressive PanNETs.

[PanNET-7A](#)

- New footnote gg added: The study excluded patients with prior systemic anticancer therapy, including anti-vascular endothelial growth factor therapy, patients needing immediate surgical intervention for tumor treatment, or patients with evidence of metastatic disease on screening imaging. Jonasch E, Donskov F, Iliopoulos O, et al. Belzutifan for renal cell carcinoma in von Hippel-Lindau disease. *N Engl J Med* 2021;385:2036-2046.

[NE-F \(3 of 6\)](#)

- Pancreatic Neuroendocrine Tumors (Well-Differentiated Grade 1/2), Useful in Certain circumstances:
 - ▶ New option added: Consider belzutifan in the setting of germline *VHL* alteration in patients with progressive PanNETs.
- New footnote h added: The study excluded patients with prior systemic anticancer therapy, including anti-vascular endothelial growth factor therapy, patients needing immediate surgical intervention for tumor treatment, or patients with evidence of metastatic disease on screening imaging.

[NE-F \(5 of 6\)](#)

- New reference added: Jonasch E, Donskov F, Iliopoulos O, et al. Belzutifan for renal cell carcinoma in von Hippel-Lindau disease. *N Engl J Med* 2021;385:2036-2046.

[MS-1](#)

- The discussion section has been updated to reflect the changes in the algorithm.

Updates in Version 3.2021 of the NCCN Guidelines for Neuroendocrine and Adrenal Tumors from Version 2.2021 include:

[PanNET-6](#)

- >1 y post-resection to a maximum of 10 y, Every 6-12 mo:
 - ▶ Third sub-bullet revised: ~~Consider a~~Abdominal multiphasic CT or MRI and chest CT (\pm contrast) as clinically indicated
 - ▶ New sub-bullet added: Chest CT (\pm contrast) as clinically indicated

[MS-1](#)

- The Discussion section has been updated to reflect the changes in the algorithm.

Updates in Version 2.2021 of the NCCN Guidelines for Neuroendocrine and Adrenal Tumors from Version 1.2021 include:

[NE-C 2 of 3](#)

- Cushing Syndrome, Testing, third bullet revised: ~~Serum~~ *Plasma* ACTH

[MS-1](#)

- The Discussion section has been updated to reflect the changes in the algorithm.

[Continued](#)

UPDATES



NCCN Guidelines Version 4.2021

Neuroendocrine and Adrenal Tumors

Updates in Version 1.2021 of the NCCN Guidelines for Neuroendocrine and Adrenal Tumors from Version 2.2020 include:

Global

- Footnotes added throughout:
 - SSR PET tracers include: 68Ga-DOTATATE, 64Cu-DOTATATE, 68Ga-DOTATOC.
 - [See Principles of Genetic Risk Assessment and Counseling \(NE-E\).](#)
- Modified "somatostatin receptor-based imaging or SSR scintigraphy" to "SSR-PET/CT or SSR-PET/MRI."
- Added "Well-Differentiated Grade 1/2" to page headings where applicable.
- Testing for inherited genetic syndromes revised: *Genetic counseling and testing for inherited genetic syndromes.*

Neuroendocrine Tumors of the Gastrointestinal Tract (Well-Differentiated Grade 1/2, Lung and Thymus)

NET-1

- Footnote g revised:
 - Should include:
 - ◊ ~~Careful manual examination palpation~~ of the entire bowel, as ~~multiple synchronous lesions~~ tumors may be present.
 - ◊ ~~Assessment of the~~ Assess for proximity to or involvement of the superior mesenteric artery and superior mesenteric vein.

NET-2

- Primary Treatment of Non-Metastatic Disease
 - Non-functioning NET and duodenal gastrinoma; revised: Local excision (transduodenal) + ~~lymph node sampling~~ regional lymphadenectomy.

NET-3

- Clinical Location, criteria modified:
 - ~~T1 (confined to the appendix)~~ Tumor ≤ 2 cm
 - ~~T2-4 or Tumor > 2 cm or Incomplete resection or Positive nodes/ margins or LVt.~~
- Evaluation:
 - Removed: Chest CT with or without contrast.
 - Removed: Biochemical evaluation as clinically indicated.
- Primary Treatment of Non-Metastatic Disease, removed: Re-exploration.
- Top pathway; surveillance modified: ~~Surveillance as clinically indicated~~ No surveillance indicated.

NET-5

- Evaluation
 - Following Hypergastrinemic/Type 1, third bullet added: After baseline gastrin, following gastrin and CgA levels is not recommended.
- Primary Treatment/Surveillance
 - Normal gastrin/Type 3 options revised: Radical resection with regional lymphadenectomy (preferred) or Consider endoscopic or surgical wedge resection (if no evidence of regional lymphadenopathy on EUS or other imaging).
- Footnote q added: May need multiple biopsies throughout the entire stomach.

NET-6

- Evaluation
 - Bullet added: Consider genetic counseling and testing for inherited genetic syndromes. (Also page NET-7)
- Primary Treatment of Non-Metastatic Disease
 - Locoregional disease (Stage IIIA/B):
 - ◊ Incomplete resection and/or positive margins pathway; revised: "carcinoid" added. (Also on NET-7)
 - ◊ Low grade (typical carcinoid); revised: Consider observation or Consider RT (category 3) ~~± cytotoxic chemotherapy.~~
- Footnote removed: Thymic neuroendocrine tumors are often associated with MEN1. See Multiple Endocrine Neoplasia, Type 1 (MEN1-1).

NET-7

- Primary Therapy
 - Localized disease (Stage I-II) options revised: ~~SBRT (if surgery contraindicated) or If surgery contraindicated, thermal ablation or SBRT (if surgery and RT is contraindicated).~~
- Footnote removed: Bronchopulmonary neuroendocrine tumors are often associated with MEN1. See Multiple Endocrine Neoplasia, Type 1 (MEN1-1). (Also on NET-10)

NET-9

- Treatment, last column: Everolimus dose removed.

[Continued](#)

UPDATES



NCCN Guidelines Version 4.2021

Neuroendocrine and Adrenal Tumors

Updates in Version 1.2021 of the NCCN Guidelines for Neuroendocrine and Adrenal Tumors from Version 2.2020 include:

NET-10

- Footnote pp revised: For symptom control, consider addition of focal therapy (~~ie, endobronchial therapy~~). (*ie, endobronchial therapy debulking, ablation*). (Also on NET-11)

NET-12

- Following Carcinoid syndrome poorly controlled, option revised: Consider additional therapy for *disease symptom* control.
- Footnote removed: Treatment with octreotide or lanreotide will likely only benefit those patients who are SSR positive.
- Footnote vv added: Evaluate for pancreatic exocrine deficiency and bile acid diarrhea.

Neuroendocrine Tumors of the Pancreas (Well-Differentiated Grade 1/2)

PanNET-1

- Evaluation, first bullet revised: Abdominal \pm *pelvis* multiphasic CT or MRI. (Also PanNET-2 through 5)
- Management of Primary Non-Metastatic Disease:
 - ▶ Small (≤ 2 cm) option revised: Observation in select cases or Enucleation \pm ~~regional nodes~~ *regional lymphadenectomy* or ~~Distal pancreatectomy \pm regional nodes/splenectomy~~ or ~~Pancreatoduodenectomy \pm regional nodes~~ *Resection \pm regional lymphadenectomy*.
 - ▶ Larger (>2 cm), invasive, or node-positive tumors pathway revised:
 - ◊ Head: Pancreatoduodenectomy + ~~regional nodes~~ *regional lymphadenectomy*.
 - ◊ Distal: Distal pancreatectomy + splenectomy + ~~regional nodes~~ *regional lymphadenectomy*.
- Footnotes:
 - ▶ Removed: For all patients with PanNET, evaluate personal and family history for possibility of MEN1 or other hereditary syndromes as appropriate. See Multiple Endocrine Neoplasia, Type 1 (MEN-1). (Also PanNET-2 through 5)
 - ▶ Footnote g revised: Observation can be considered for small (≤ 2 cm), low-grade, incidentally discovered, *non-functional* tumors. Decision based on estimated surgical risk, site of tumor, and patient comorbidities. (Sadot E, et al. Ann Surg Oncol 2016;23:1361-70.) Follow surveillance recommendations on PanNET-6.
 - ▶ Footnote j added: As appropriate, central pancreatectomy or spleen-preserving surgery should be considered.

PanNET-2

- Clinical location revised: Gastrinoma (usually ~~duodenal~~ *duodenum* or head of pancreas)
- Evaluation, bullet moved from "as appropriate" to "recommended": Genetic counseling and testing for inherited genetic syndromes.

PanNET-3

- Management of Primary Non-Metastatic Disease, Locoregional disease, following Head or Distal, option revised: Tumor enucleation, ~~consider minimally invasive resection~~.

PanNET-4

- Management of Primary Non-Metastatic Disease, following Head, option revised: Pancreatoduodenectomy + peripancreatic lymph nodes *lymphadenectomy*. (Also page PanNET-5)
- Management of Primary Non-Metastatic Disease, following Distal, option revised: Distal pancreatoduodenectomy + peripancreatic lymph nodes *lymphadenectomy* + splenectomy. (Also page PanNET-5)

PanNET-7

- Evaluation, bullet revised: Abdominal/ \pm pelvic multiphasic CT or MRI and chest CT (\pm contrast) as clinically indicated.
- Treatment, last column: Everolimus and Sunitinib dose removed.
- Footnotes:
 - ▶ Footnote dd revised: For patients with insulinoma, octreotide or lanreotide should be used only if *SSR-based imaging somatostatin* scintigraphy is positive. If used...
 - ▶ Footnote gg revised: After any prior biliary instrumentation, there are increased risks of *infectious complications* associated with liver-directed therapies.

Neuroendocrine Tumors of Unknown Primary

NUP-1

- Initial Work-up, following Primary not discovered, heading revised: Well-differentiated *grade 1/2*.
- Footnote b added: Treat presumptively as gastroenteropancreatic (GEP) NETs if it is unknown primary.

Neuroendocrine Tumors, Well-Differentiated Grade 3

WDG3-1 through WDG3-4

- New algorithm added for *Well-Differentiated, Grade 3 Neuroendocrine Tumors*.

[Continued](#)**UPDATES**



NCCN Guidelines Version 4.2021

Neuroendocrine and Adrenal Tumors

Updates in Version 1.2021 of the NCCN Guidelines for Neuroendocrine and Adrenal Tumors from Version 2.2020 include:

Poorly Differentiated Neuroendocrine Carcinoma/Large or Small Cell PDNEC-1

- Treatment, Metastatic pathway, following chemotherapy, option revised: If progression, consider ipilimumab + nivolumab for non-pancreatic NET (category 2B).
- Surveillance:
 - ▶ Top pathway revised: Every 3 mo 12 weeks for 1 y, then every 6 mo.
 - ▶ Bottom pathway revised: Every 3 mo 6–16 weeks.
- Footnotes:
 - ▶ Footnote a revised: *This page is for PDNEC and not high-grade NET.* Not all high-grade (*Ki-67* >20%) neuroendocrine cancers neoplasms are poorly differentiated. See WDG3-1. NETs with *Ki-67* index >20% may be characterized by relatively well-differentiated histology, particularly tumors with *Ki-67* index between 20%–50%. Tumors that fall into the "well-differentiated/ high-grade" category may respond relatively poorly to cisplatin/etoposide or carboplatin/etoposide, and respond more favorably to treatments described for well-differentiated NETs.
 - ▶ Footnote c revised: Somatostatin scintigraphy with SPECT/CT is not part of the routine evaluation of poorly differentiated neuroendocrine carcinomas, but may be considered for morphologically well-differentiated tumors with higher proliferation index, as appropriate. [See Principles of Imaging \(NE-B\)](#). For options for well-differentiated tumors, see [NET-10](#) or [NET-11](#).
 - ▶ Footnote d revised: Pembrolizumab can be considered for patients with mismatch repair-deficient (dMMR), microsatellite instability-high (MSI-H), or advanced tumor mutational burden-high (TMB-H) tumors (as determined by an FDA-approved test) that have progressed following prior treatment and have no satisfactory alternative treatment options.
 - ▶ Footnote e revised: Combination of pembrolizumab immune checkpoint inhibitors + chemotherapy is investigational for all patients with extrapulmonary poorly differentiated neuroendocrine carcinomas.
 - ▶ Footnotes with chemotherapy options were removed and replaced with a link to NE-F (4 of 4); where regimens are now listed.

Adrenal Gland Tumors

AGT-1

- Footnotes added:
 - ▶ For benign-appearing lesions, refer to the following guidelines for the management of adrenal incidentalomas: Zeiger MA, Thompson GB, Duh QY, et al. The American Association of Clinical Endocrinologists and American Association of Endocrine Surgeons medical guidelines for the management of adrenal incidentalomas. *Endocrine practice: official journal of the American College of Endocrinology and the American Association of Clinical Endocrinologists* 2009;15 Suppl 1:1-20; Fassnacht M, Arlt W, Bancos I, et al. Management of adrenal incidentalomas: European Society of Endocrinology Clinical Practice Guideline in collaboration with the European Network for the Study of Adrenal Tumors. *Eur J Endocrinol* 2016;175:G1-G34.
 - ▶ For benign-appearing lesions, refer to the Endocrine Society's Clinical Practice Guidelines for the Treatment of Cushing's Syndrome (Nieman LK, et al. *J Clin Endocrinol Metab* 2015;100:2807-2831).

AGT-2

- Top pathway, second column revised: *Rule out pheochromocytoma* (See NE-C). ~~Check plasma-free or 23-hour urine fractionated metanephrines (See NE-G).~~
- Footnote b added: See Principles of Biochemical Testing (NE-C). (Also page AGT-4)

[Continued](#)**UPDATES**



NCCN Guidelines Version 4.2021

Neuroendocrine and Adrenal Tumors

Updates in Version 1.2021 of the NCCN Guidelines for Neuroendocrine and Adrenal Tumors from Version 2.2020 include:

AGT-3

- Primary Treatment, top pathway, last column revised: Adrenalectomy (*minimally invasive preferred*).
- Tumor >4 cm or inhomogeneous, irregular margins, local invasion, or other malignant imaging characteristics pathway:
 - ▶ Additional evaluation:
 - ◊ First bullet added: FDG-PET/CT.
 - ◊ Third bullet revised: Abdominal/pelvic CT or MRI with contrast to ~~evaluate for metastases and local invasion.~~
 - ▶ Primary treatment, middle pathway revised: *Open* Adrenalectomy for suspected carcinoma malignancy.
- Footnote removed: If size is resectable by laparoscopy, may explore using a minimally invasive approach with planned conversion for evidence of local invasion. The decision for open versus minimally invasive surgery is based on tumor size and degree of concern regarding potential malignancy, and local surgical expertise.
- Footnote j added: Some centers may use 6 cm as cutoff.

AGT-4

- Additional Evaluation
 - ▶ Bullet added: FDG PET/CT.
 - ▶ Third bullet revised: Abdominal/pelvic CT or MRI with contrast to ~~evaluate for metastases and local invasion.~~
 - ▶ Last bullet added: Biochemical workup.
- Following evaluation:
 - ▶ Top pathway revised: *Resectable disease (intermediate-size tumor (4–6 cm) with aggressive features.*
 - ▶ Bottom pathway revised: *Unresectable or suspected metastatic disease Large tumor (>6 cm) with aggressive features.*
- Primary Treatment:
 - ▶ Top pathway revised: *Open* adrenalectomy for suspected carcinoma.
- Footnotes:
 - ▶ Removed: For benign-appearing lesions, refer to the following guidelines for the management of adrenal incidentalomas...
 - ▶ Removed: Aggressive features such as inhomogeneous, irregular margins, and local invasion.

AGT-5

- Workup
 - ▶ Second bullet revised: Consider *tumor MSI, MMR and TMB testing*.
 - ▶ Bullet removed: Biochemical evaluation (See NE-C).
 - ▶ Second option revised: *Locoregional unresectable or Metastatic disease.*
- Treatment, following Localized disease, footnotes removed from "Consider adjuvant mitotane therapy (category 3).
- Treatment, following Locoregional unresectable or Metastatic disease, options revised:
 - ▶ First bullet revised: Consider observation with chest CT ± contrast and abdominal/pelvic CT or MRI with contrast for clinically indolent disease every 3–mo 12 weeks and biomarkers (if tumor initially functional) .
 - ▶ Third bullet revised: Consider local therapy (ie, SBRT, thermal ablative therapies, *liver-directed therapy*).
 - ▶ Fourth bullet revised: Consider systemic therapy preferably in clinical trial (See *Systemic Therapy for Metastatic Adrenocortical Tumors* [AGT-A]).
 - ▶ Chemotherapy options were removed and replaced with a link to (AGT-A); where regimens are now listed.
- Follow-up, following Locoregional unresectable or Metastatic disease, added: Every 12 wk–12 mo up to 5 y (after 5 y as clinically indicated):
 - ▶ Second bullet revised: Abdominal/pelvic CT or MRI with contrast *or FDG-PET/CT*.
- Footnotes revised:
 - ▶ Footnote n: ~~Chest CT with or without contrast and abdominal/pelvic CT or MRI with contrast to evaluate for metastases and local invasion to stage disease, if not previously done. Staging workup, see AGT-4.~~
 - ▶ Footnote p: FDA-approved test recommended for determination of TMB. ~~Genetic counseling and testing for Lynch syndrome is recommended for any patient with mismatch repair-deficient adrenocortical carcinoma.~~

[Continued](#)**UPDATES**



NCCN Guidelines Version 4.2021

Neuroendocrine and Adrenal Tumors

Updates in Version 1.2021 of the NCCN Guidelines for Neuroendocrine and Adrenal Tumors from Version 2.2020 include:

AGT-5 (continued)

• Footnotes added:

- ▶ Footnote o: See Principles of Genetic Risk Assessment and Counseling (NE-E).
- ▶ Footnote s: If bulky disease, or <90% is removable, surgery can be reconsidered following response to systemic therapy.

• Footnotes removed:

- ▶ Monitor mitotane blood levels. Some institutions recommend target levels of 14–20 mcg/mL if tolerated. Steady-state levels may be reached several months after initiation of mitotane. Life-long hydrocortisone replacement may be required with mitotane.
- ▶ Mitotane may have more benefit for control of hormone symptoms than control of tumor.
- ▶ See Discussion for further information regarding the phase III FIRM-ACT trial. (Fassnacht et al. N Eng J Med 2012;366:2189-2197.)

AGT-A

- New page added: *Systemic Therapy for Locoregional Unresectable/Metastatic Adrenocortical Carcinoma.*

Paraganglioma/Pheochromocytoma

PHEO-1

• Evaluation

▶ Recommended;

- ◊ Bullet added: Adrenal protocol CT (abdomen/pelvis).
- ◊ Bullet removed: Abdominal/pelvic multiphasic CT or MRI.

▶ As appropriate

- ◊ Bullet added: Abdominal/pelvic multiphasic CT or MRI.

- Footnote removed: A high incidence of inherited disease has been reported in patients with pheochromocytoma/paraganglioma.

Certain genetic variants may require more frequent follow-up. ([See Discussion](#)) (Also page PHEO-3)

- Footnote j revised: PET/CT or PET/MRI of skull base to mid-thigh with IV contrast when possible. Data are limited on the optimal timing of scans following administration of SSAs. (Also page PHEO-3)

PHEO-3

• Surveillance

- ▶ For resectable disease, bullet revised: Consider chest CT ± contrast and abdominal/pelvic CT or MRI with contrast ~~or FDG-PET/CT.~~
- ▶ For locally unresectable disease or distant metastases, bullet revised: ~~SSR-PET/CT or SSR-PET/MRI or SSR scintigraphy (eg, 68Ga-dotatate imaging preferred [PET/CT or PET/MRI] or SSR scintigraphy).~~

Multiple Endocrine Neoplasia, Type 1

MEN1-1

- Page removed: Diagnosis of or Clinical Suspicion of MEN1 (formerly MEN1-1).
- ~~Clinical diagnosis of MEN1 or clinical suspicion of MEN1 (See MEN1-4)~~
- Bullet added: Genetic counseling and testing for inherited genetic syndromes. (Also on MEN2-1)
- Footnotes removed:
 - ▶ For MEN1 genetic testing recommendations, see MEN1-1.
 - ▶ Preference of scan will depend on institutional practice/protocol. Sestamibi scan may not be as sensitive as other imaging options since often the patient has hyperplasia. See Principles of Imaging (NE-B).
- Footnote b added: See Principles of Genetic Risk Assessment and Counseling (NE-E). (Also on MEN2-1)

MEN1-2

- MEN1 Surveillance, Parathyroid pathway,
 - ▶ If calcium rises, third sub-bullet revised: Re-image with neck ultrasound and/or parathyroid sestamibi with SPECT scan (SPECT-CT preferred) or 4D-CT.
- Footnote a removed: Preference of scan will depend on institutional practice/protocol. Sestamibi scan may not be as sensitive as other imaging options since often the patient has hyperplasia. [See Principles of Imaging \(NE-B\).](#)

MEN1-A

- Treatment of PanNETs Specific to MEN1 Patients, references added:
 - ▶ Faggiano A, Modica R, Lo Calzo F, et al. Lanreotide Therapy vs Active Surveillance in MEN1-Related Pancreatic Neuroendocrine Tumors < 2 Centimeters. J Clin Endocrinol Metab 2020;105:dgz007.
 - ▶ Niederle B, Selberherr A, Bartsch DK, et al. Multiple Endocrine Neoplasia Type 1 (MEN1) and the Pancreas: Diagnosis and Treatment of Functioning and Non-Functioning Pancreatic and Duodenal Neuroendocrine Neoplasia within the MEN1 Syndrome - An International Consensus Statement [published online ahead of print September 24, 2020]. Neuroendocrinology 2020.

[Continued](#)**UPDATES**



NCCN Guidelines Version 4.2021

Neuroendocrine and Adrenal Tumors

Updates in Version 1.2021 of the NCCN Guidelines for Neuroendocrine and Adrenal Tumors from Version 2.2020 include:

Multiple Endocrine Neoplasia, Type 2

MEN2-1

- Page removed: Diagnosis of or Clinical Suspicion of MEN2 (formerly MEN2-1).
- ~~Diagnosis of or Clinical suspicion~~ *diagnosis* of MEN2 (See MEN2-4):
 - ▶ Surveillance, middle pathway revised: ~~Calcium annually~~. See NCCN Guidelines for Medullary Thyroid Carcinoma.
 - ▶ Footnotes removed:
 - ◊ For RET genetic testing recommendations, see MEN2-1.
 - ◊ See Principles of Biochemical Testing (NE-C).

NE-A 1 of 5

- Table 1 removed from this page.
- Footnote removed: Adapted with permission from Bosman FT, Carneiro F, Hruban RH, Theise ND. World Health Organization Classification of Tumours of the Digestive System. IARC, Lyon, 2010; and Travis WD, Brambilla E, Burke AP, et al. WHO Classification of Tumours of the Lung, Pleura, Thymus and Heart. IARC, Lyon, 2015; and Lloyd RV, Osamaru RY, Klöppel G, Rosai J. WHO Classification of Tumours of Endocrine Organs. IARC, Lyon, 2017.

NE-A 2 of 5

- 2019 WHO Classification and Grading Criteria for Neuroendocrine Neoplasms of the Gastrointestinal Tract and Hepatopancreatobiliary Organs table was added to the guideline.
- Footnotes added:
 - ▶ Footnote a: Mitotic rates are to be expressed as the number of mitoses/2 mm² (equaling 10 high-power fields at 40× magnification and an ocular field diameter of 0.5 mm) as determined by counting in 50 fields of 0.2 mm² (ie, in a total area of 10 mm²); the Ki-67 proliferation index value is determined by counting at least 500 cells in the regions of highest labeling (hot spots), which are identified at scanning magnification; the final grade is based on whichever of the two proliferation indexes places the neoplasm in the higher grade category.
 - ▶ Footnote b: Poorly differentiated NECs are not formally graded but are considered high grade by definition.
 - ▶ Footnote c: In most MiNENs, both the neuroendocrine and non-neuroendocrine components are poorly differentiated, and the neuroendocrine component has proliferation indexes in the same range as other NECs, but this conceptual category allows for the possibility that one or both components may be well differentiated; when feasible, each component should therefore be graded separately.

NE-A 3 of 5

- 2015 WHO Criteria for the Diagnosis of Pulmonary NET table was added to the guideline.

NE-A 4 of 5

- Ki-67 Index, bullet added: Ki-67 immunohistochemistry should be analyzed and/or counted in the areas of highest activity referred to as "hot spots."

NE-B

- Anatomic Imaging
 - ▶ Bullet added: Consider MRI over CT to minimize radiation risk.
 - ▶ Bullet added: MRI preferred for pregnant patients.
- Functional Imaging
 - ▶ First bullet revised: Evaluation with *somatostatin receptor* (SSR) imaging to assess receptor status and distant disease is appropriate. This is especially important for determining whether a patient may benefit from SSR-directed therapy.
 - ◊ First sub-bullet revised: SSR-based imaging options include SSR-PET/CT or SSR-PET/MRI, or SSR- *Octreotide* SPECT/CT (*only if SSR-PET is not available*).
 - ◊ Second sub-bullet added: Appropriate SSR-PET tracers include 68Ga-DOTATATE, 68Ga-DOTATOC, or 64Cu-DOTATATE.
 - ◊ Third sub-bullet added: SSR-positive if uptake in measurable lesions is greater than liver.
 - ▶ Third bullet revised: SR- *Octreotide* SPECT/CT is much less sensitive for defining SSR-positive disease than SSR-PET/CT, and typically cannot be done in combination with multiphase CT or MRI. Therefore, SSR-PET/CT or SSR-PET/MRI is preferred.
 - ▶ Fourth bullet revised: In selected cases where high-grade NET or *poorly differentiated neuroendocrine carcinoma* is documented or suspected or *where disease is growing rapidly*, FDG-PET/CT may be useful to identify high-grade active disease.

[Continued](#)

UPDATES



NCCN Guidelines Version 4.2021

Neuroendocrine and Adrenal Tumors

Updates in Version 1.2021 of the NCCN Guidelines for Neuroendocrine and Adrenal Tumors from Version 2.2020 include:

[NE-B \(continued\)](#)

- Surveillance, bullet revised: After potentially curative surgery, surveillance is recommended for at least 10 years for most patients. In certain cases, surveillance may be extended beyond 10 years based on *risk* factors such as age and aggressiveness of disease *risk of recurrence*. However, data are limited on the optimal surveillance schedule beyond 10 years.
- **Transthoracic Echocardiogram (ECHO) to Assess for Carcinoid (NET-related) Heart Disease** category header was added.
 - ▶ Bullet added: Echocardiogram (transthoracic echocardiography, TTE) is important for the evaluation of carcinoid heart disease (CHD) and should include morphologic evaluation of the valves (especially tricuspid and pulmonic) and the right heart.

[NE-C 1 of 3](#)

- Bullet added: In select cases, chromogranin A may have prognostic value but treatment decisions are not based solely on changes in chromogranin.
- NETs of Gastrointestinal Tract, Lung, and Thymus, Testing, removed bullet: Chromogranin A (category 3).
- **PanNET** added to subtypes in first column of table.
- **PanNET: PPoma**
 - ▶ Clinical Symptoms revised: ~~Depends on hormone secreted, Can be clinically silent.~~
 - ▶ Testing, bullet removed: Chromogranin A (category 3).

[NE-C 2 of 3](#)

- Pheochromocytoma/Paraganglioma, Testing, second bullet revised: Cervical paragangliomas: consider serum ~~or~~ and urine dopamine catecholamines or methoxytyramine (the metabolite of dopamine).
- Cushing Syndrome, Testing, third bullet revised: ~~If hypercortisolemic, test Serum ACTH (8 am cortisol) should be done.~~
- Footnote c added: 24-hour urine for aldosterone, sodium and potassium should be considered for definitive diagnosis.
- Footnote e added: Petrosal vein sampling can be considered to differentiate adrenal from pituitary and ectopic causes.

[NE-D](#)

- This section has been significantly revised.

[NE-E](#)

- New section added: **Principles of Genetic Risk Assessment and Counseling: Hereditary Endocrine Neoplasias.**

[NE-F](#)

- "Well-Differentiated Grade 1/2" added to table headings.

[NE-F 4 of 5](#)

- Table added for **Poorly Differentiated Neuroendocrine Carcinoma/ Large or Small Cell (Extrapulmonary)** (regimens formerly listed on PDNEC-1).
- Locoregional Unresectable/Metastatic Disease:
 - ▶ Option added: FOLFIRINOX.
 - ▶ Option added: Pembrolizumab.

[NE-F 5 of 5](#)

- References updated.

[NE-G 1 of 3](#)

- Third bullet revised: ~~Currently there are no randomized data, but there are reports of treatment efficacy and favorable outcomes when PRRT is used for PanNETs, for the use of PRRT for bronchopulmonary NET, thymus NET, pheochromocytomas, or paragangliomas, ; however, PRRT may be considered if SSR-positive and progression on octreotide/lanreotide; and bronchopulmonary/thymic NETs. If feasible, participation in clinical trials of PRRT is strongly recommended for patients with such rare groups of NET.~~
- Key Eligibility, second bullet revised: SSR expression of NET as detected by ~~SSR-PET/CT or SSR-PET/MR. (ie, 68Ga-dotatate imaging preferred [PET/CT or PET/MRI] or SSR scintigraphy).~~
- Footnotes added:
 - ▶ Footnote a: See Principles of Imaging (NE-B).
 - ▶ Footnote b: PET/CT or PET/MRI of skull base to mid-thigh with IV contrast when possible. Data are limited on the optimal timing of scans following administration of SSAs.

[NE-G 3 of 3](#)

- References updated.

[Continued](#)

UPDATES



Updates in Version 1.2021 of the NCCN Guidelines for Neuroendocrine and Adrenal Tumors from Version 2.2020 include:

NE-H

- Indications for Hepatic Arterial Embolization, third bullet: 10% after TARE changed to 8%.
- Embolization Modalities
 - TAE and TACE, third sub-bullet revised: ...Overnight observation is typically appropriate to monitor and treat symptoms of post-embolization syndrome such as pain and nausea *and exacerbation of hormone-related symptoms*.
 - TARE (category 2B) *may be considered particularly in the following scenarios:*
 - ◊ Sub-bullets added:
 - Lobar or segmental (less than lobular) disease distribution.
 - Patients with prior Whipple surgery or biliary tract instrumentation (lower risk of hepatobiliary infection than TAE/TACE)
 - TARE is better tolerated than TAE/TACE, but late radioembolization-induced chronic hepatotoxicity (RECHT) may occur in long-term survivors, and is particularly a concern among patients undergoing bilobar radioembolization.
 - ◊ Sub-bullets removed:
 - Routine use of radioembolization (TARE) using yttrium-90 microspheres is controversial.
 - Short-term side effects are milder than observed with TAE or TACE, but late radioembolization-induced chronic liver toxicity (RECHT) occurs in 10%–20% of long-term survivors in retrospective series, and is particularly a concern among patients with bilobar disease.
 - TARE may be most appropriate for patients with prior biliary interventions due to the lower risk of abscess.
- Ablative Therapy (category 2B)
 - Bullet removed: Includes ablative techniques such as radiofrequency, microwave, and cryotherapy. There are no randomized clinical trials and prospective data for these interventions are limited. However, data on the use of these interventions are emerging.
 - Bullet revised: Percutaneous thermal ablation, often using microwave energy (*radiofrequency and cryoablation are also acceptable*), can be considered for oligometastatic liver disease, generally up to four lesions each smaller than 3 cm. Feasibility considerations include ~~conspicuity on CT or ultrasound~~, a safe percutaneous *imaging-guided* approach to the target lesions, and proximity to vessels, bile ducts, or adjacent non-target structures that may require hydro- or aero-dissection for displacement.
 - References added.

ST-2

- Heading revised: American Joint Committee on Cancer (AJCC) TNM Staging System for *Well-Differentiated* Neuroendocrine Tumors of the Duodenum and Ampulla of Vater (8th ed., 2017).

ST-12

- Table 21 heading revised: *Thymus Ampulla of Vater (high-grade neuroendocrine carcinoma)*.

**CLINICAL PRESENTATIONS AND DIAGNOSIS^a****Neuroendocrine Tumors of the Gastrointestinal Tract (Well-Differentiated Grade 1/2)^b, Lung, and Thymus****Clinical presentations:**

- Jejunal, ileal, colon ([See NET-1](#))
- Duodenal ([See NET-2](#))
- Appendix ([See NET-3](#))
- Rectal ([See NET-4](#))
- Gastric ([See NET-5](#))
- Thymus ([See NET-6](#))
- Bronchopulmonary, NET ([See NET-7](#))
- Locoregional advanced disease and/or distant metastases of the GI tract ([See NET-9](#))
- Locoregional unresectable Bronchopulmonary/Thymic NET ([See NET-10](#))
- Distant metastatic Bronchopulmonary/Thymic NET ([See NET-11](#))
- Carcinoid syndrome ([See NET-12](#))

Neuroendocrine Tumors of the Pancreas (Well-Differentiated Grade 1/2)^b**Clinical presentations:**

- Nonfunctioning pancreatic tumors ([See PanNET-1](#))
- Gastrinoma ([See PanNET-2](#))
- Insulinoma ([See PanNET-3](#))
- Glucagonoma ([See PanNET-4](#))
- VIPoma ([See PanNET-5](#))
- Locoregional unresectable disease and/or distant metastases ([See PanNET-7](#))

Neuroendocrine Tumors of Unknown Primary (Well-Differentiated Grade 1/2) ([See NUP-1](#))^b**Well-Differentiated, Grade 3 Neuroendocrine Tumors ([See WDG3-1](#))****Extrapulmonary: Poorly differentiated neuroendocrine carcinoma/Large or small cell carcinoma other than lung/Unknown primary (poorly differentiated) ([See PDNEC-1](#))****Adrenal Gland Tumors ([See AGT-1](#))^c****Pheochromocytoma/Paraganglioma ([See PHEO-1](#))****Multiple Endocrine Neoplasia, Type 1 ([See MEN1-1](#))**

- Parathyroid
- Pancreatic neuroendocrine tumors (PanNETs)
- Pituitary tumor
- Bronchial/thymic

Multiple Endocrine Neoplasia, Type 2 ([See MEN2-1](#))

- Medullary thyroid carcinoma ([Also see NCCN Guidelines for Thyroid Carcinoma](#))
- Parathyroid
- Pheochromocytoma

Merkel Cell Carcinoma ([See NCCN Guidelines for Merkel Cell Carcinoma](#))^a [See Principles of Pathology for Diagnosis and Reporting of Neuroendocrine Tumors \(NE-A\).](#)^b For well-differentiated grade 3 NET, [see WDG3-1](#). For poorly differentiated/large or small cell carcinomas, [see PDNEC-1](#).^c Includes adrenal cortical tumors and incidentalomas.**Note:** All recommendations are category 2A unless otherwise indicated.**Clinical Trials:** NCCN believes that the best management of any patient with cancer is in a clinical trial. Participation in clinical trials is especially encouraged.



National
Comprehensive
Cancer
Network®

NCCN Guidelines Version 4.2021

Neuroendocrine Tumors of the Gastrointestinal Tract (Well-Differentiated Grade 1/2), Lung, and Thymus

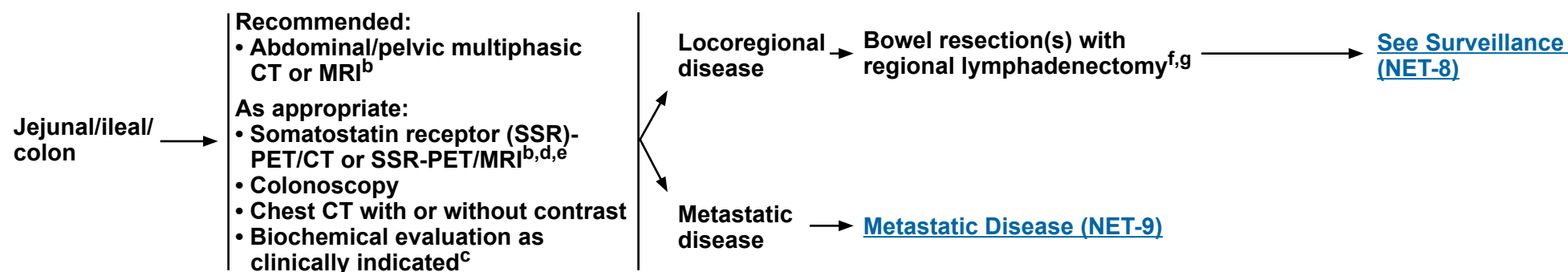
[NCCN Guidelines Index](#)
[Table of Contents](#)
[Discussion](#)

CLINICAL LOCATION

EVALUATION^{a,b,c}

PRIMARY TREATMENT OF NON-METASTATIC DISEASE^f

SURVEILLANCE



^a [See Principles of Pathology for Diagnosis and Reporting of Neuroendocrine Tumors \(NE-A\).](#)

^b [See Principles of Imaging \(NE-B\).](#)

^c [See Principles of Biochemical Testing \(NE-C\).](#)

^d PET/CT or PET/MRI of skull base to mid-thigh with IV contrast when possible. Data are limited on the optimal timing of scans following administration of somatostatin analogs (SSAs).

^e SSR PET tracers include: 68Ga-DOTATATE, 64Cu-DOTATATE, 68Ga-DOTATOC.

^f [See Surgical Principles for Management of Neuroendocrine Tumors \(NE-D\).](#)

^g Should include:

- Manual palpation of the entire bowel, as synchronous tumors may be present.
- Assess for proximity to or involvement of the superior mesenteric artery and vein.

Note: All recommendations are category 2A unless otherwise indicated.

Clinical Trials: NCCN believes that the best management of any patient with cancer is in a clinical trial. Participation in clinical trials is especially encouraged.

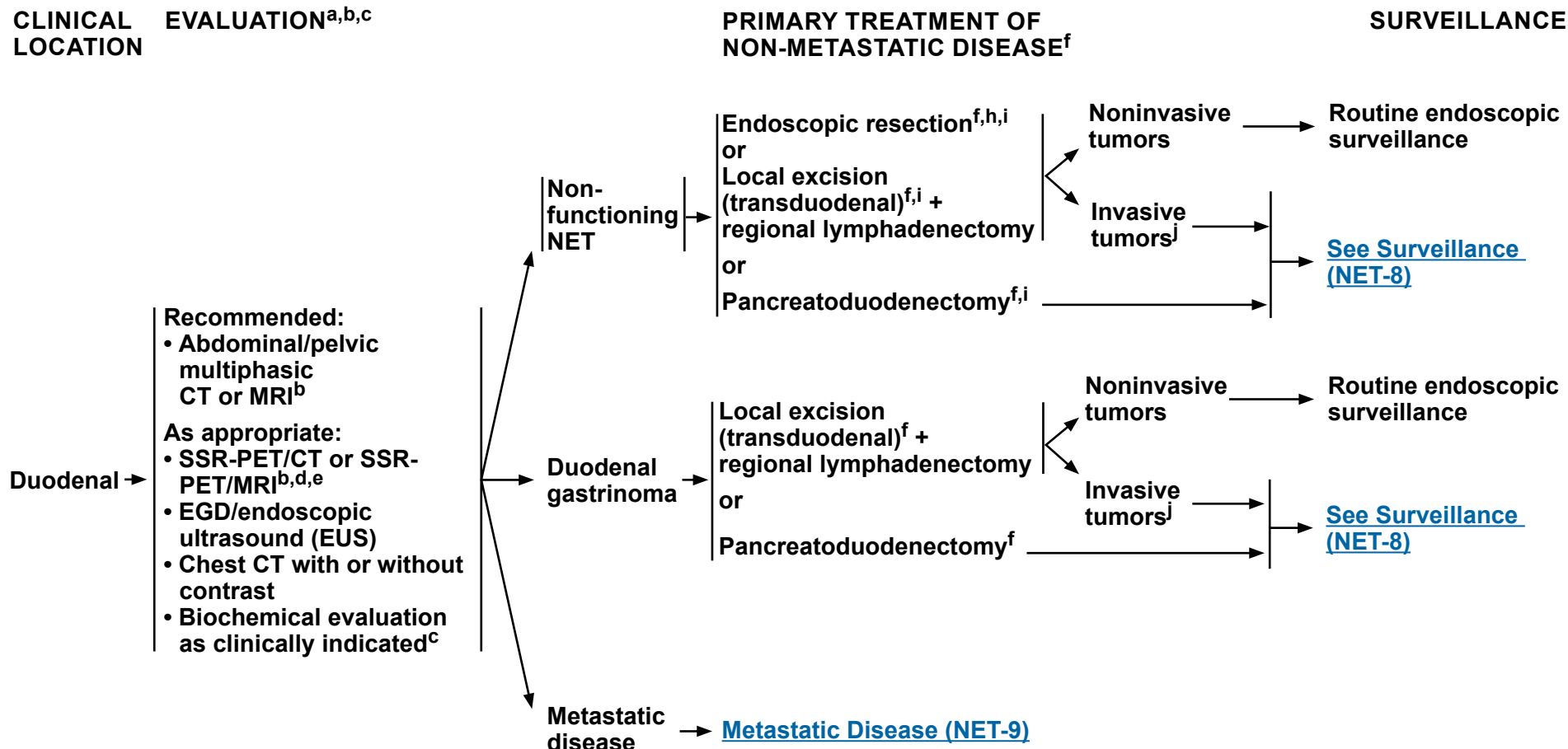


National
Comprehensive
Cancer
Network®

NCCN Guidelines Version 4.2021

Neuroendocrine Tumors of the Gastrointestinal Tract (Well-Differentiated Grade 1/2), Lung, and Thymus

[NCCN Guidelines Index](#)
[Table of Contents](#)
[Discussion](#)



^a [See Principles of Pathology for Diagnosis and Reporting of Neuroendocrine Tumors \(NE-A\).](#)

^b [See Principles of Imaging \(NE-B\).](#)

^c [See Principles of Biochemical Testing \(NE-C\).](#)

^d PET/CT or PET/MRI of skull base to mid-thigh with IV contrast when possible. Data are limited on the optimal timing of scans following administration of SSAs.

^e SSR PET tracers include: 68Ga-DOTATATE, 64Cu-DOTATATE, 68Ga-DOTATOC.

^f [See Surgical Principles for Management of Neuroendocrine Tumors \(NE-D\).](#)

^h If endoscopic resection performed, follow-up EGD as appropriate.

ⁱ For non-ampullary tumors, endoscopic or local excision is preferred. Pancreatoduodenectomy should be considered for ampullary tumors not amenable to endoscopic or local excision.

^j Invasion into muscle ([see Staging, ST-2](#)).

Note: All recommendations are category 2A unless otherwise indicated.

Clinical Trials: NCCN believes that the best management of any patient with cancer is in a clinical trial. Participation in clinical trials is especially encouraged.

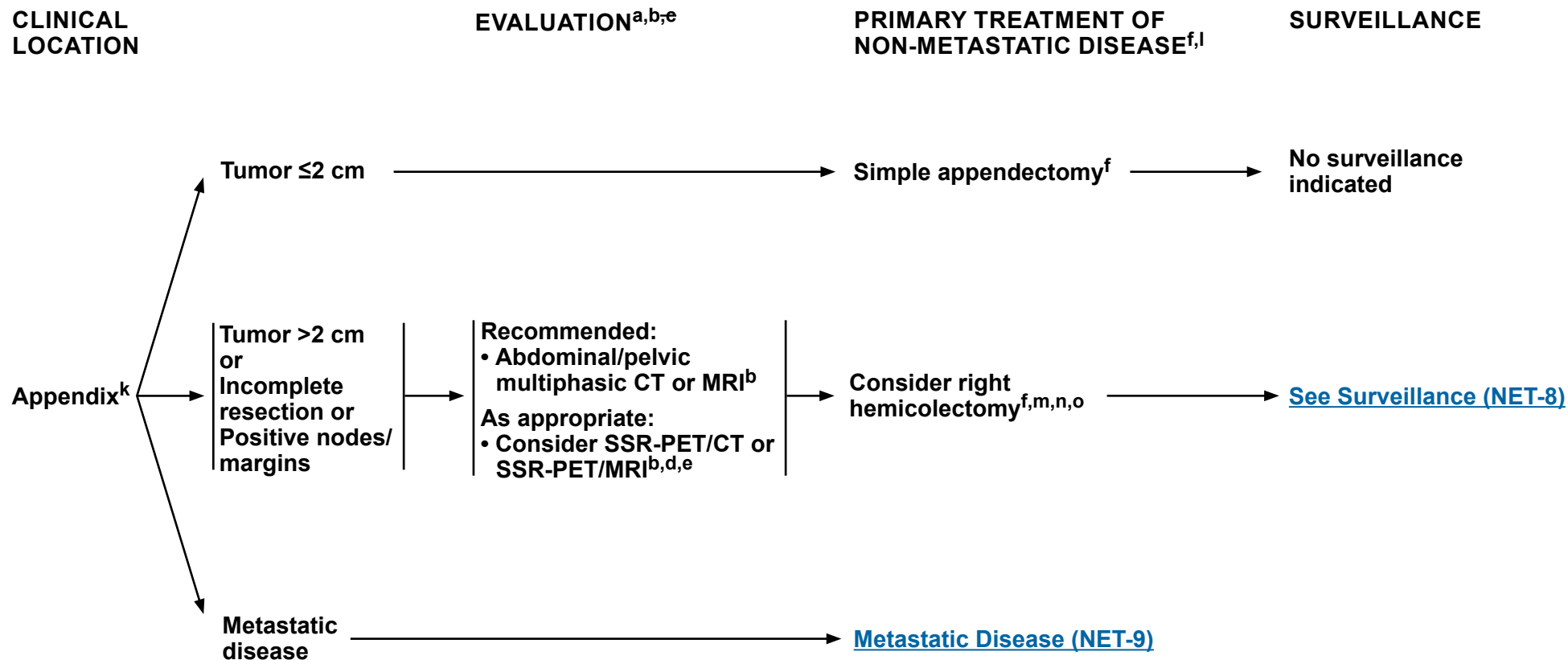


National
Comprehensive
Cancer
Network®

NCCN Guidelines Version 4.2021

Neuroendocrine Tumors of the Gastrointestinal Tract (Well-Differentiated Grade 1/2), Lung, and Thymus

[NCCN Guidelines Index](#)
[Table of Contents](#)
[Discussion](#)



^a See [Principles of Pathology for Diagnosis and Reporting of Neuroendocrine Tumors \(NE-A\)](#).

^b See [Principles of Imaging \(NE-B\)](#).

^d PET/CT or PET/MRI of skull base to mid-thigh with IV contrast when possible. Data are limited on the optimal timing of scans following administration of SSAs.

^e SSR PET tracers include: 68Ga-DOTATATE, 64Cu-DOTATATE, 68Ga-DOTATOC.

^f See [Surgical Principles for Management of Neuroendocrine Tumors \(NE-D\)](#).

^k Some appendiceal neuroendocrine tumors will have mixed histology, including elements of adenocarcinoma. Such tumors should be managed according to colon cancer guidelines. See [NCCN Guidelines for Colon Cancer](#).

^l Some institutions will consider more aggressive treatments for 1- to 2-cm tumors with poor prognostic features. See [Discussion](#) for details.

^m See [Staging \(ST-6\)](#). Patients with tumors <2 cm that do not invade beyond the mesoappendix can be considered for observation, after patient-physician discussion. Heller D, et al. J Am Coll Surg 2019;228:839-851.

ⁿ Greater than 12 lymph nodes should be retrieved.

^o Data are limited on survival benefit from right hemicolectomy.

Note: All recommendations are category 2A unless otherwise indicated.

Clinical Trials: NCCN believes that the best management of any patient with cancer is in a clinical trial. Participation in clinical trials is especially encouraged.

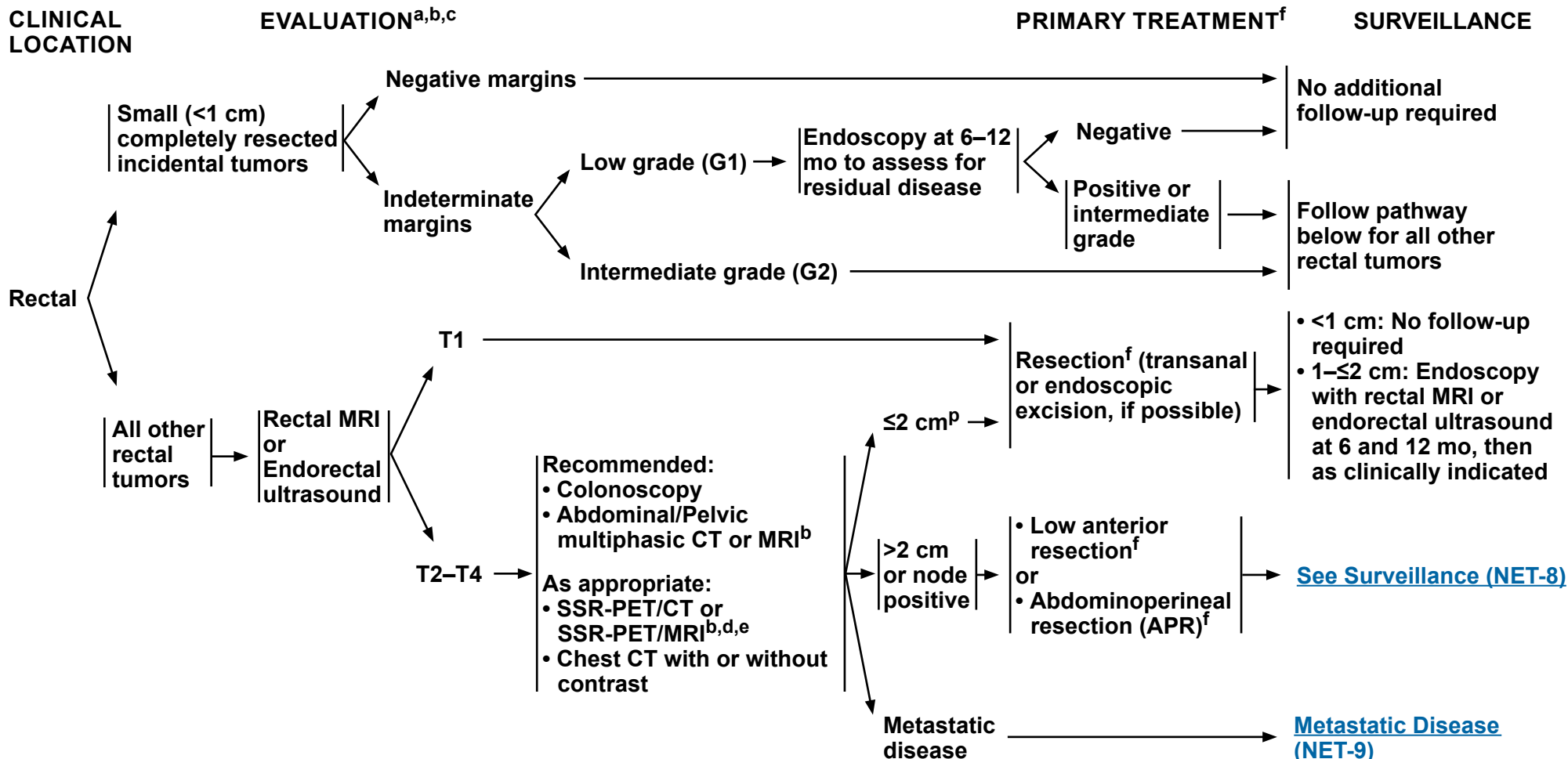


National
Comprehensive
Cancer
Network®

NCCN Guidelines Version 4.2021

Neuroendocrine Tumors of the Gastrointestinal Tract (Well-Differentiated Grade 1/2), Lung, and Thymus

[NCCN Guidelines Index](#)
[Table of Contents](#)
[Discussion](#)



^a See Principles of Pathology for Diagnosis and Reporting of Neuroendocrine Tumors (NE-A).

^b See Principles of Imaging (NE-B).

^c See Principles of Biochemical Testing (NE-C).

^d PET/CT or PET/MRI of skull base to mid-thigh with IV contrast when possible. Data are limited on the optimal timing of scans following administration of SSAs.

^e SSR PET tracers include: 68Ga-DOTATATE, 64Cu-DOTATATE, 68Ga-DOTATOC.

^f See Surgical Principles for Management of Neuroendocrine Tumors (NE-D).

^p For 1- to 2-cm tumors, consider examination under anesthesia (EUA) and/or EUS with radical resection if muscularis propria invasion or node positive.

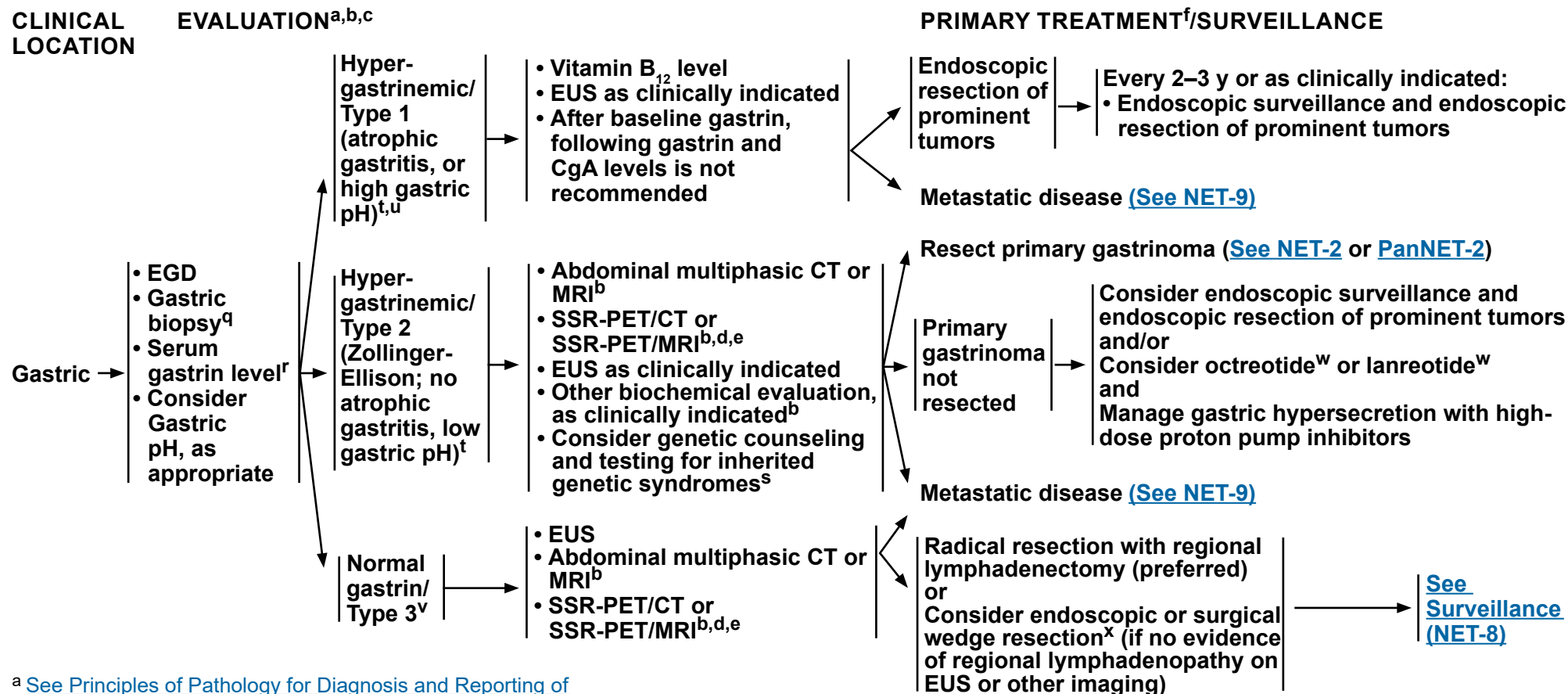
Note: All recommendations are category 2A unless otherwise indicated.

Clinical Trials: NCCN believes that the best management of any patient with cancer is in a clinical trial. Participation in clinical trials is especially encouraged.



NCCN Guidelines Version 4.2021

Neuroendocrine Tumors of the Gastrointestinal Tract (Well-Differentiated Grade 1/2), Lung, and Thymus



^a See Principles of Pathology for Diagnosis and Reporting of Neuroendocrine Tumors (NE-A).

^b See Principles of Imaging (NE-B).

^c See Principles of Biochemical Testing (NE-C).

^d PET/CT or PET/MRI of skull base to mid-thigh with IV contrast when possible. Data are limited on the optimal timing of scans following administration of SSAs.

^e SSR PET tracers include: 68Ga-DOTATATE, 64Cu-DOTATATE, 68Ga-DOTATOC.

^f See Surgical Principles for Management of Neuroendocrine Tumors (NE-D).

^q May need multiple biopsies throughout the entire stomach.

^r Serum gastrin can be falsely elevated with proton pump inhibitor (PPI) use. To confirm diagnosis, it should ideally be checked when fasting and off PPI for >1 week. However, PPI should be continued in patients with overt clinical symptoms of gastrinoma and/or risks of complications.

^s See Principles of Genetic Risk Assessment and Counseling (NE-E).

^t Elevated gastrin levels are usually suggestive of type 1 or type 2 tumors.

^u For rare, >2 cm, type 1 gastric tumors, workup should include multiphasic CT or MRI of the abdomen. For metastatic disease, [NET-11](#).

^v Type 3 gastric neuroendocrine tumors are sporadic and unifocal.

^w See Principles of Systemic Anti-Tumor Therapy (NE-F).

^x Endoscopic resection should be reserved for small (<1 cm), superficial, low-grade tumors.

Note: All recommendations are category 2A unless otherwise indicated.

Clinical Trials: NCCN believes that the best management of any patient with cancer is in a clinical trial. Participation in clinical trials is especially encouraged.

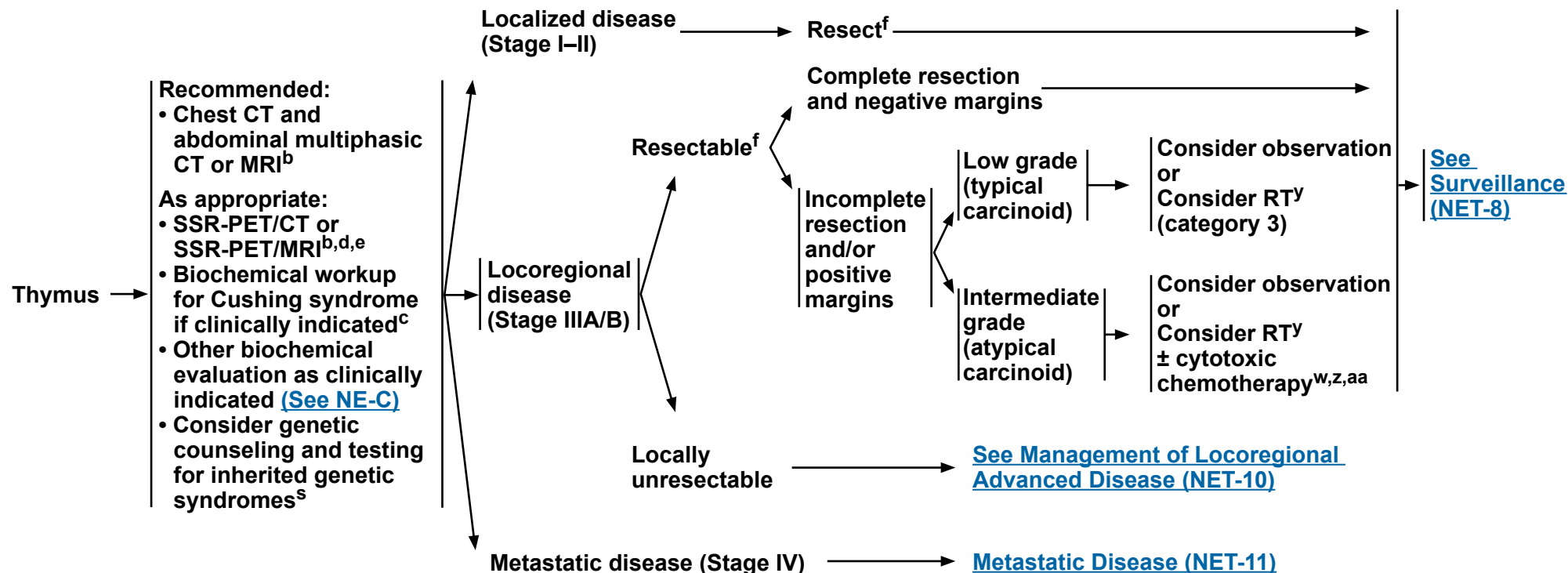


NCCN Guidelines Version 4.2021

Neuroendocrine Tumors of the Gastrointestinal Tract (Well-Differentiated Grade 1/2), Lung, and Thymus

CLINICAL LOCATION

EVALUATION^{a,b,c}



^a [See Principles of Pathology for Diagnosis and Reporting of Neuroendocrine Tumors \(NE-A\).](#)

^b [See Principles of Imaging \(NE-B\).](#)

^c [See Principles of Biochemical Testing \(NE-C\).](#)

^d PET/CT or PET/MRI of skull base to mid-thigh with IV contrast when possible. Data are limited on the optimal timing of scans following administration of SSAs.

^e SSR PET tracers include: 68Ga-DOTATATE, 64Cu-DOTATATE, 68Ga-DOTATOC.

^f [See Surgical Principles for Management of Neuroendocrine Tumors \(NE-D\).](#)

^s [See Principles of Genetic Risk Assessment and Counseling \(NE-E\).](#)

^w [See Principles of Systemic Anti-Tumor Therapy \(NE-F\).](#)

^y There is a gap issue and therapeutic challenge in managing patients who fall into this category due to a lack of data. However, the panel suggests use of these options in select cases or as needed.

^z Chemoradiation is thought to have most efficacy for tumors with atypical histology or tumors with higher mitotic and proliferative indices (eg, Ki-67).

^{aa} Cytotoxic chemotherapy options include cisplatin + etoposide, or carboplatin + etoposide.

Note: All recommendations are category 2A unless otherwise indicated.

Clinical Trials: NCCN believes that the best management of any patient with cancer is in a clinical trial. Participation in clinical trials is especially encouraged.

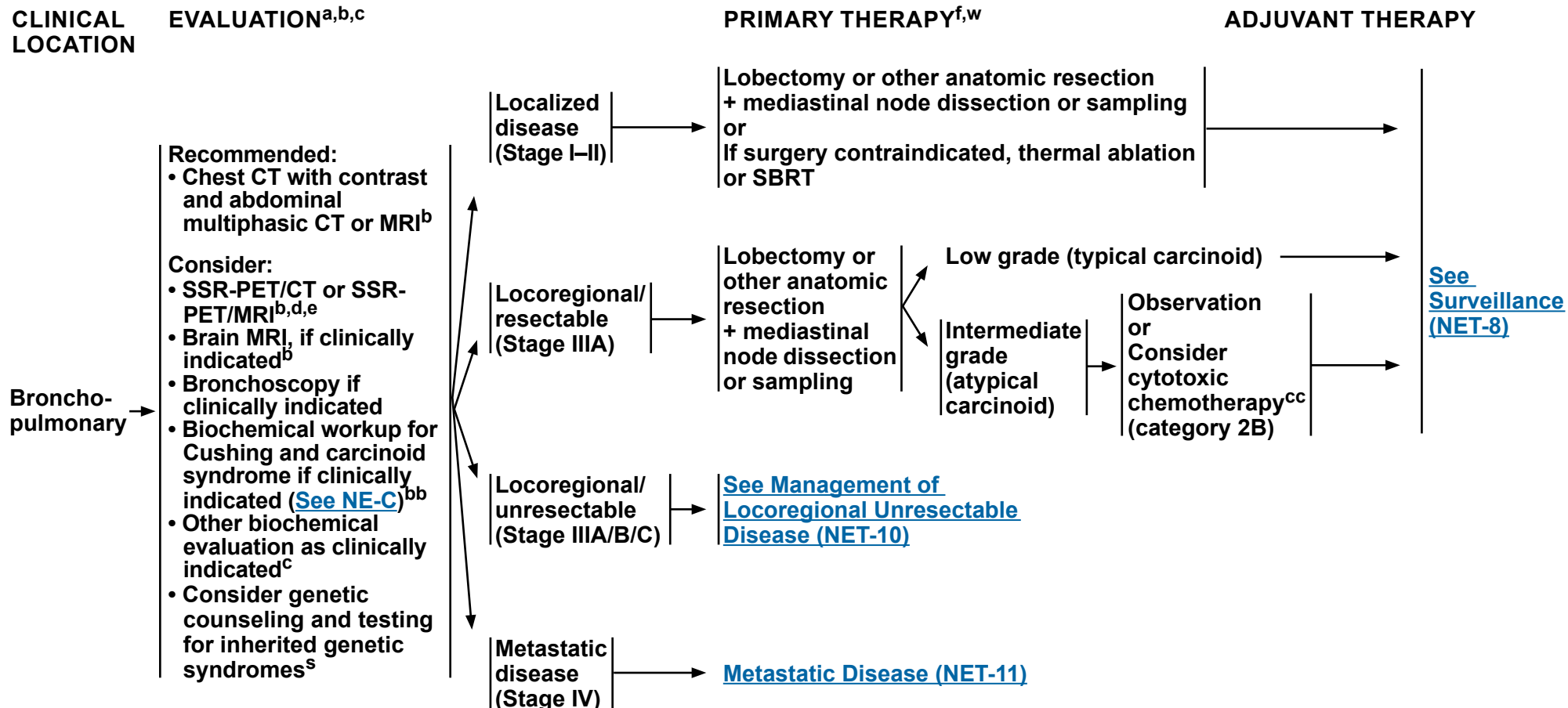


National
Comprehensive
Cancer
Network®

NCCN Guidelines Version 4.2021

Neuroendocrine Tumors of the Gastrointestinal Tract (Well-Differentiated Grade 1/2), Lung, and Thymus

[NCCN Guidelines Index](#)
[Table of Contents](#)
[Discussion](#)



^a See Principles of Pathology for Diagnosis and Reporting of Neuroendocrine Tumors (NE-A).

^b See Principles of Imaging (NE-B).

^c See Principles of Biochemical Testing (NE-C).

^d PET/CT or PET/MRI of skull base to mid-thigh with IV contrast when possible. Data are limited on the optimal timing of scans following administration of SSAs.

^e SSR PET tracers include: 68Ga-DOTATATE, 64Cu-DOTATATE, 68Ga-DOTATOC.

^f See Surgical Principles for Management of Neuroendocrine Tumors (NE-D).

^s See Principles of Genetic Risk Assessment and Counseling (NE-E).

^w See Principles of Systemic Anti-Tumor Therapy (NE-F).

^{bb} If Cushing syndrome is suspected, assess for and treat ectopic sources of ACTH production.

^{cc} Cytotoxic chemotherapy options include cisplatin + etoposide, carboplatin + etoposide, or temozolomide. There are limited data on the efficacy of chemotherapy for stage III atypical bronchopulmonary NET.

Note: All recommendations are category 2A unless otherwise indicated.

Clinical Trials: NCCN believes that the best management of any patient with cancer is in a clinical trial. Participation in clinical trials is especially encouraged.



NCCN Guidelines Version 4.2021

Neuroendocrine Tumors of the Gastrointestinal Tract (Well-Differentiated Grade 1/2), Lung, and Thymus

SURVEILLANCE^{c,dd,ee,ff} GI TRACT, LUNG, AND THYMUS

RECURRENT DISEASE

MANAGEMENT OF RECURRENT DISEASE^f

12 wk–12 mo post-resection:

- H&P
- Consider biochemical markers as clinically indicated ([See NE-C](#))^c
- Abdominal ± pelvic multiphasic CT or MRI as clinically indicated^b
- Chest CT with or without contrast for primary lung/thymus tumors (as clinically indicated for primary GI tumors)

>1 y post-resection to 10 y:

- Every 12–24 mo
 - ▶ H&P
 - ▶ Consider biochemical markers as clinically indicated ([See NE-C](#))^c
 - ▶ Abdominal ± pelvic multiphasic CT or MRI^c
 - ▶ Chest CT with or without contrast for primary lung/thymus tumors (as clinically indicated for primary GI tumors)^b

>10 y:

- Consider surveillance as clinically indicated^{b,gg}

Disease recurrence^{hh}

GI Tract

[See Management of Locoregional Advanced Disease and/or Distant Metastases \(NET-9\)](#)

Bronchopulmonary/
Thymus

[See Management of Locoregional Unresectable Disease \(NET-10\)](#)
or
[See Management of Distant Metastases \(NET-11\)](#)

Carcinoid
Syndrome

[See Management of Carcinoid Syndrome \(NET-12\)](#)

^b [See Principles of Imaging \(NE-B\).](#)

^c [See Principles of Biochemical Testing \(NE-C\).](#)

^f [See Surgical Principles for Management of Neuroendocrine Tumors \(NE-D\).](#)

^{dd} Earlier, if symptoms. If initial scans are negative, the frequency of follow-up scans may decrease. For high-grade tumors, more frequent surveillance may be appropriate.

^{ee} SSR-based imaging and FDG-PET/CT scan are not recommended for routine surveillance.

^{ff} [See NCCN Guidelines for Survivorship.](#)

^{gg} Singh S, et al. JAMA Oncol 2018;4:1597-1604.

^{hh} In select cases, resection may be considered.

Note: All recommendations are category 2A unless otherwise indicated.

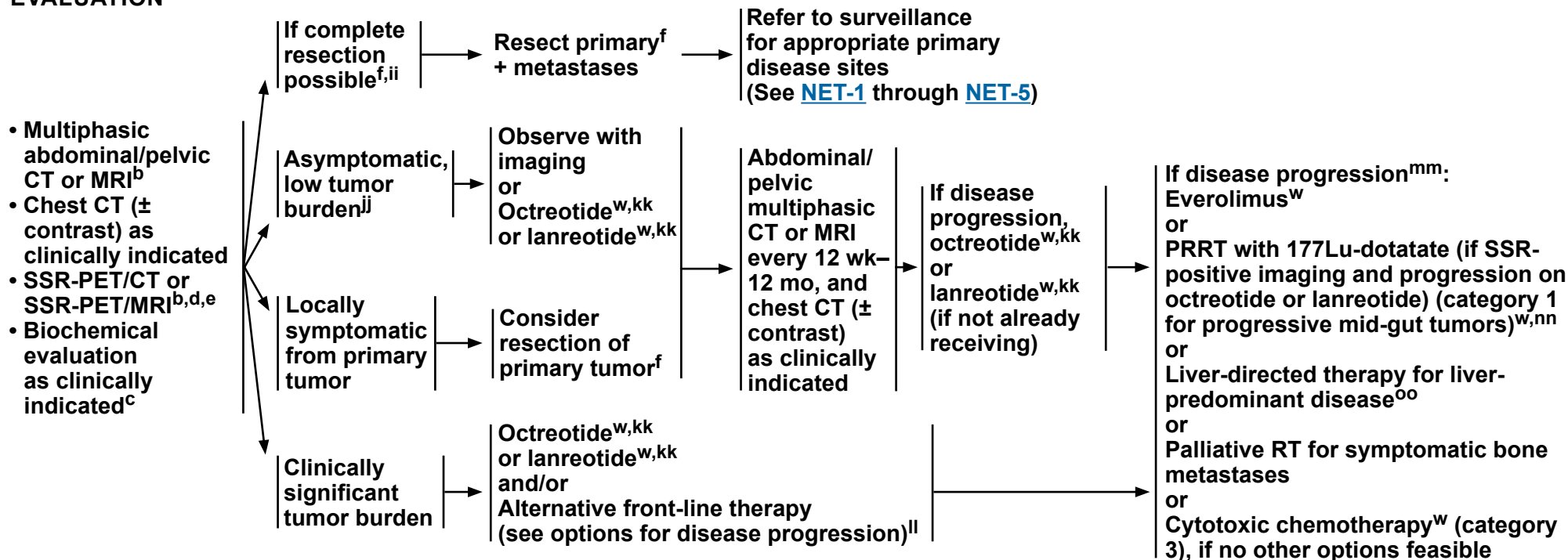
Clinical Trials: NCCN believes that the best management of any patient with cancer is in a clinical trial. Participation in clinical trials is especially encouraged.



NCCN Guidelines Version 4.2021

Neuroendocrine Tumors of the Gastrointestinal Tract (Well-Differentiated Grade 1/2), Lung, and Thymus

MANAGEMENT OF LOCOREGIONAL ADVANCED DISEASE AND/OR DISTANT METASTASES GASTROINTESTINAL TRACT EVALUATION^{b,c}



^b See [Principles of Imaging \(NE-B\)](#).

^c See [Principles of Biochemical Testing \(NE-C\)](#).

^d PET/CT or PET/MRI of skull base to mid-thigh with IV contrast when possible. Data are limited on the optimal timing of scans following administration of SSAs.

^e SSR PET tracers include: 68Ga-DOTATATE, 64Cu-DOTATATE, 68Ga-DOTATOC.

^f See [Surgical Principles for Management of Neuroendocrine Tumors \(NE-D\)](#).

^w See [Principles of Systemic Anti-Tumor Therapy \(NE-F\)](#).

ⁱⁱ Noncurative debulking surgery might be considered in select cases.

^{jj} Resection of a small asymptomatic (relatively stable) primary in the presence of unresectable metastatic disease is not indicated. However, taking a careful history is recommended as surgery may be an option for asymptomatic patients with previous, intermittent obstructions.

^{kk} Treatment with octreotide or lanreotide will likely only benefit those patients who are SSR-positive.

^{ll} In select cases it may be appropriate to proceed to front-line systemic therapy or liver-directed therapy prior to or concurrently with octreotide or lanreotide.

^{mm} If disease progression, treatment with octreotide or lanreotide should be discontinued for non-functional tumors and continued in patients with functional tumors; those regimens may be used in combination with any of the subsequent options. For details on the administration of octreotide or lanreotide with 177Lu-dotatate, see [NE-G](#).

ⁿⁿ See [Principles of Peptide Receptor Radionuclide Therapy \(PRRT\) with 177Lu-dotatate \(NE-G\)](#).

^{oo} See [Principles of Liver-Directed Therapy for Neuroendocrine Tumor Metastases \(NE-H\)](#).

Note: All recommendations are category 2A unless otherwise indicated.

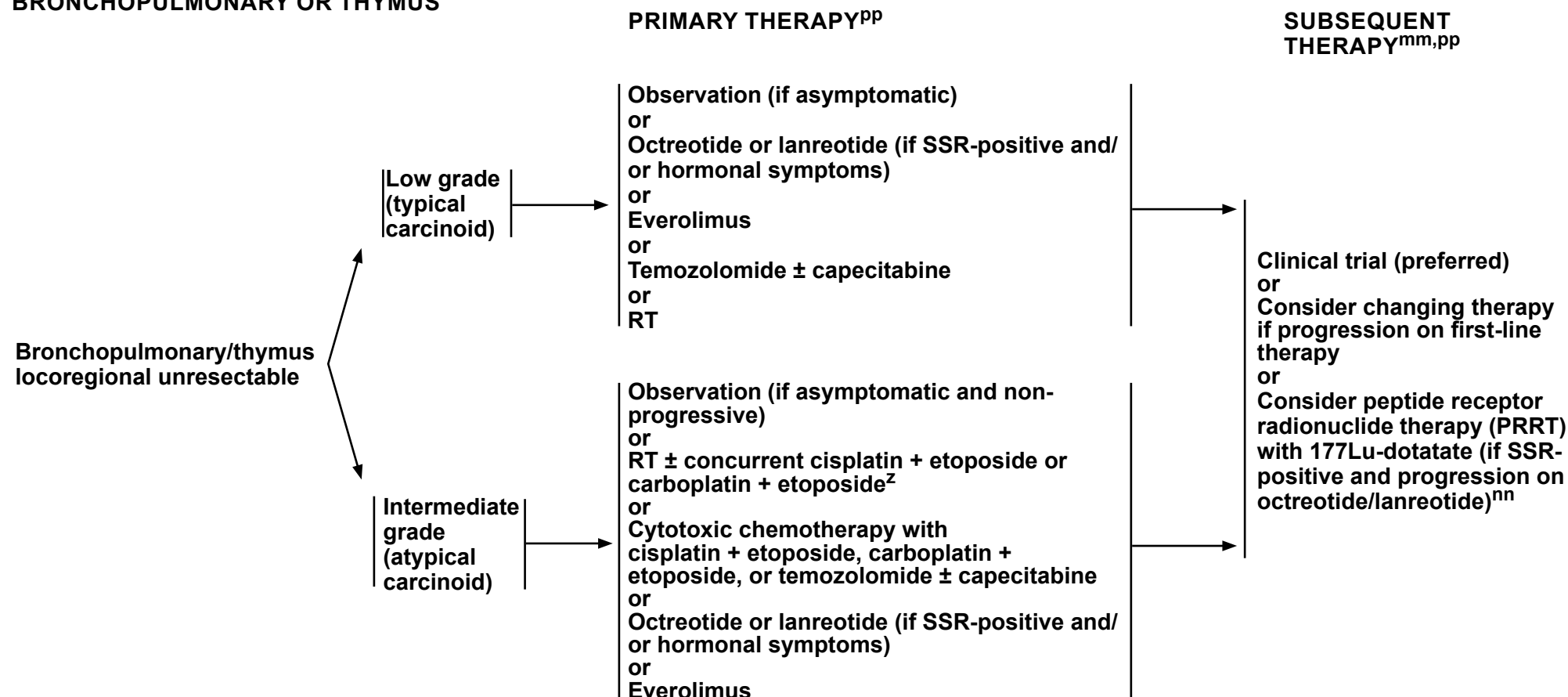
Clinical Trials: NCCN believes that the best management of any patient with cancer is in a clinical trial. Participation in clinical trials is especially encouraged.



NCCN Guidelines Version 4.2021

Neuroendocrine Tumors of the Gastrointestinal Tract (Well-Differentiated Grade 1/2), Lung, and Thymus

MANAGEMENT OF LOCOREGIONAL UNRESECTABLE DISEASE BRONCHOPULMONARY OR THYMUS



^z Chemoradiation is thought to have most efficacy for tumors with atypical histology or tumors with higher mitotic and proliferative indices (eg, Ki-67).

^{mm} If disease progression, treatment with octreotide or lanreotide should be discontinued for non-functional tumors and continued in patients with functional tumors; those regimens may be used in combination with any of the subsequent options. For details on the administration of octreotide or lanreotide with ¹⁷⁷Lu-dotatate, [see NE-G](#).

ⁿⁿ [See Principles of Peptide Receptor Radionuclide Therapy \(PRRT\) with ¹⁷⁷Lu-dotatate \(NE-G\)](#).

^{pp} For symptom control, consider addition of focal therapy (ie, endobronchial therapy debulking, ablation).

Note: All recommendations are category 2A unless otherwise indicated.

Clinical Trials: NCCN believes that the best management of any patient with cancer is in a clinical trial. Participation in clinical trials is especially encouraged.



National
Comprehensive
Cancer
Network®

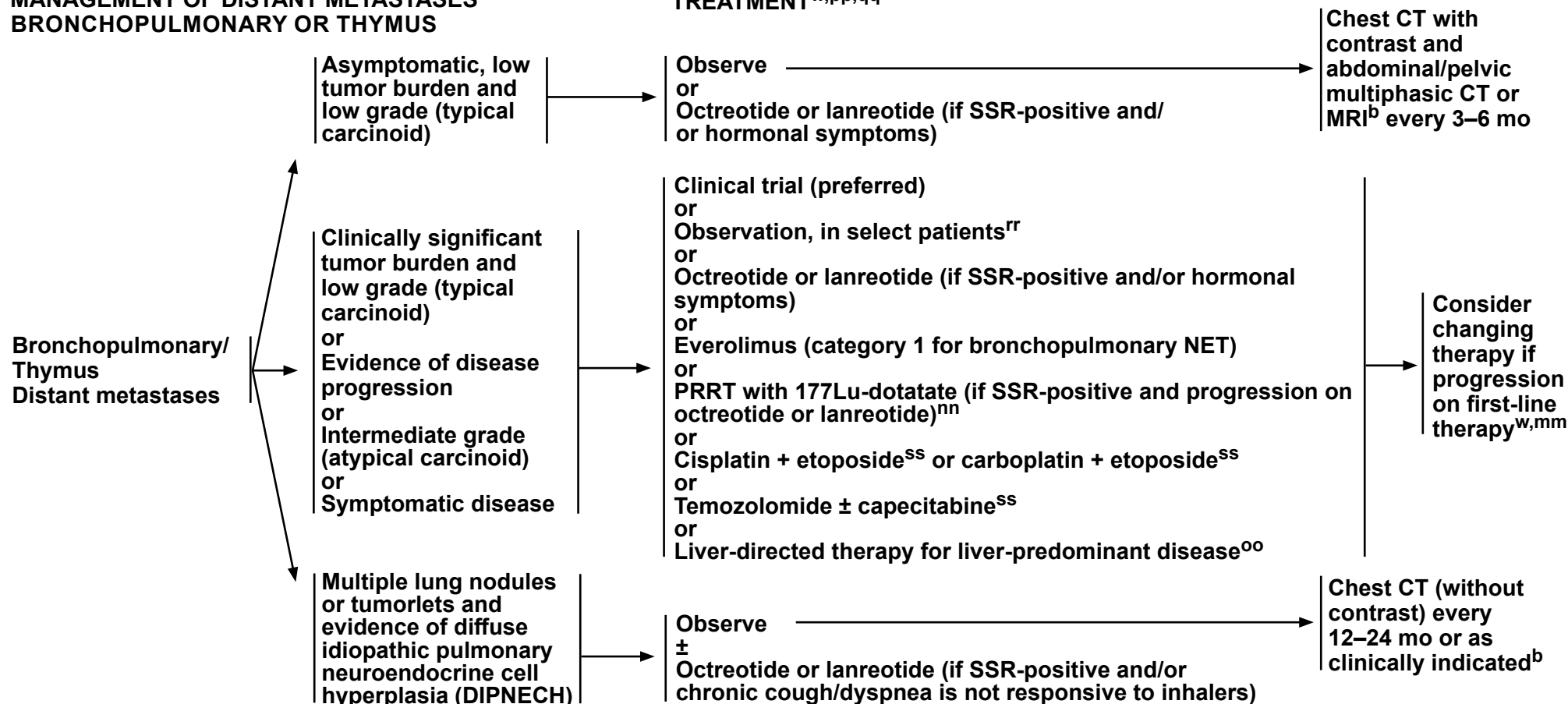
NCCN Guidelines Version 4.2021

Neuroendocrine Tumors of the Gastrointestinal Tract (Well-Differentiated Grade 1/2), Lung, and Thymus

[NCCN Guidelines Index](#)
[Table of Contents](#)
[Discussion](#)

MANAGEMENT OF DISTANT METASTASES^w BRONCHOPULMONARY OR THYMUS

TREATMENT^{w,pp,qq}



^b See Principles of Imaging (NE-B).

^w See Principles of Systemic Anti-Tumor Therapy (NE-F).

^{mm} If disease progression, treatment with octreotide or lanreotide should be discontinued for non-functional tumors and continued in patients with functional tumors; those regimens may be used in combination with any of the subsequent options. For details on the administration of octreotide or lanreotide with 177Lu-dotatate, see NE-G.

ⁿⁿ See Principles of Peptide Receptor Radionuclide Therapy (PRRT) with 177Lu-dotatate (NE-G).

^{oo} See Principles of Liver-Directed Therapy for Neuroendocrine Tumor Metastases (NE-H).

^{pp} For symptom control, consider addition of focal therapy (ie, endobronchial therapy debulking, ablation).

^{qq} Neuroendocrine tumors are highly heterogeneous and all elements need to be considered (eg, burden of disease, symptoms, histopathology, rate of growth) when determining the best course of treatment.

^{rr} Observation can be considered if asymptomatic or for tumors on the lower end of the spectrum.

^{ss} Can be considered for intermediate-grade/atypical tumors with Ki-67 proliferative index and mitotic index in the higher end of the defined spectrum.

Note: All recommendations are category 2A unless otherwise indicated.

Clinical Trials: NCCN believes that the best management of any patient with cancer is in a clinical trial. Participation in clinical trials is especially encouraged.



NCCN Guidelines Version 4.2021

Neuroendocrine Tumors of the Gastrointestinal Tract (Well-Differentiated Grade 1/2), Lung, and Thymus

CARCINOID SYNDROME^{tt}

EVALUATION

TREATMENT

SURVEILLANCE

ADDITIONAL THERAPY^{mm}

Recommended:

- Biochemical evaluation with 24-hour urine or plasma 5-HIAA^c
- Echocardiogram
- Imaging to assess disease progression (See [NET-10](#) or [NET-11](#))

Octreotide^{w,uu}
or
Lanreotide^w

Carcinoid
syndrome
well
controlled



Carcinoid
syndrome
poorly
controlled

If any persistent symptoms (ie, flushing, diarrhea), rule out non-carcinoid syndrome causes^{vv} and Consider additional therapy for symptom control:

- Hepatic arterial embolization or cytoreductive surgery for liver-predominant disease or
- Telotristat for diarrhea (250 mg, by mouth 3 times a day) or
- Other systemic therapy based on disease site^{w,ww}

- Echocardiogram every 2–3 y or as clinically indicated^b
- Abdominal/pelvic multiphasic CT or MRI every 12 wk–12 mo, and chest CT (± contrast) as clinically indicated

If disease progression, see Management of Locoregional, Advanced Disease and/or Distant Metastases:

- GI Tract ([NET-9](#))
- Bronchopulmonary/Thymus ([NET-10](#) and [NET-11](#))

^bSee [Principles of Imaging \(NE-B\)](#).

^cSee [Principles of Biochemical Testing \(NE-C\)](#).

^wSee [Principles of Systemic Anti-Tumor Therapy \(NE-F\)](#).

^{mm} If disease progression, treatment with octreotide or lanreotide should be discontinued for non-functional tumors and continued in patients with functional tumors; those regimens may be used in combination with any of the subsequent options. For details on the administration of octreotide or lanreotide with ¹⁷⁷Lu-dotatate, see [NE-G](#).

^{tt} See [Principles of Hormone Control \(NE-I\)](#).

^{uu} For symptom control, octreotide 150–250 mcg SC TID or octreotide LAR 20–30 mg IM or lanreotide 120 mg SC every 4 weeks. Dose and frequency may be further increased for symptom control as needed. Therapeutic levels of octreotide would not be expected to be reached for 10–14 d after LAR injection. Short-acting octreotide can be added to octreotide LAR for rapid relief of symptoms or for breakthrough symptoms. For details on the administration of short-acting and/or long-acting octreotide with ¹⁷⁷Lu-dotatate, see [NE-G](#).

^{vv} Evaluate for pancreatic exocrine deficiency and bile acid diarrhea.

^{ww} Safety and effectiveness of everolimus in the treatment of patients with carcinoid syndrome have not been established.

Note: All recommendations are category 2A unless otherwise indicated.

Clinical Trials: NCCN believes that the best management of any patient with cancer is in a clinical trial. Participation in clinical trials is especially encouraged.



NCCN Guidelines Version 4.2021

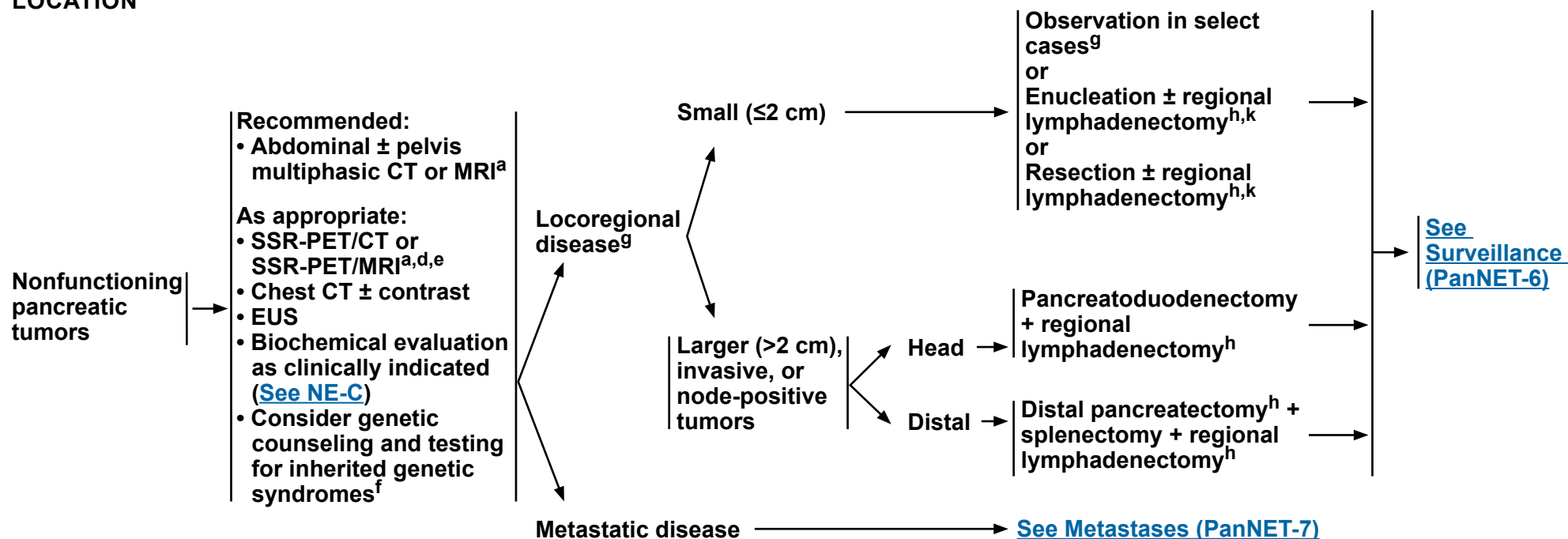
Neuroendocrine Tumors of the Pancreas

(Well-Differentiated Grade 1/2)

CLINICAL LOCATION

EVALUATION^{a,b,c}

MANAGEMENT OF PRIMARY NON-METASTATIC DISEASE^{h,i,j}



^a [See Principles of Imaging \(NE-B\).](#)

^b [See Principles of Pathology for Diagnosis and Reporting of Neuroendocrine Tumors \(NE-A\).](#)

^c [See Principles of Biochemical Testing \(NE-C\).](#)

^d SSR PET tracers include: 68Ga-DOTATATE, 64Cu-DOTATATE, 68Ga-DOTATOC.

^e PET/CT or PET/MRI of skull base to mid-thigh with IV contrast when possible. Data are limited on the optimal timing of scans following administration of SSAs.

^f [See Principles of Genetic Risk Assessment and Counseling \(NE-E\).](#)

^g Observation can be considered for small (≤ 2 cm), low-grade, incidentally discovered, non-functional tumors. Decision based on estimated surgical risk, site of tumor, and patient comorbidities. (Sadot E, et al. Ann Surg Oncol 2016;23:1361-70.) Follow surveillance recommendations on [PanNET-6](#).

^h [See Surgical Principles for Management of Neuroendocrine Tumors \(NE-D\).](#)

ⁱ Preoperative trivalent vaccine (ie, pneumococcus, haemophilus influenzae b, meningococcal group C), if considering surgery with possible splenectomy.

^j As appropriate, central pancreatectomy or spleen-preserving surgery should be considered.

^k Neuroendocrine tumors of the pancreas that are 1–2 cm have a small, but real risk of lymph node metastases. Therefore, lymph node resection should be considered.

Note: All recommendations are category 2A unless otherwise indicated.

Clinical Trials: NCCN believes that the best management of any patient with cancer is in a clinical trial. Participation in clinical trials is especially encouraged.



National
Comprehensive
Cancer
Network®

NCCN Guidelines Version 4.2021

Neuroendocrine Tumors of the Pancreas

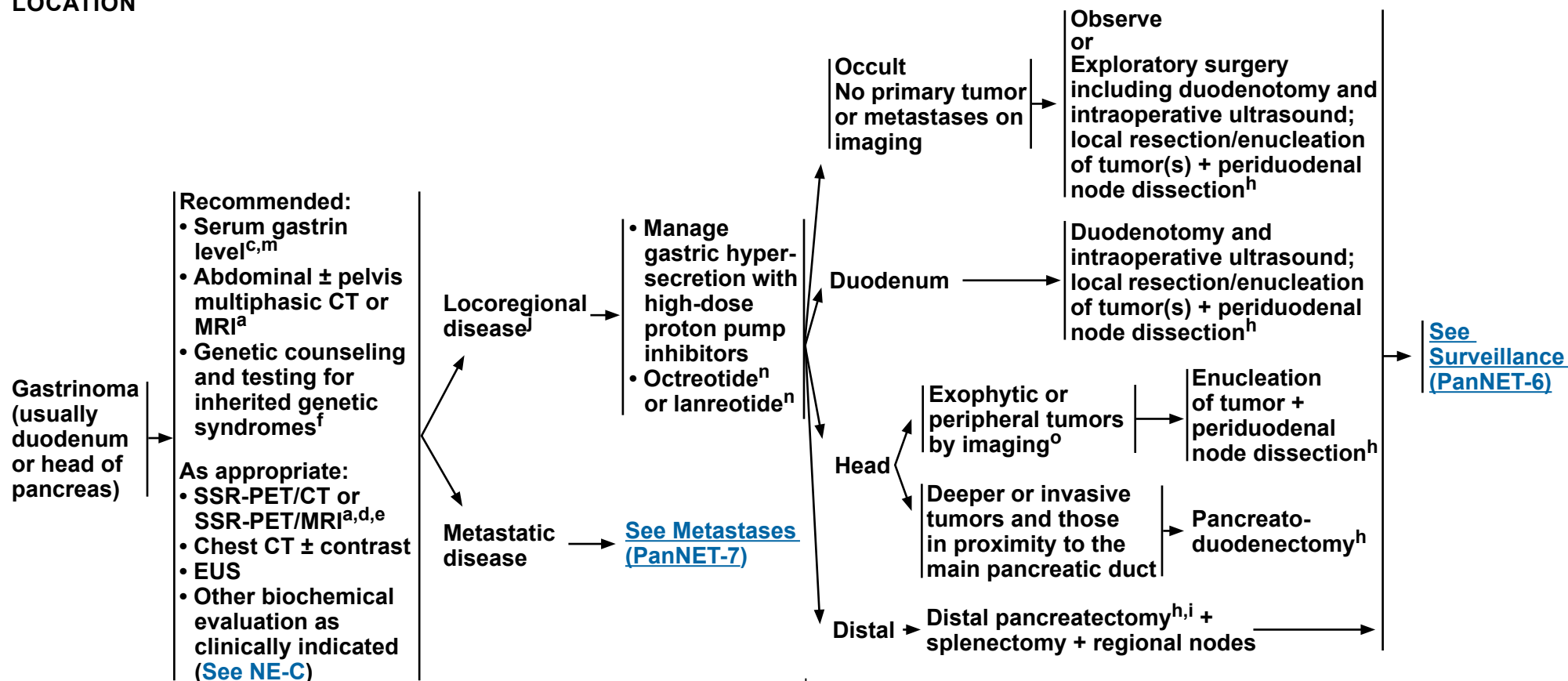
(Well-Differentiated Grade 1/2)

[NCCN Guidelines Index](#)
[Table of Contents](#)
[Discussion](#)

CLINICAL
LOCATION

EVALUATION^{a,b,c}

MANAGEMENT OF PRIMARY NON-METASTATIC DISEASE^{h,i,l}



^a [See Principles of Imaging \(NE-B\).](#)

^b [See Principles of Pathology for Diagnosis and Reporting of Neuroendocrine Tumors \(NE-A\).](#)

^c [See Principles of Biochemical Testing \(NE-C\).](#)

^d SSR PET tracers include: 68Ga-DOTATATE, 64Cu-DOTATATE, 68Ga-DOTATOC.

^e PET/CT or PET/MRI of skull base to mid-thigh with IV contrast when possible. Data are limited on the optimal timing of scans following administration of SSAs.

^f [See Principles of Genetic Risk Assessment and Counseling \(NE-E\).](#)

^h [See Surgical Principles for Management of Neuroendocrine Tumors \(NE-D\).](#)

ⁱ Preoperative trivalent vaccine (ie, pneumococcus, haemophilus influenzae b, meningococcal group C), if considering surgery with possible splenectomy.

^l [See Principles of Hormone Control \(NE-I\).](#)

^m Serum gastrin can be falsely elevated with proton pump inhibitor (PPI) use. To confirm diagnosis, it should ideally be checked when fasting and off PPI for >1 week. However, PPI should be continued in patients with overt clinical symptoms of gastrinoma and/or risks of complications.

ⁿ [See Principles of Systemic Anti-Tumor Therapy \(NE-F\).](#)

^o Not adjacent to the main pancreatic duct.

Note: All recommendations are category 2A unless otherwise indicated.

Clinical Trials: NCCN believes that the best management of any patient with cancer is in a clinical trial. Participation in clinical trials is especially encouraged.



National
Comprehensive
Cancer
Network®

NCCN Guidelines Version 4.2021

Neuroendocrine Tumors of the Pancreas

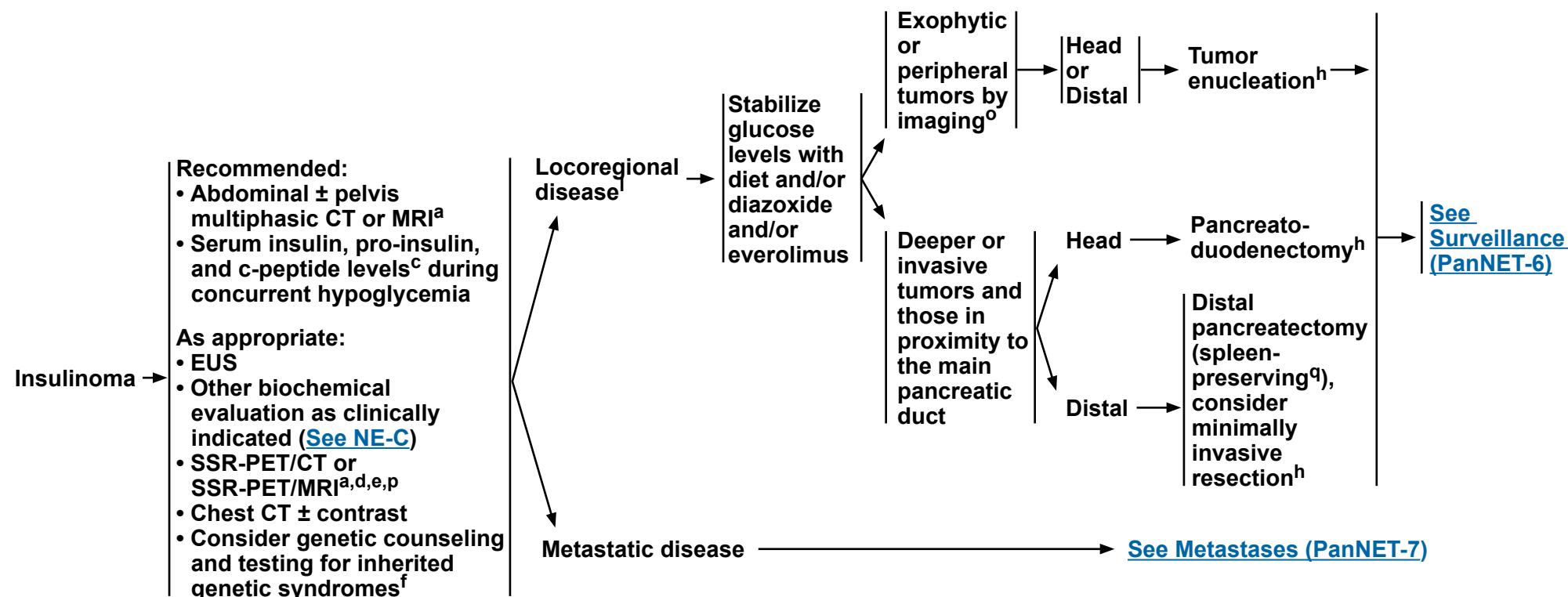
(Well-Differentiated Grade 1/2)

[NCCN Guidelines Index](#)
[Table of Contents](#)
[Discussion](#)

CLINICAL LOCATION

EVALUATION^{a,b,c}

MANAGEMENT OF PRIMARY NON-METASTATIC DISEASE^{h,i,l}



^a [See Principles of Imaging \(NE-B\).](#)

^b [See Principles of Pathology for Diagnosis and Reporting of Neuroendocrine Tumors \(NE-A\).](#)

^c [See Principles of Biochemical Testing \(NE-C\).](#)

^d SSR PET tracers include: 68Ga-DOTATATE, 64Cu-DOTATATE, 68Ga-DOTATOC.

^e PET/CT or PET/MRI of skull base to mid-thigh with IV contrast when possible. Data are limited on the optimal timing of scans following administration of SSAs.

^f [See Principles of Genetic Risk Assessment and Counseling \(NE-E\).](#)

^h [See Surgical Principles for Management of Neuroendocrine Tumors \(NE-D\).](#)

ⁱ Preoperative trivalent vaccine (ie, pneumococcus, haemophilus influenzae b, meningococcal group C), if considering surgery with possible splenectomy.

^l [See Principles of Hormone Control \(NE-I\).](#)

^o Not adjacent to the main pancreatic duct.

^p SSR-based imaging only if treatment with octreotide or lanreotide is planned. Octreotide or lanreotide should only be given if tumor demonstrates SSRs. In the absence of SSRs, octreotide or lanreotide can profoundly worsen hypoglycemia. ([See Discussion](#) for details).

^q Splenectomy should be performed for larger tumors involving splenic vessels.

Note: All recommendations are category 2A unless otherwise indicated.

Clinical Trials: NCCN believes that the best management of any patient with cancer is in a clinical trial. Participation in clinical trials is especially encouraged.



National
Comprehensive
Cancer
Network®

NCCN Guidelines Version 4.2021

Neuroendocrine Tumors of the Pancreas

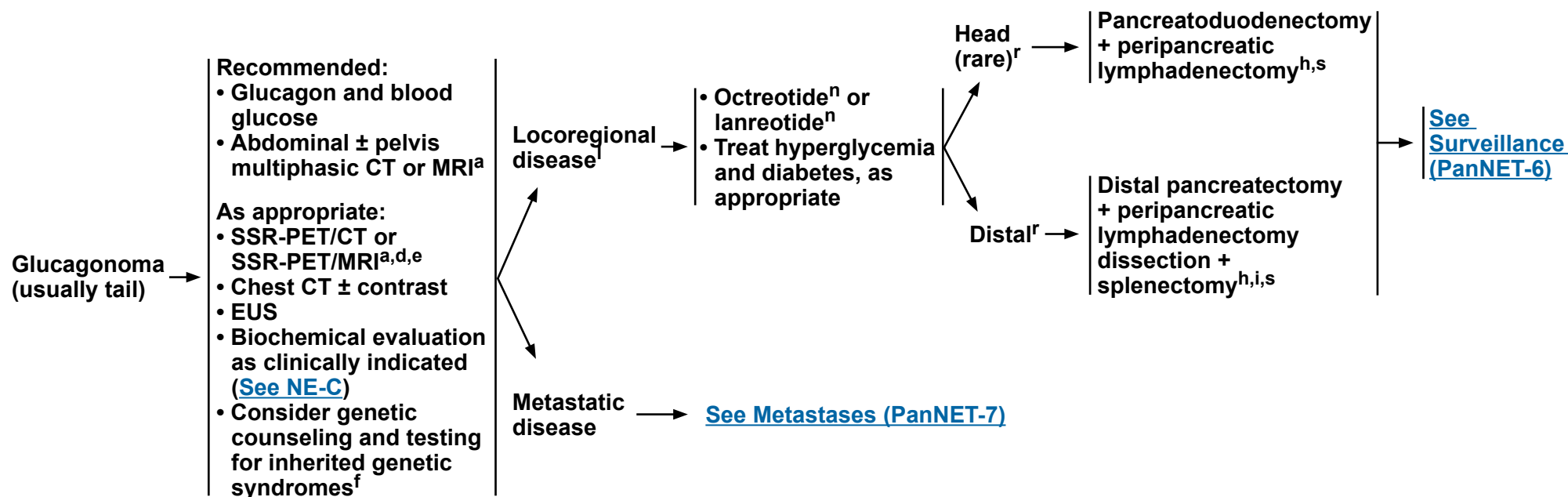
(Well-Differentiated Grade 1/2)

[NCCN Guidelines Index](#)
[Table of Contents](#)
[Discussion](#)

CLINICAL LOCATION

EVALUATION^{a,b,c}

MANAGEMENT OF PRIMARY NON-METASTATIC DISEASE^{h,i,l}



^a [See Principles of Imaging \(NE-B\).](#)

^b [See Principles of Pathology for Diagnosis and Reporting of Neuroendocrine Tumors \(NE-A\).](#)

^c [See Principles of Biochemical Testing \(NE-C\).](#)

^d SSR PET tracers include: 68Ga-DOTATATE, 64Cu-DOTATATE, 68Ga-DOTATOC.

^e PET/CT or PET/MRI of skull base to mid-thigh with IV contrast when possible. Data are limited on the optimal timing of scans following administration of SSAs.

^f [See Principles of Genetic Risk Assessment and Counseling \(NE-E\).](#)

^h [See Surgical Principles for Management of Neuroendocrine Tumors \(NE-D\).](#)

ⁱ Preoperative trivalent vaccine (ie, pneumococcus, haemophilus influenzae b, meningococcal group C), if considering surgery with possible splenectomy.

^l [See Principles of Hormone Control \(NE-I\).](#)

ⁿ [See Principles of Systemic Anti-Tumor Therapy \(NE-F\).](#)

^r Small (<2 cm), peripheral glucagonomas are rare; enucleation/local excision + peripancreatic lymph dissection may be considered.

^s Hypercoagulable state has been described. Perioperative anticoagulation can be considered.

Note: All recommendations are category 2A unless otherwise indicated.

Clinical Trials: NCCN believes that the best management of any patient with cancer is in a clinical trial. Participation in clinical trials is especially encouraged.



National
Comprehensive
Cancer
Network®

NCCN Guidelines Version 4.2021

Neuroendocrine Tumors of the Pancreas

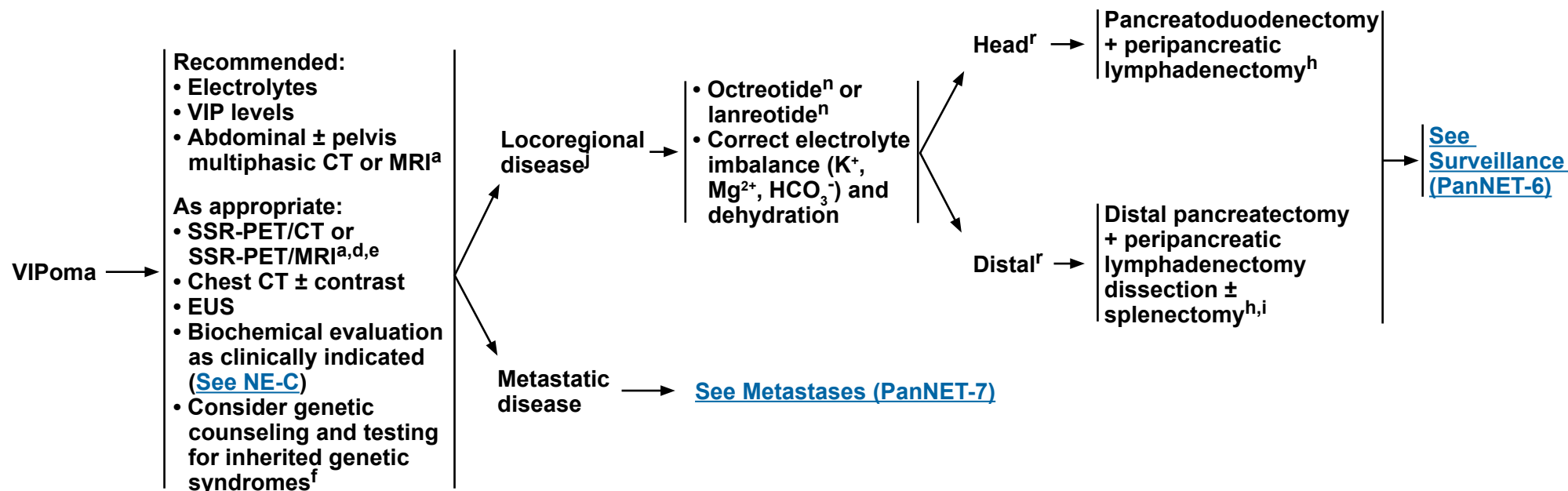
(Well-Differentiated Grade 1/2)

[NCCN Guidelines Index](#)
[Table of Contents](#)
[Discussion](#)

CLINICAL LOCATION

EVALUATION^{a,b,c}

MANAGEMENT OF PRIMARY NON-METASTATIC DISEASE^{h,i,l}



^a [See Principles of Imaging \(NE-B\).](#)

^b [See Principles of Pathology for Diagnosis and Reporting of Neuroendocrine Tumors \(NE-A\).](#)

^c [See Principles of Biochemical Testing \(NE-C\).](#)

^d SSR PET tracers include: 68Ga-DOTATATE, 64Cu-DOTATATE, 68Ga-DOTATOC.

^e PET/CT or PET/MRI of skull base to mid-thigh with IV contrast when possible. Data are limited on the optimal timing of scans following administration of SSAs.

^f [See Principles of Genetic Risk Assessment and Counseling \(NE-E\).](#)

^h [See Surgical Principles for Management of Neuroendocrine Tumors \(NE-D\).](#)

ⁱ Preoperative trivalent vaccine (ie, pneumococcus, haemophilus influenzae b, meningococcal group C), if considering surgery with possible splenectomy.

^l [See Principles of Hormone Control \(NE-I\).](#)

ⁿ [See Principles of Systemic Anti-Tumor Therapy \(NE-F\).](#)

^r Small (<2 cm), peripheral VIPomas are rare; enucleation/local excision + peripancreatic lymph dissection may be considered.

Note: All recommendations are category 2A unless otherwise indicated.

Clinical Trials: NCCN believes that the best management of any patient with cancer is in a clinical trial. Participation in clinical trials is especially encouraged.



National
Comprehensive
Cancer
Network®

NCCN Guidelines Version 4.2021

Neuroendocrine Tumors of the Pancreas

(Well-Differentiated Grade 1/2)

[NCCN Guidelines Index](#)
[Table of Contents](#)
[Discussion](#)

SURVEILLANCE^{t,u,v,w}

RECURRENT DISEASE

MANAGEMENT OF RECURRENT DISEASE^h

12 wk–12 mo post-resection:

- H&P
- Consider biochemical markers as clinically indicated^c
- Abdominal multiphasic^a CT or MRI and chest CT (± contrast) as clinically indicated

>1 y post-resection to a maximum of 10 y:

- Every 6–12 mo
 - H&P
 - Consider biochemical markers as clinically indicated^c
 - Abdominal multiphasic^a CT or MRI
 - Chest CT (± contrast) as clinically indicated

>10 y:

- Consider surveillance as clinically indicated^x

Disease recurrence^y

[See Management of Locoregional Advanced Disease and/or Distant Metastases \(PanNET-7\)](#)

^a [See Principles of Imaging \(NE-B\).](#)

^c [See Principles of Biochemical Testing \(NE-C\).](#)

^h [See Surgical Principles for Management of Neuroendocrine Tumors \(NE-D\).](#)

^t Earlier, if symptoms.

^u SSR-based imaging and FDG-PET/CT scan are not recommended for routine surveillance.

^v Surveillance recommendations also apply to cases where observation has been chosen.

^w [See NCCN Guidelines for Survivorship.](#)

^x Singh S, et al. JAMA Oncol 2018;4:1597-1604.

^y In select cases, resection may be considered.

Note: All recommendations are category 2A unless otherwise indicated.

Clinical Trials: NCCN believes that the best management of any patient with cancer is in a clinical trial. Participation in clinical trials is especially encouraged.



National
Comprehensive
Cancer
Network®

NCCN Guidelines Version 4.2021

Neuroendocrine Tumors of the Pancreas

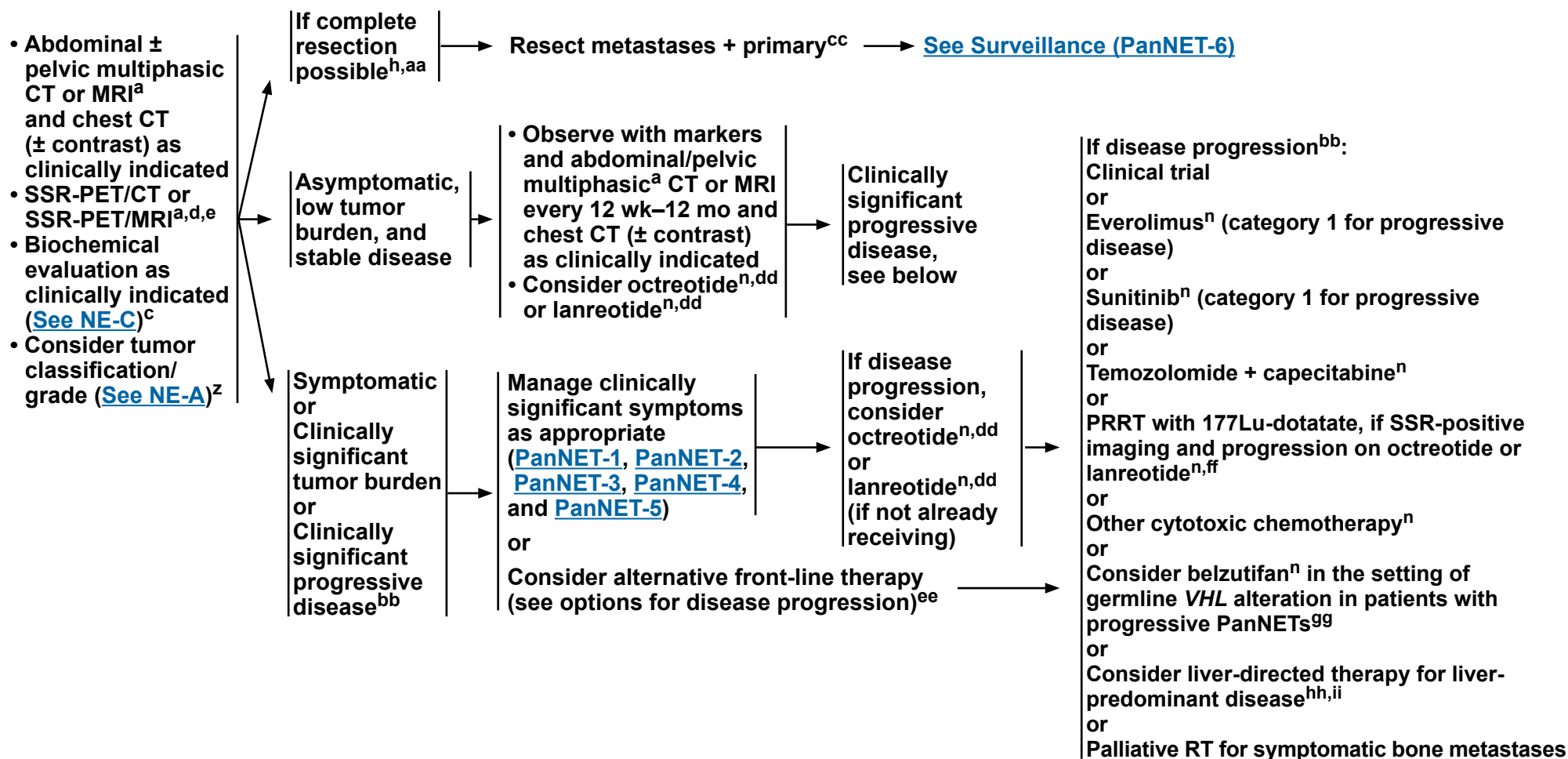
(Well-Differentiated Grade 1/2)

[NCCN Guidelines Index](#)
[Table of Contents](#)
[Discussion](#)

MANAGEMENT OF LOCOREGIONAL ADVANCED DISEASE AND/OR DISTANT METASTASES^h

EVALUATION

TREATMENT



Note: All recommendations are category 2A unless otherwise indicated.

Clinical Trials: NCCN believes that the best management of any patient with cancer is in a clinical trial. Participation in clinical trials is especially encouraged.

[Footnotes](#)



NCCN Guidelines Version 4.2021

Neuroendocrine Tumors of the Pancreas

(Well-Differentiated Grade 1/2)

FOOTNOTES

^a [See Principles of Imaging \(NE-B\).](#)

^c [See Principles of Biochemical Testing \(NE-C\).](#)

^d SSR PET tracers include: 68Ga-DOTATATE, 64Cu-DOTATATE, 68Ga-DOTATOC.

^e PET/CT or PET/MRI of skull base to mid-thigh with IV contrast when possible. Data are limited on the optimal timing of scans following administration of SSAs.

^h [See Surgical Principles for Management of Neuroendocrine Tumors \(NE-D\).](#)

ⁿ [See Principles of Systemic Anti-Tumor Therapy \(NE-F\).](#)

^z There are limited data on management of well-differentiated G3 tumors. Treatment options will vary based on clinical judgment, but may include those options for poorly differentiated G3 tumors, or well-differentiated G1-2 tumors. [See Discussion.](#)

^{aa} Noncurative debulking surgery might be considered in select cases.

^{bb} If disease progression, treatment with octreotide or lanreotide should be discontinued for non-functional tumors and continued in patients with functional tumors; those regimens may be used in combination with any of the subsequent options. For details on the administration of octreotide or lanreotide with 177Lu-dotatate, [see NE-G.](#)

^{cc} Staged or synchronous resection when possible. When performing staged pancreatoduodenectomy and liver resection, consider hepatectomy prior to pancreatic resection in order to reduce risk of perihepatic sepsis. De Jong MC, et al. Ann Surg 2010;252:142-148.

^{dd} For patients with insulinoma, octreotide or lanreotide should be used only if SSR-based imaging is positive. If used, they should be used with caution in patients with insulinoma as they may transiently worsen hypoglycemia ([See Discussion](#) for details).

^{ee} In select cases it may be appropriate to proceed to front-line systemic therapy or liver-directed therapy prior to or concurrently with octreotide or lanreotide.

^{ff} [See Principles of PRRT with 177Lu-dotatate \(NE-G\).](#)

^{gg} The study excluded patients with prior systemic anticancer therapy, including anti-vascular endothelial growth factor therapy, patients needing immediate surgical intervention for tumor treatment, or patients with evidence of metastatic disease on screening imaging. Jonasch E, Donskov F, Iliopoulos O, et al. Belzutifan for renal cell carcinoma in von Hippel-Lindau disease. N Engl J Med 2021;385:2036-2046.

^{hh} After any prior biliary instrumentation, there are increased risks of infectious complications associated with liver-directed therapies.

ⁱⁱ [See Principles of Liver-Directed Therapy for Neuroendocrine Tumor Metastases \(NE-H\).](#)

Note: All recommendations are category 2A unless otherwise indicated.

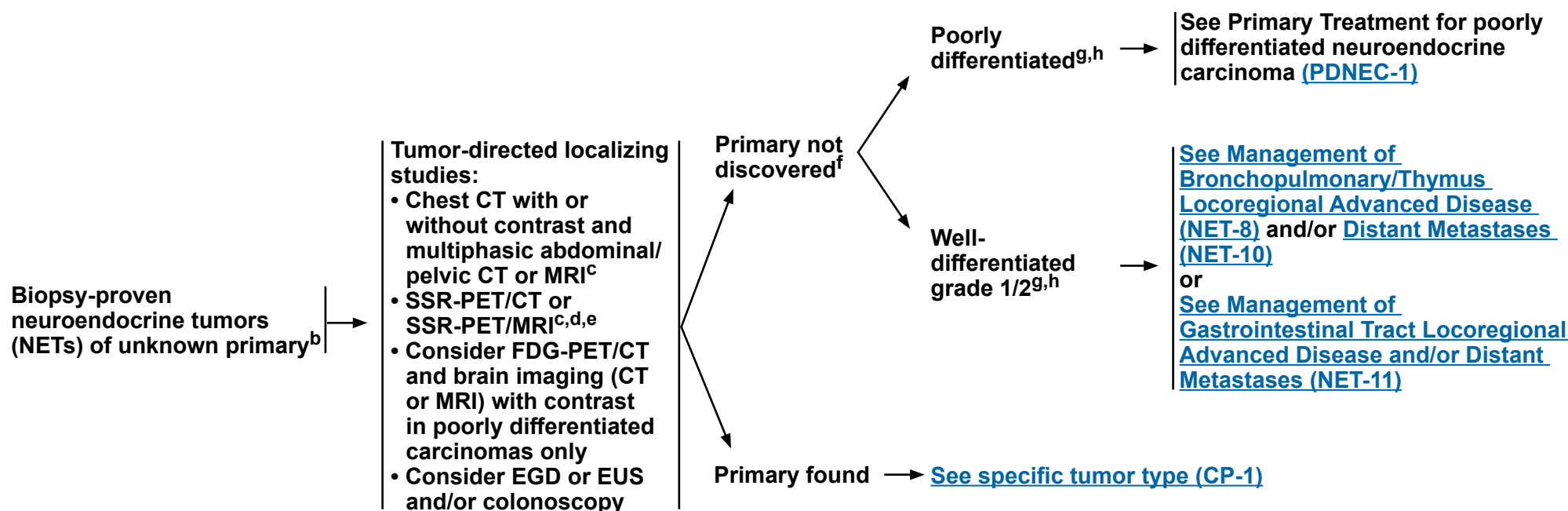
Clinical Trials: NCCN believes that the best management of any patient with cancer is in a clinical trial. Participation in clinical trials is especially encouraged.



NCCN Guidelines Version 4.2021

Neuroendocrine Tumors of Unknown Primary

INITIAL WORKUP^a



^a See [Principles of Pathology for Diagnosis and Reporting of Neuroendocrine Tumors \(NE-A\)](#).

^b Treat presumptively as gastroenteropancreatic (GEP) NETs if it is unknown primary.

^c See [Principles of Imaging \(NE-B\)](#).

^d PET/CT or PET/MRI of skull base to mid-thigh with IV contrast when possible. Data are limited on the optimal timing of scans following administration of SSAs.

^e SSR PET tracers include: 68Ga-DOTATATE, 64Cu-DOTATATE, 68Ga-DOTATOC.

^f Consider small bowel primary tumor based on symptoms and associated radiologic findings.

^g Indicate well- or poorly differentiated. Klimstra DS, et al. *Pancreas* 2010;39:707-712.

^h See [Principles of Biochemical Testing \(NE-C\)](#).

Note: All recommendations are category 2A unless otherwise indicated.

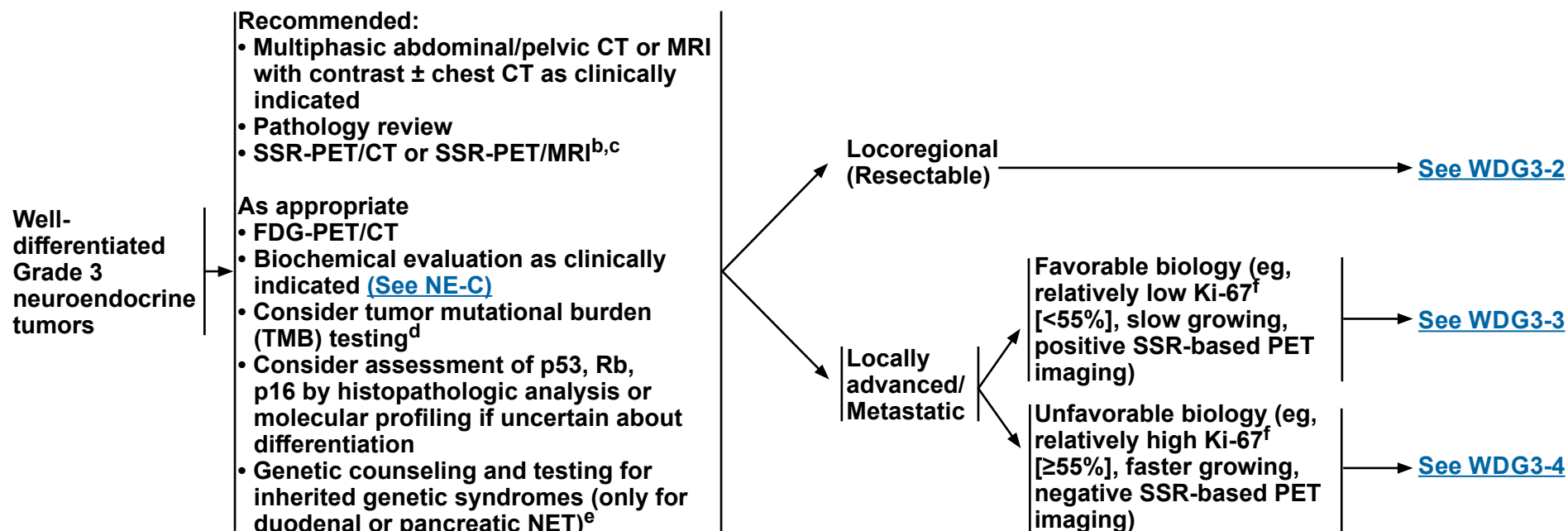
Clinical Trials: NCCN believes that the best management of any patient with cancer is in a clinical trial. Participation in clinical trials is especially encouraged.



NCCN Guidelines Version 4.2021

Well-Differentiated, Grade 3 Neuroendocrine Tumors

TUMOR TYPE EVALUATION^a

^a [See Principles of Imaging \(NE-B\).](#)^b PET/CT or PET/MRI of skull base to mid-thigh with IV contrast when possible. Data are limited on the optimal timing of scans following administration of SSAs.^c SSR PET tracers include: 68Ga-DOTATATE, 64Cu-DOTATATE, 68Ga-DOTATOC.^d FDA-approved test recommended for determination of TMB.^e [See Principles of Genetic Risk Assessment and Counseling \(NE-E\).](#)^f There are limitations in terms of the data for what the appropriate cutoff should be, as well as variability/heterogeneity of Ki-67 in a given tumor and over time in serial biopsies. The clinical course and histopathologic workup combined should dictate therapy, not solely Ki-67.**Note:** All recommendations are category 2A unless otherwise indicated.**Clinical Trials:** NCCN believes that the best management of any patient with cancer is in a clinical trial. Participation in clinical trials is especially encouraged.



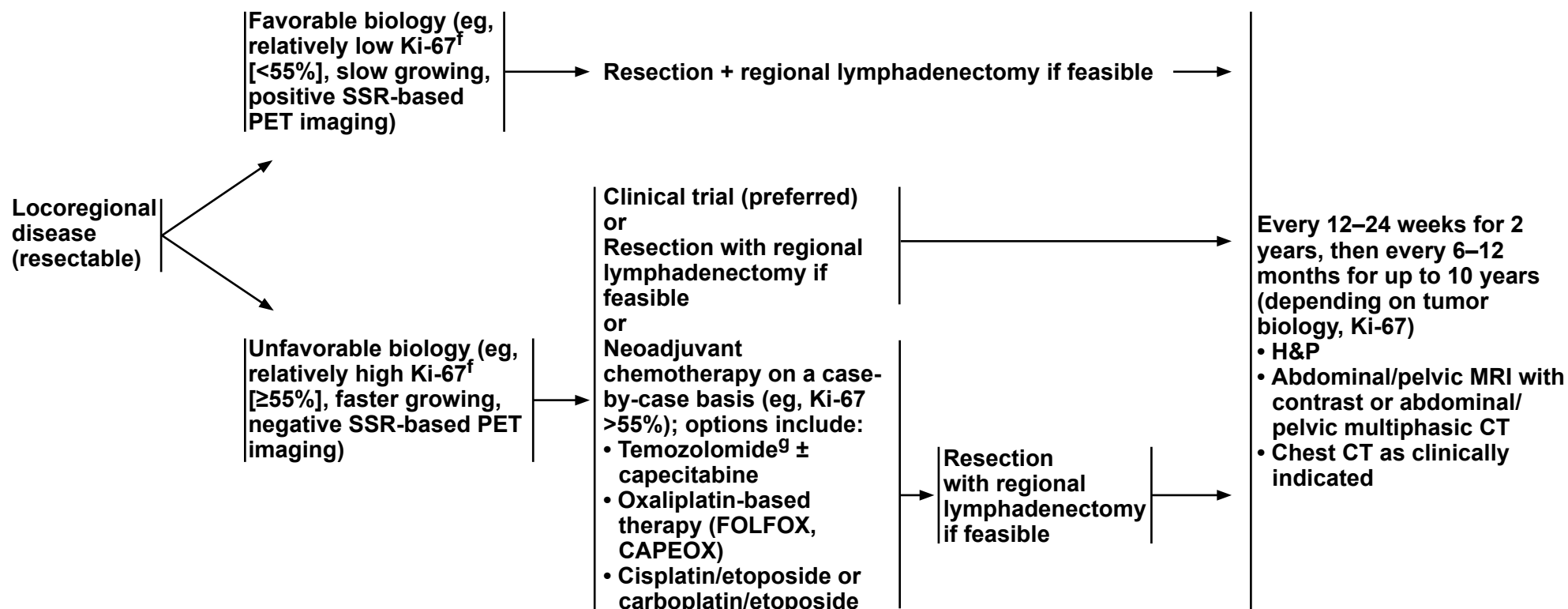
NCCN Guidelines Version 4.2021

Well-Differentiated, Grade 3 Neuroendocrine Tumors

MANAGEMENT OF LOCOREGIONAL DISEASE

TREATMENT

SURVEILLANCE^a


^a See Principles of Imaging (NE-B).

^f There are limitations in terms of the data for what the appropriate cutoff should be, as well as variability/heterogeneity of Ki-67 in a given tumor and over time in serial biopsies. The clinical course and histopathologic workup combined should dictate therapy, not solely Ki-67.

^g May have more activity in tumors arising in pancreas.

Note: All recommendations are category 2A unless otherwise indicated.

Clinical Trials: NCCN believes that the best management of any patient with cancer is in a clinical trial. Participation in clinical trials is especially encouraged.



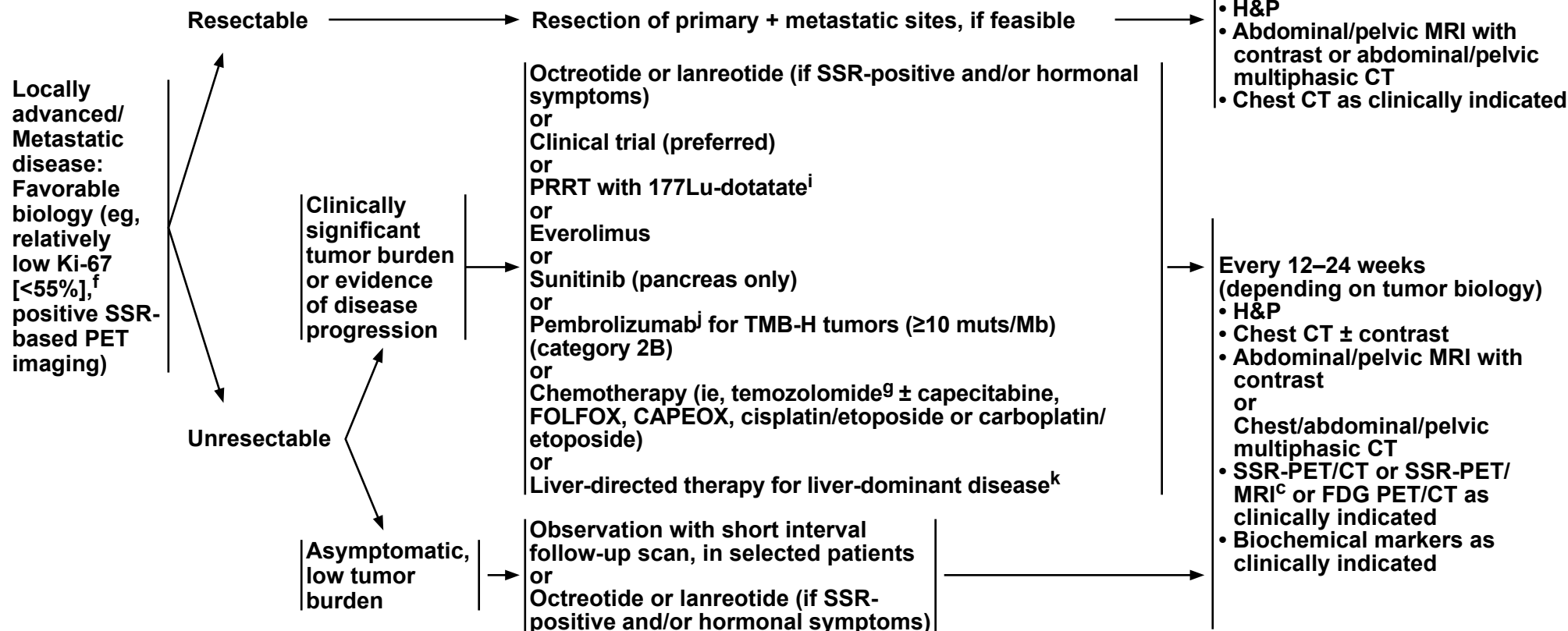
NCCN Guidelines Version 4.2021

Well-Differentiated, Grade 3 Neuroendocrine Tumors

MANAGEMENT OF LOCALLY ADVANCED/METASTATIC DISEASE: FAVORABLE BIOLOGY

TREATMENT^h

SURVEILLANCE^a



^a See [Principles of Imaging \(NE-B\)](#).

^c SSR PET tracers include: ⁶⁸Ga-DOTATATE, ⁶⁴Cu-DOTATATE, ⁶⁸Ga-DOTATOC.

^f There are limitations in terms of the data for what the appropriate cutoff should be, as well as variability/heterogeneity of Ki-67 in a given tumor and over time in serial biopsies. The clinical course and histopathologic workup combined should dictate therapy, not solely Ki-67.

^g May have more activity in tumors arising in pancreas.

^h Clinical trials preferred due to a lack of data from prospective clinical trials to guide therapy.

ⁱ Consider trial of SSA before PRRT. Preliminary data suggest reduced efficacy if high Ki-67 and/or FDG-PET avid. See [Principles of PRRT with ¹⁷⁷Lu-DOTATATE \(NE-G\)](#).

^j Pembrolizumab is an option for patients with advanced tumor mutational burden-high (TMB-H) tumors (as determined by an FDA-approved test) that have progressed following prior treatment and have no satisfactory alternative treatment options.

^k See [Principles of Liver-Directed Therapy for Neuroendocrine Tumor Metastases \(NE-H\)](#).

Note: All recommendations are category 2A unless otherwise indicated.

Clinical Trials: NCCN believes that the best management of any patient with cancer is in a clinical trial. Participation in clinical trials is especially encouraged.



NCCN Guidelines Version 4.2021

Well-Differentiated, Grade 3 Neuroendocrine Tumors

MANAGEMENT OF LOCALLY ADVANCED/METASTATIC DISEASE: UNFAVORABLE BIOLOGY

TREATMENT

SURVEILLANCE^a

Locally advanced/Metastatic disease
Unfavorable biology (relatively high
Ki-67 [≥55%],^f rapid growth rate, FDG-
avid tumors, negative SSR-based
PET imaging)

Clinical trial (preferred)
or
Systemic therapy, options:
• Cisplatin/etoposide or carboplatin/etoposide
• Temozolomide ± capecitabine^g
• Oxaliplatin-based therapy (ie, FOLFOX or CAPEOX)
• Pembrolizumab^j for TMB-H tumors (≥10 muts/Mb)
• Irinotecan-based therapy (eg, FOLFIRI, cisplatin +
irinotecan, or FOLFIRINOX)
• Nivolumab + ipilimumab (category 2B)
or
Consider addition of liver-directed therapy
(embolization, selective internal RT, ablation, SBRT)^l
or
Palliative RT for symptomatic bone metastases

Every 8–12 weeks (depending
on tumor biology)
• H&P
• Chest CT ± contrast
• Abdominal/pelvic MRI with
contrast or chest/abdominal/
pelvic multiphasic CT
• FDG PET/CT as clinically
indicated
• Biochemical markers as
clinically indicated^m

^a See [Principles of Imaging \(NE-B\)](#).

^f There are limitations in terms of the data for what the appropriate cutoff should be, as well as variability/heterogeneity of Ki-67 in a given tumor and over time in serial biopsies. The clinical course and histopathologic workup combined should dictate therapy, not solely Ki-67.

^g May have more activity in tumors arising in pancreas.

^j Pembrolizumab is an option for patients with advanced tumor mutational burden-high (TMB-H) tumors (as determined by an FDA-approved test) that have progressed following prior treatment and have no satisfactory alternative treatment options.

^l Consider liver-directed therapy in selected cases with residual liver-predominant disease after systemic therapy. See [Principles of Liver-Directed Therapy for Neuroendocrine Tumor Metastases \(NE-H\)](#).

^m See [Principle of Biochemical Testing \(NE-C\)](#).

Note: All recommendations are category 2A unless otherwise indicated.

Clinical Trials: NCCN believes that the best management of any patient with cancer is in a clinical trial. Participation in clinical trials is especially encouraged.



National
Comprehensive
Cancer
Network®

NCCN Guidelines Version 4.2021

Poorly Differentiated Neuroendocrine Carcinoma/ Large or Small Cell

[NCCN Guidelines Index](#)
[Table of Contents](#)
[Discussion](#)

TUMOR TYPE	EVALUATION ^{a,c}	TREATMENT ^{d,e,f}	SURVEILLANCE ^{h,i}
Extrapulmonary: • Poorly differentiated neuroendocrine carcinoma ^{a,b} • Large or small cell carcinoma (other than lung) • Unknown primary (poorly differentiated)	Recommended: • Chest/abdominal/pelvic CT or • Chest CT and abdominal/pelvic MRI ^c As appropriate: • Brain MRI or CT with contrast • FDG-PET/CT • Biochemical evaluation as clinically indicated (See NE-C) • Consider MSI, MMR, and TMB testing ^d	Resectable → <div> Therapy options depend on sites of disease. Options may include: • Resection + adjuvant chemotherapy^g ± RT • Neoadjuvant chemotherapy^g ± RT + resection • Chemotherapy alone^g • RT alone • Definitive chemoradiation with cisplatin + etoposide or carboplatin + etoposide </div>	Every 12 weeks for 1 y, then every 6 mo: • H&P • Appropriate imaging studies: ▶ Chest CT with or without contrast and abdominal/pelvic MRI with contrast or ▶ Chest/abdominal/pelvic multiphasic CT
		Locoregional, unresectable → <div> Concurrent or sequential RT + chemotherapy^g or Chemotherapy^g </div>	Every 6–16 weeks: • H&P • Appropriate imaging studies: ▶ Chest CT with or without contrast and abdominal/pelvic MRI with contrast or ▶ Chest/abdominal/pelvic multiphasic CT
		Metastatic → Chemotherapy ^g → <div> If progression, consider nivolumab + ipilimumab (category 2B) </div>	

^a This page is for PDNEC and not high-grade NET. Not all high-grade (Ki-67 >20%) neuroendocrine neoplasms are poorly differentiated. [See WDG3-1](#).

^b [See Principles of Pathology for Diagnosis and Reporting of Neuroendocrine Tumors \(NE-A\)](#).

^c Somatostatin scintigraphy with SPECT/CT is not part of the routine evaluation of poorly differentiated neuroendocrine carcinomas, but may be considered for morphologically well-differentiated tumors with higher proliferation index, as appropriate. [See Principles of Imaging \(NE-B\)](#).

^d Pembrolizumab can be considered for patients with mismatch repair-deficient (dMMR), microsatellite instability-high (MSI-H), or advanced tumor mutational burden-high (TMB-H) tumors (as determined by an FDA-approved test) that have progressed following prior treatment and have no satisfactory alternative treatment options.

^e Combination of immune checkpoint inhibitors + chemotherapy is investigational for all patients with extrapulmonary poorly differentiated neuroendocrine carcinomas.

^f [See Surgical Principles for Management of Neuroendocrine Tumors \(NE-D\)](#).

^g [See Principles of Systemic Anti-Tumor Therapy \(NE-F\)](#).

^h Earlier, if symptoms.

ⁱ [See NCCN Guidelines for Survivorship](#).

Note: All recommendations are category 2A unless otherwise indicated.

Clinical Trials: NCCN believes that the best management of any patient with cancer is in a clinical trial. Participation in clinical trials is especially encouraged.



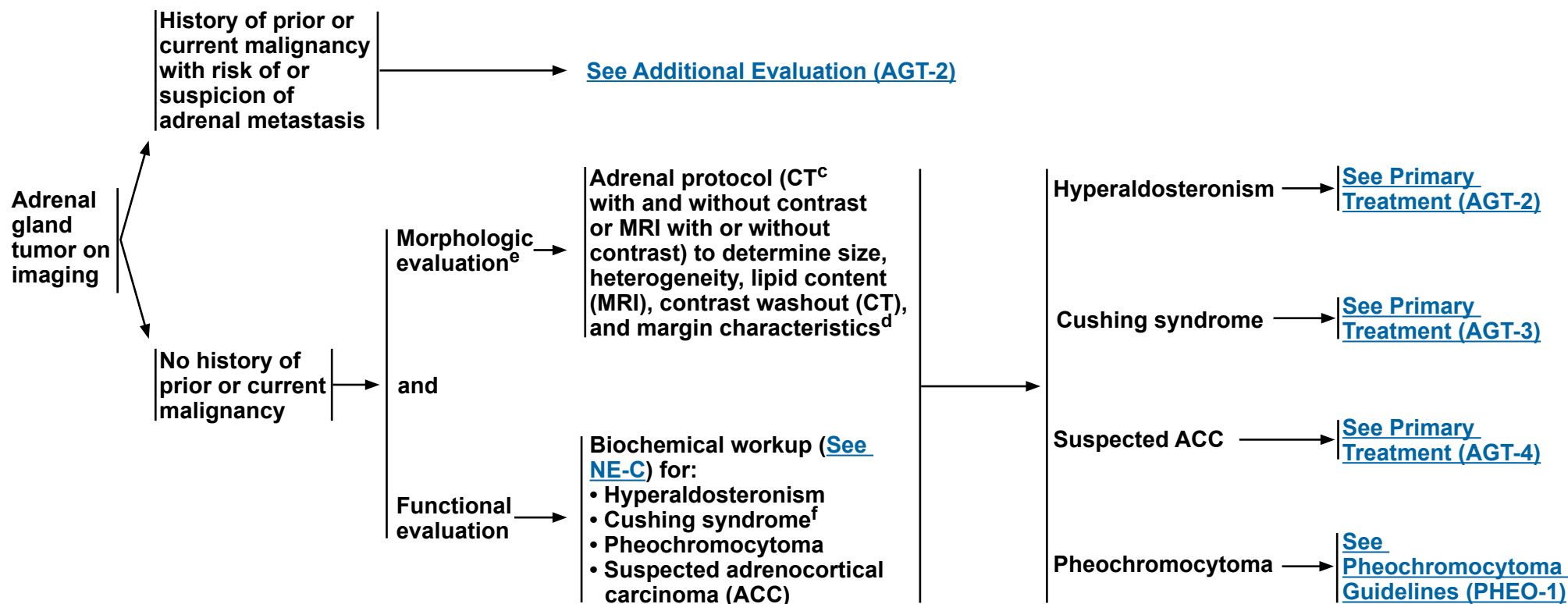
NCCN Guidelines Version 4.2021

Adrenal Gland Tumors

CLINICAL PRESENTATION

EVALUATION^{a,b}

CLINICAL DIAGNOSIS



^a [See Principles of Pathology for Diagnosis and Reporting of Neuroendocrine Tumors \(NE-A\).](#)

^b [See Principles of Biochemical Testing \(NE-C\).](#)

^c If unenhanced is <+ 10 HU, then the tumor is probably benign. If unenhanced is >+ 10 HU, then use enhanced and washout. If >60% absolute washout in 15 minutes, the tumor is likely to be benign; if <60%, the tumor is possibly malignant. (Caoili E, et al. Radiology 2002;222:629-633.)

^d [See Principles of Imaging \(NE-B\).](#)

^e For benign-appearing lesions, refer to the following guidelines for the management of adrenal incidentalomas: Zeiger MA, Thompson GB, Duh QY, et al. The American Association of Clinical Endocrinologists and American Association of Endocrine Surgeons medical guidelines for the management of adrenal incidentalomas. Endocrine practice: official journal of the American College of Endocrinology and the American Association of Clinical Endocrinologists 2009;15 Suppl 1:1-20; Fassnacht M, Arlt W, Bancos I, et al. Management of adrenal incidentalomas: European Society of Endocrinology Clinical Practice Guideline in collaboration with the European Network for the Study of Adrenal Tumors. Eur J Endocrinol 2016;175:G1-G34.

^f For benign-appearing lesions, refer to the Endocrine Society's Clinical Practice Guidelines for the Treatment of Cushing's Syndrome (Nieman LK, et al. J Clin Endocrinol Metab 2015;100:2807-2831).

Note: All recommendations are category 2A unless otherwise indicated.

Clinical Trials: NCCN believes that the best management of any patient with cancer is in a clinical trial. Participation in clinical trials is especially encouraged.




NCCN Guidelines Version 4.2021

Adrenal Gland Tumors

CLINICAL DIAGNOSIS

ADDITIONAL EVALUATION

PRIMARY TREATMENT



^b See Principles of Biochemical Testing (NE-C).

^g Suspect malignancies with irregular/inhomogeneous morphology, lipid-poor, do not wash-out, tumor >4 cm, or secretion of more than one hormone.

^h False negatives are possible; may consider proceeding directly to surgery in selected cases.

ⁱ Adrenal vein sampling can be considered for distinguishing single unilateral adenomas from bilateral hyperplasia. CT imaging is not always reliable. Some NCCN Member Institutions recommend sampling in all cases of primary aldosteronism. However, it may be reasonable to exclude adrenal vein sampling in patients <40 y. Cortisol measurement in the catheterization samples is used to confirm proper catheter placement.

Note: All recommendations are category 2A unless otherwise indicated.

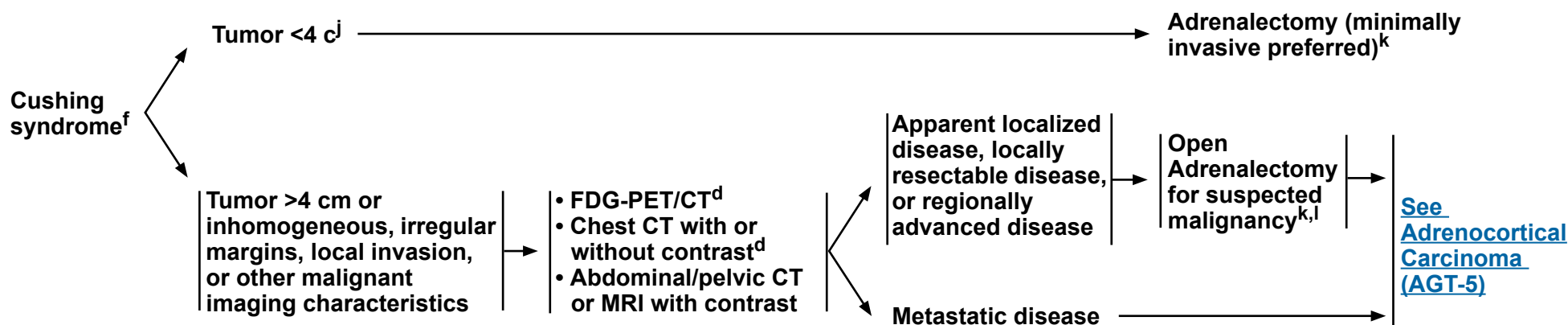
Clinical Trials: NCCN believes that the best management of any patient with cancer is in a clinical trial. Participation in clinical trials is especially encouraged.



CLINICAL DIAGNOSIS

ADDITIONAL EVALUATION

PRIMARY TREATMENT



^d See Principles of Imaging (NE-B).

^f For benign-appearing lesions, refer to the Endocrine Society's Clinical Practice Guidelines for the Treatment of Cushing's Syndrome (Nieman LK, et al. J Clin Endocrinol Metab 2015;100:2807-2831).

^j Some centers may use 6 cm as cutoff.

^k Perioperative management should include stress-dose steroids (eg, methylprednisolone or hydrocortisone).

^l May require removal of adjacent structures (ie, liver, kidney, pancreas, spleen, diaphragm) for complete resection.

Note: All recommendations are category 2A unless otherwise indicated.

Clinical Trials: NCCN believes that the best management of any patient with cancer is in a clinical trial. Participation in clinical trials is especially encouraged.



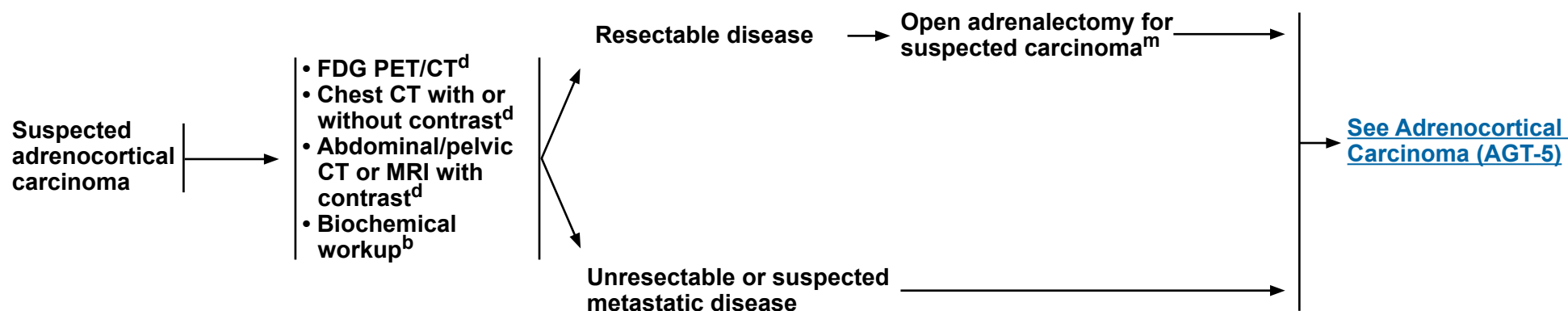NCCN Guidelines Version 4.2021

Adrenal Gland Tumors

CLINICAL DIAGNOSIS

ADDITIONAL EVALUATION

PRIMARY TREATMENT



^b See Principles of Biochemical Testing (NE-C).

^d See Principles of Imaging (NE-B).

^m If size is resectable by laparoscopy, may explore with a minimally invasive approach with planned conversion for evidence of local invasion. The decision for open versus minimally invasive surgery is based on tumor size and degree of concern regarding potential malignancy, and local surgical expertise.

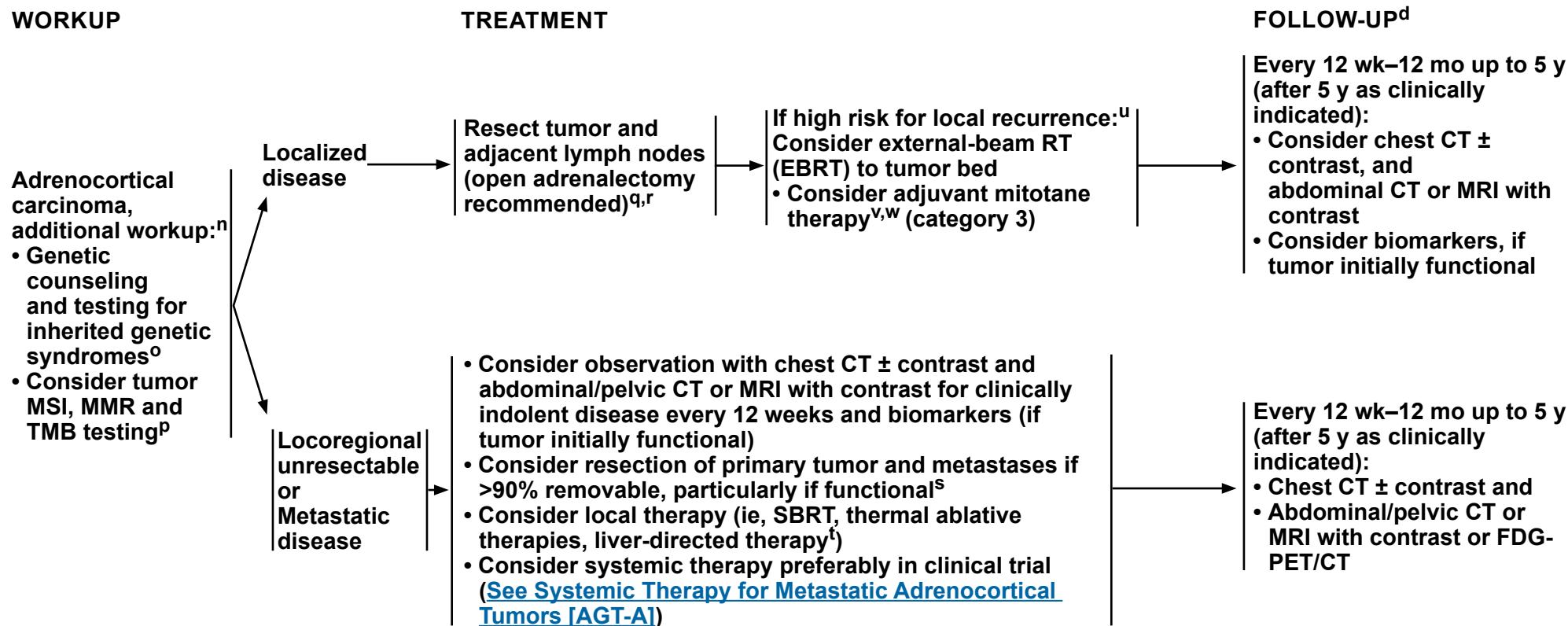
Note: All recommendations are category 2A unless otherwise indicated.

Clinical Trials: NCCN believes that the best management of any patient with cancer is in a clinical trial. Participation in clinical trials is especially encouraged.



NCCN Guidelines Version 4.2021

Adrenal Gland Tumors


^d See Principles of Imaging (NE-B).

ⁿ Staging workup, see AGT-4.

^o See Principles of Genetic Risk Assessment and Counseling (NE-E).

^p FDA-approved test recommended for determination of TMB.

^q May require removal of adjacent structures (ie, liver, kidney, pancreas, spleen, diaphragm) for complete resection.

^r It is important to achieve negative margins and avoid breaching the tumor capsule. There may be an increased risk for local recurrence and peritoneal spread when done with a minimally invasive approach.

^s If bulky disease, or <90% is removable, surgery can be reconsidered following response to systemic therapy.

^t See Principles of Liver-Directed Therapy for Neuroendocrine Tumor Metastases (NE-H).

^u High-risk local recurrence features include: positive margins, Ki-67 >10%, rupture of capsule, large size, and high grade.

^v Monitor mitotane blood levels. Some institutions recommend target levels of 14–20 mcg/mL if tolerated. Steady-state levels may be reached several months after initiation of mitotane. Life-long hydrocortisone ± fludrocortisone replacement may be required with mitotane.

^w Mitotane may have more benefit for control of hormone symptoms than control of tumor.

Note: All recommendations are category 2A unless otherwise indicated.

Clinical Trials: NCCN believes that the best management of any patient with cancer is in a clinical trial. Participation in clinical trials is especially encouraged.



SYSTEMIC THERAPY FOR LOCOREGIONAL UNRESECTABLE/METASTATIC ADRENOCORTICAL CARCINOMA^x

Preferred Regimens	Other Recommended Regimens	Useful in Certain Circumstances
<ul style="list-style-type: none"> • Cisplatin + etoposide¹ ± doxorubicin ± mitotane^{v,w,2} • Carboplatin + etoposide ± doxorubicin ± mitotane^{v,w} 	<ul style="list-style-type: none"> • Pembrolizumab^{3,4} ± mitotane^{v,w} • Mitotane monotherapy^{v,w} 	<ul style="list-style-type: none"> • Streptozocin ± mitotane^{v,w,2}

References

¹ Williamson SK, Lew D, Miller GJ, et al. Phase II evaluation of cisplatin and etoposide followed by mitotane at disease progression in patients with locally advanced or metastatic adrenocortical carcinoma: a Southwest Oncology Group Study. *Cancer* 2000;88:1159-1165.

² Fassnacht M, Terzolo M, Allolio B, et al. Combination chemotherapy in advanced adrenocortical carcinoma. *N Engl J Med*. 2012;366(23):2189-2197. doi:10.1056/NEJMoa1200966

³ Raj N, Zheng Y, Kelly V, et al. PD-1 blockade in advanced adrenocortical carcinoma. *J Clin Oncol* 2020;38:71-80.

⁴ Habra MA, Stephen B, Campbell M, et al. Phase II clinical trial of pembrolizumab efficacy and safety in advanced adrenocortical carcinoma. *J Immunother Cancer* 2019;7:253.

^v Monitor mitotane blood levels. Some institutions recommend target levels of 14–20 mcg/mL if tolerated. Steady-state levels may be reached several months after initiation of mitotane. Life-long hydrocortisone ± fludrocortisone replacement may be required with mitotane.

^w Mitotane may have more benefit for control of hormone symptoms than control of tumor.

^x [See Discussion](#) for further information regarding the phase III FIRM-ACT trial.

Note: All recommendations are category 2A unless otherwise indicated.

Clinical Trials: NCCN believes that the best management of any patient with cancer is in a clinical trial. Participation in clinical trials is especially encouraged.



NCCN Guidelines Version 4.2021

Pheochromocytoma/Paraganglioma

TUMOR TYPE	EVALUATION ^{a,b,c}	PRIMARY TREATMENT
Pheochromocytoma/ paraganglioma	<p>Recommended:</p> <ul style="list-style-type: none"> • Plasma free or 24-hour urine fractionated metanephrines and normetanephrines^{b,d,e} ± serum or 24-hour urine catecholamines^f • Adrenal protocol CT (abdomen/pelvis) • Genetic counseling and testing for inherited genetic syndromes^h <p>As appropriate, if metastatic or multifocal disease suspected:ⁱ</p> <ul style="list-style-type: none"> • Abdominal/pelvic multiphasic CT or MRI^g • SSR-PET/CT or SSR-PET/MRI^{e,j,k} • FDG-PET/CT (skull base to mid-thigh) • Chest CT with or without contrast • MIBG scan^l 	See Primary Treatment (PHEO-2)

^a [See Principles of Pathology for Diagnosis and Reporting of Neuroendocrine Tumors \(NE-A\).](#)

^b [See Principles of Biochemical Testing \(NE-C\).](#)

^c Consider medical alert ID for hormonally secreting pheochromocytomas and paragangliomas in situ or metastatic disease.

^d Review concurrent medication(s) for those that may interfere with plasma metanephrines evaluation. Elevations that are 3 times above the upper limit of normal are diagnostic.

^e For cervical paraganglioma, consider measuring serum and/or 24-hour urine fractionated catecholamines (for dopamine).

^f Both catecholamines and metanephrines/normetanephrines can produce false-positive results ([see NE-C](#)).

^g [See Principles of Imaging \(NE-B\).](#)

^h [See Principles of Genetic Risk Assessment and Counseling \(NE-E\).](#)

ⁱ Data on the role of functional imaging in pheochromocytoma/paraganglioma are evolving and the preferred method remains unclear.

^j PET/CT or PET/MRI of skull base to mid-thigh with IV contrast when possible.

^k SSR PET tracers include: 68Ga-DOTATATE, 64Cu-DOTATATE, 68Ga-DOTATOC.

^l MIBG scans are less sensitive than FDG-PET and 68Ga-dotatate for metastatic and multifocal paragangliomas/pheochromocytomas. Obtain MIBG scan if considering treatment with I131-MIBG.

Note: All recommendations are category 2A unless otherwise indicated.

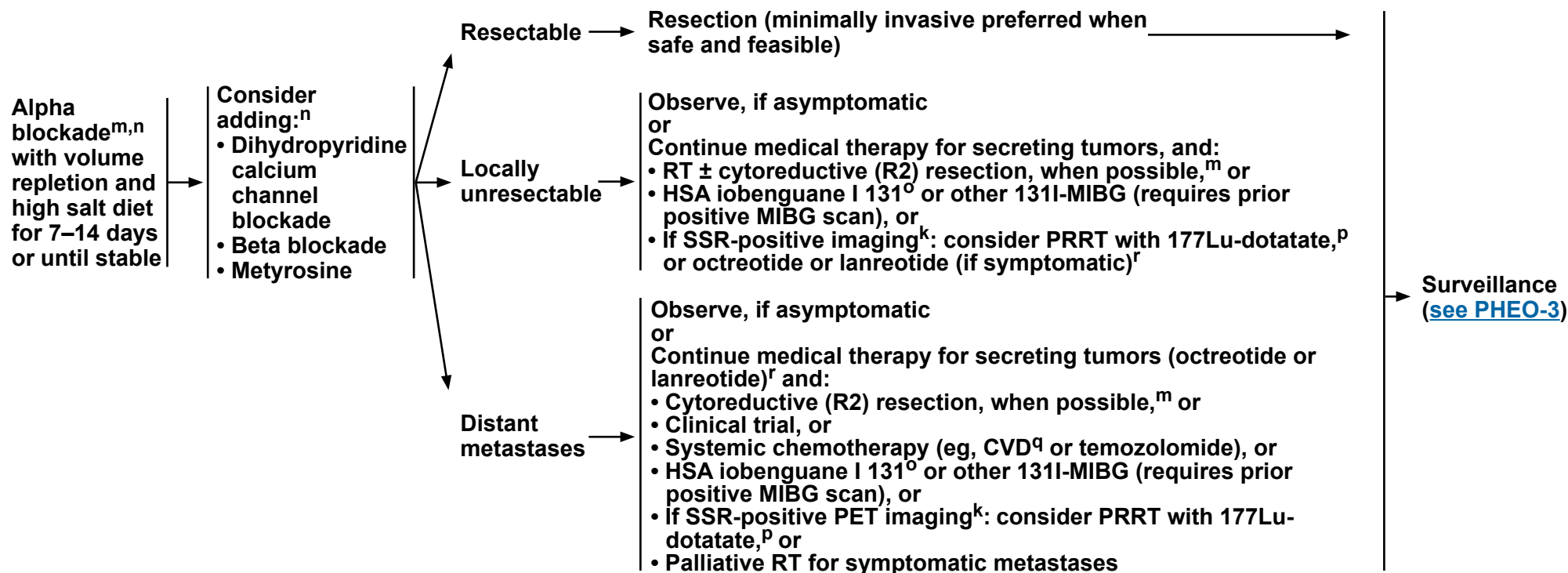
Clinical Trials: NCCN believes that the best management of any patient with cancer is in a clinical trial. Participation in clinical trials is especially encouraged.



NCCN Guidelines Version 4.2021

Pheochromocytoma/Paraganglioma

PRIMARY TREATMENT^c



^c Consider medical alert ID for hormonally secreting pheochromocytomas and paragangliomas in situ or metastatic disease.

^k SSR PET tracers include: 68Ga-DOTATATE, 64Cu-DOTATATE, 68Ga-DOTATOC.

^m Alpha 1 selective receptor blockers include terazosin, doxazosin, and prazosin, and non-selective receptor blockers include phenoxymethamine. Therapy for 7–14 days is recommended prior to surgical therapy. Nonselective alpha blockade phentolamine (IV) can be used intraoperatively.

ⁿ Alpha blockade is first-line therapy for all hormonally secreting pheochromocytomas and paragangliomas. After alpha blockade, if additional blood pressure (bp) support is needed, the addition of dihydropyridine calcium channel blockers can be used. This is not recommended as monotherapy unless the patient cannot tolerate alpha blockade. Metyrosine can also be used in addition to alpha blockade to stabilize bp. Beta blockade can be added to alpha blockade for tachycardia. B1 selective blockers or nonselective beta blockers can be used. Combination beta/alpha blockers are not recommended.

^o HSA iobenguane I 131 is an FDA-approved option.

^p Data are limited on the use of PRRT with 177Lu-dotatate in this setting. [See Principles of PRRT with 177Lu-dotatate \(NE-G\)](#).

^q CVD = cyclophosphamide, vincristine, and dacarbazine

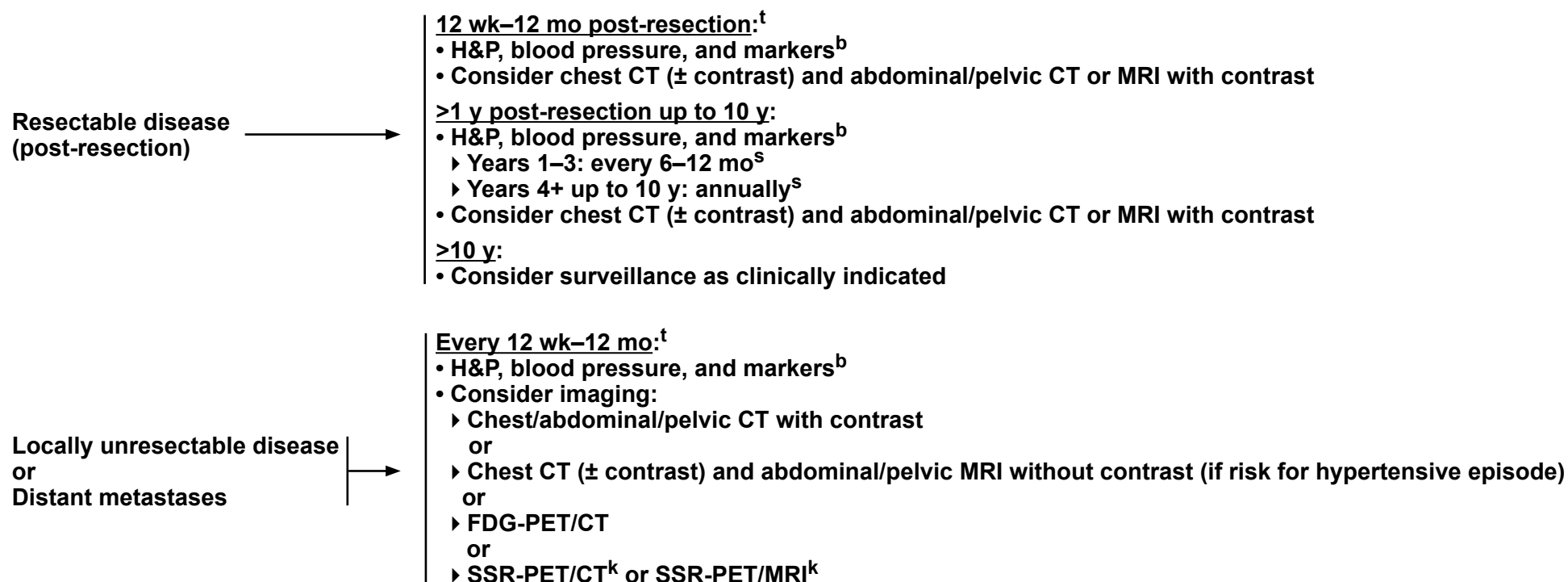
^r For symptom control, octreotide 150–250 mcg SC TID or octreotide LAR 20–30 mg IM or lanreotide 90–120 mg SC every 4 weeks. Dose and frequency may be further increased for symptom control as needed. Therapeutic levels of octreotide would not be expected to be reached for 10–14 days after LAR injection. Short-acting octreotide can be added to octreotide LAR for rapid relief of symptoms or for breakthrough symptoms. For details on the administration of short-acting and/or long-acting octreotide with 177Lu-dotatate, [see NE-G](#).

Note: All recommendations are category 2A unless otherwise indicated.

Clinical Trials: NCCN believes that the best management of any patient with cancer is in a clinical trial. Participation in clinical trials is especially encouraged.



SURVEILLANCE^s



^b See [Principles of Biochemical Testing \(NE-C\)](#).

^j PET/CT or PET/MRI of skull base to mid-thigh with IV contrast when possible.

^k SSR PET tracers include: 68Ga-DOTATATE, 64Cu-DOTATATE, 68Ga-DOTATOC.

^s See [NCCN Guidelines for Survivorship](#).

^t Earlier, if symptoms; less frequently if stable disease and no new symptoms.

Note: All recommendations are category 2A unless otherwise indicated.

Clinical Trials: NCCN believes that the best management of any patient with cancer is in a clinical trial. Participation in clinical trials is especially encouraged.



NCCN Guidelines Version 4.2021

Multiple Endocrine Neoplasia, Type 1

CLINICAL EVALUATION^b

TREATMENT

Parathyroid:

- Serum calcium
- If calcium elevated:
 - PTH and 25-OH vitamin D
 - Imaging^{a,c} (neck ultrasound, parathyroid sestamibi with SPECT scan, or 4D-CT)

Subtotal parathyroidectomy
± cryopreservation of parathyroids
± thymectomy
or
Total parathyroidectomy with
autotransplantation ± cryopreservation
of parathyroids ± thymectomy

[See MEN1
Surveillance
\(MEN1-2\)](#)

PanNET:^d

- Recommended
 - Biochemical evaluation as clinically indicated ([See NE-C](#))
 - Abdominal ± pelvic multiphasic CT or MRI^c
- As appropriate
 - EUS
- SSR-PET/CT or SSR-PET/MRI^{c,e,f}

[See Treatment of PanNETs Specific
to MEN1 Patients \(MEN1-A\)](#)
and
See appropriate sporadic PanNET
workup and treatment ([PanNET-1](#)
through [PanNET-5](#))

[See MEN1
Surveillance
\(MEN1-2\)](#)

Pituitary:

- Recommended
 - Pituitary or sella MRI with contrast
 - Biochemical evaluation as clinically indicated ([See NE-C](#))

Consider referral to
endocrinology for further workup

[See MEN1
Surveillance
\(MEN1-2\)](#)

Bronchial/Thymic:

- Chest CT with contrast and abdominal/
pelvic multiphasic CT or MRI
- Biochemical evaluation as clinically
indicated ([See NE-C](#))

See appropriate bronchopulmonary/
thymus workup and treatment ([NET-6](#))

Clinical diagnosis of
MEN1
• Genetic
counseling
and testing for
inherited genetic
syndromes^b

^b [See Principles of Genetic Risk Assessment and Counseling \(NE-E\).](#)

^c [See Principles of Imaging \(NE-B\).](#)

^d van Treijen MJC, et al. J Endocr Soc 2018;2:1067-1088.

^e PET/CT or PET/MRI of skull base to mid-thigh with IV contrast when possible. Data are limited on the optimal timing of scans following administration of SSAs.

^f SSR PET tracers include: 68Ga-DOTATATE, 64Cu-DOTATATE, 68Ga-DOTATOC.

Note: All recommendations are category 2A unless otherwise indicated.

Clinical Trials: NCCN believes that the best management of any patient with cancer is in a clinical trial. Participation in clinical trials is especially encouraged.



MEN1 SURVEILLANCE^{g,h}

Patients with MEN1 should be screened for all of the following tumor types:

Parathyroid:

- Calcium annually

- If calcium rises:

- PTH
- 25-OH vitamin D
- Re-image with neck ultrasound and/or parathyroid sestamibi with SPECT scan (SPECT-CT preferred) or 4D-CT^{a,h}

PanNET:

- Follow previously elevated serum hormones or as symptoms indicate
- Consider abdominal/pelvic CT or MRI^{c,h} with contrast every 1–3 y
- Consider serial EUS

See appropriate sporadic PanNET workup and treatment ([PanNET-1](#) through [PanNET-5](#))

Pituitary:

- Pituitary or sella MRI with contrast of pituitary every 3–5 y
- Prolactin, IGF-1, and other previously abnormal pituitary hormones every 3–5 y or as symptoms indicate

Bronchial/Thymic:

- Consider chest CT or MRI^{c,h} with contrast every 1–3 y

See appropriate workup and treatment for thymic ([NET-6](#)) or bronchial ([NET-7](#))

^a Preference of scan will depend on institutional practice/protocol. Sestamibi may not be as sensitive since often the patient has hyperplasia. [See Principles of Imaging \(NE-B\)](#).

^c [See Principles of Imaging \(NE-B\)](#).

^g Consider referral to an endocrinologist.

^h For prolonged surveillance, studies without radiation are preferred.

Note: All recommendations are category 2A unless otherwise indicated.

Clinical Trials: NCCN believes that the best management of any patient with cancer is in a clinical trial. Participation in clinical trials is especially encouraged.



TREATMENT OF PanNETs SPECIFIC TO MEN1 PATIENTS¹⁻⁴

- In general, surgical management of patients with MEN1 is similar to those with sporadic tumors. Refer to the relevant site-specific recommendations for PanNETs earlier in these guidelines. (See [PanNET-1](#) through [PanNET-5](#))
- However, one notable exception is the multi-focality of pancreaticoduodenal NETs in patients with MEN1. The role of surgery remains controversial in patients with multifocal tumors.
- Decision to resect a pancreatic or duodenal NET in the setting of multifocal disease is complex. If surgery is performed to resect hormonally functional tumor(s), attempts should be made to preoperatively localize the site of the functional tumor. Surgical resection can be considered in the following scenarios:
 - ▶ Symptomatic functional tumors refractory to medical management
 - ▶ Tumor larger than 2 cm in size
 - ▶ Tumor with relatively rapid rate of growth over 6–12 months
- Endoscopy with EUS is recommended prior to pancreatic surgery in order to preoperatively assess and localize tumors.
- MEN1-associated metastatic PanNETs are often slower growing than metastatic sporadic tumors. Observation can be considered for non-functioning indolent tumors.

¹ Yates CJ, Newey PJ, Thakker RV. Challenges and controversies in management of pancreatic neuroendocrine tumours in patients with MEN1. *Lancet Diabetes Endocrinol* 2015;3:895-905.

² Frost M, Lines KE, Thakker RV. Current and emerging therapies for PNETs in patients with or without MEN1. *Nat Rev Endocrinol* 2018;14:216-227.

³ Faggiano A, Modica R, Lo Calzo F, et al. Lanreotide therapy vs active surveillance in MEN1-related pancreatic neuroendocrine tumors < 2 centimeters. *J Clin Endocrinol Metab* 2020;105:dgz007.

⁴ Niederle B, Selberherr A, Bartsch D, et al. Multiple Endocrine Neoplasia Type 1 (MEN1) and the Pancreas - Diagnosis and Treatment of Functioning and Non-Functioning Pancreatic and Duodenal Neuroendocrine Neoplasia within the MEN1 Syndrome - An International Consensus Statement [published online ahead of print September 24, 2020]. *Neuroendocrinology* 2020.

Note: All recommendations are category 2A unless otherwise indicated.

Clinical Trials: NCCN believes that the best management of any patient with cancer is in a clinical trial. Participation in clinical trials is especially encouraged.



NCCN Guidelines Version 4.2021

Multiple Endocrine Neoplasia, Type 2

CLINICAL EVALUATION^a

TREATMENT^f

SURVEILLANCE

**Clinical diagnosis
of MEN2**
• Genetic
counseling
and testing for
inherited genetic
syndromes^a

Medullary thyroid cancer:
• Calcitonin, CEA
• Neck ultrasound of both thyroid
and cervical lymph nodes

[See NCCN Guidelines for Medullary Thyroid Carcinoma](#)

Parathyroid:
• Serum calcium
• If calcium elevated:
▸ PTH and 25-OH vitamin D
▸ Imaging^b (neck
ultrasound, parathyroid
sestamibi with SPECT
scan, or 4D-CT)

Parathyroidectomy^g

[See NCCN Guidelines for
Medullary Thyroid Carcinoma](#)

Pheochromocytoma^{c,d,e}

[See Pheochromocytoma Guidelines \(PHEO-1\)](#)

^a [See Principles of Genetic Risk Assessment and Counseling \(NE-E\).](#)

^b Preference of scan will depend on institutional practice/protocol. Sestamibi scan may not be as sensitive as other imaging options since often the patient has hyperplasia. [See Principles of Imaging \(NE-B\).](#)

^c Evaluation of pheochromocytoma should be done before the administration of any anesthetic or invasive procedure.

^d More likely to be multifocal.

^e For synchronous bilateral pheochromocytomas, a bilateral adrenalectomy is recommended.

^f For the treatment of synchronous tumors, surgical resection of pheochromocytoma should take priority over thyroidectomy for medullary thyroid cancer.

^g Subtotal parathyroidectomy is recommended when all the parathyroid glands are abnormal. Some thyroid surgeons recommend total parathyroidectomy with parathyroid autotransplantation, but others believe the risk of hypoparathyroidism (~6%) is too high to warrant this procedure.

Note: All recommendations are category 2A unless otherwise indicated.

Clinical Trials: NCCN believes that the best management of any patient with cancer is in a clinical trial. Participation in clinical trials is especially encouraged.



PRINCIPLES OF PATHOLOGY FOR DIAGNOSIS AND REPORTING OF NEUROENDOCRINE TUMORS

Required Information:

- Anatomic site of tumor
- Diagnosis
- Mitotic rate and/or Ki-67
- Size of tumor
- Presence of multicentric disease
- Presence of vascular invasion
- Presence of perineural invasion
- Presence of other pathologic components (eg, non-neuroendocrine components)
- Lymph node metastases to include the number of positive nodes and total number of nodes examined
- Margin status (report as positive or negative)
- Assign TNM stage per the AJCC TNM system ([See Staging](#))

Optional Information:

- Immunohistochemical staining for general neuroendocrine markers
- Presence of nonischemic tumor necrosis
- Presence of unusual histologic features (eg, oncocytic, clear cell, gland forming)
- Exact distance of tumor to margin(s) if less than 0.5 cm
- Background pathology of organ (ie, PanIN, ECL cell hyperplasia)

Note: All recommendations are category 2A unless otherwise indicated.

Clinical Trials: NCCN believes that the best management of any patient with cancer is in a clinical trial. Participation in clinical trials is especially encouraged.



PRINCIPLES OF PATHOLOGY FOR DIAGNOSIS AND REPORTING OF NEUROENDOCRINE TUMORS

2019 WHO Classification and Grading Criteria for Neuroendocrine Neoplasms of the Gastrointestinal Tract and Hepatopancreatobiliary Organs

Terminology	Differentiation	Grade	Mitotic rate ^a (mitoses/2 mm ²)	Ki-67 index ^a (percent)
NET, G1	Well-differentiated	Low	<2	<3
NET, G2	Well-differentiated	Intermediate	2 to 20	3 to 20
NET, G3	Well-differentiated	High	>20	>20
Neuroendocrine carcinoma (NEC), small cell type (SCNEC)	Poorly differentiated	High ^b	>20	>20
NEC, large cell type (LCNEC)	Poorly differentiated	High ^b	>20	>20
Mixed neuroendocrine-non-neuroendocrine neoplasm	Well or poorly differentiated ^c	Variable ^c	Variable ^c	Variable ^c

Reprinted with permission from: WHO Classification of Tumours. Digestive System Tumours, 5th ed, Klimstra DS, Kloppel G, La Rosa S, Rindi G, the WHO Classification of Tumours Editorial Board (Ed), the WHO classification of neuroendocrine neoplasms of the digestive system, p.16, Copyright © 2019 International Agency for Research on Cancer.

^a Mitotic rates are to be expressed as the number of mitoses/2 mm² (equaling 10 high-power fields at 40× magnification and an ocular field diameter of 0.5 mm) as determined by counting in 50 fields of 0.2 mm² (ie, in a total area of 10 mm²); the Ki-67 proliferation index value is determined by counting at least 500 cells in the regions of highest labeling (hot spots), which are identified at scanning magnification; the final grade is based on whichever of the two proliferation indexes places the neoplasm in the higher grade category.

^b Poorly differentiated NECs are not formally graded but are considered high grade by definition.

^c In most MiNENs, both the neuroendocrine and non-neuroendocrine components are poorly differentiated, and the neuroendocrine component has proliferation indexes in the same range as other NECs, but this conceptual category allows for the possibility that one or both components may be well differentiated; when feasible, each component should therefore be graded separately.

Note: All recommendations are category 2A unless otherwise indicated.

Clinical Trials: NCCN believes that the best management of any patient with cancer is in a clinical trial. Participation in clinical trials is especially encouraged.



PRINCIPLES OF PATHOLOGY FOR DIAGNOSIS AND REPORTING OF NEUROENDOCRINE TUMORS

2015 WHO Criteria for the Diagnosis of Pulmonary NET

Tumor type	Criteria
Typical carcinoid	Carcinoid morphology and <2 mitoses/ 2 mm^2 (10 high-power fields), lacking necrosis and $\geq 0.5\text{ cm}$
Atypical carcinoid	Carcinoid morphology with 2 to 10 mitoses/ 2 mm^2 (10 high-power fields) or necrosis (often punctuate)
Large cell neuroendocrine carcinoma	Neuroendocrine morphology (organoid nesting, palisading, rosettes, trabeculae); High mitotic rate $\geq 11/2\text{ mm}^2$ (10 HPFs), median of 70/ 2 mm^2 ; Necrosis (often large zones); Cytologic features of a NSCLC: large cell size, low nuclear to cytoplasmic ratio, vesicular or fine chromatin, and/or frequent nucleoli; some tumors have fine nuclear chromatin and lack nucleoli but qualify as non-small cell lung cancer because of large cell size and abundant cytoplasm; and Positive immunohistochemical staining for one or more neuroendocrine markers (other than neuron-specific enolase) and/or neuroendocrine granules by electron microscopy
Small cell neuroendocrine carcinoma	Small size (generally less than the diameter of three resting lymphocytes); Scant cytoplasm; Nuclei: finely granular nuclear chromatin, absent or faint nucleoli; High mitotic rate: ≥ 11 mitoses/ 2 mm^2 (10 high-power fields), median of 80/ 2 mm^2 (10 high-power fields); and Frequent necrosis, often in large zones

Reprinted from Travis WD, Colby TV, Corrin B, et al. (1999) WHO Histological Classification of Tumours. Histological Typing of Lung and Pleural Tumours. 3rd ed. Berlin: Springer.

Note: All recommendations are category 2A unless otherwise indicated.

Clinical Trials: NCCN believes that the best management of any patient with cancer is in a clinical trial. Participation in clinical trials is especially encouraged.



PRINCIPLES OF PATHOLOGY FOR DIAGNOSIS AND REPORTING OF NEUROENDOCRINE TUMORS

Functional Status

- Functioning NETs should have the same pathologic diagnosis as the non-functioning NETs at the same anatomic site, since the functional status is based upon clinical symptoms and should not alter the pathologic diagnosis.

Immunohistochemistry and Other Ancillary Techniques

- Immunohistochemistry and other ancillary techniques may not be required to diagnose well-differentiated NETs when sufficient tumor material is available for histologic review.
- Specific markers that may be used to establish neuroendocrine differentiation include chromogranin A, synaptophysin, and others. In less well-differentiated tumors or tumors of unknown origin, it may be helpful (or required in the case of poorly differentiated neuroendocrine carcinomas) to utilize immunohistochemistry panels.
- Although not entirely specific, lung origin is favored by thyroid transcription factor 1 (TTF-1); intestinal origin by CDX2; and pancreatic NETs by Isl1 and PAX8.^{1,2}

Classification and Grade

- Many classification schemes have been proposed for NETs.³⁻¹¹ The most recent WHO classification system is suggested for gastroenteropancreatic (GEP) NETs and represents an attempt to unify European and American approaches.⁹ Multiple site-specific grading systems also exist.
- Therefore, the specific classification and grading scheme being utilized should be reported in parentheses after the diagnosis to avoid confusion with overlapping terminology and criteria used in other systems.
- The raw data used to derive the grade should be reported.
- Regardless of the system used, it is most important to realize that the term “neuroendocrine tumor” or “neuroendocrine carcinoma” without any further qualification as to grade is inadequate for prognostication and therapy and is inappropriate for pathology reporting.^{1,12}

Mitotic Rate

- Mitotic rate should be based on counting mitoses in the areas of highest mitotic density, and should be reported as the number of mitoses per 10 high-power field (HPF) or per 2 mm². Ten HPF is equivalent to 2 mm² on many microscopes, although the field size may vary slightly.^{4,5}
- Note that in cases where an accurate mitotic rate is precluded by inadequate tissue, such as in small biopsy samples including fine-needle aspiration (FNA), the Ki-67 index is the preferred method of establishing the proliferative rate.

Ki-67 Index

- Ki-67 index is reported as the percentage of positive tumor cells in the area of highest nuclear labeling. Although recommendations have been to count 2,000 tumor cells in order to determine the Ki-67 index, this is not practical in routine clinical practice. It is therefore currently acceptable to estimate the labeling index, despite the recognition that estimation is subject to limitations in reproducibility.¹²
- If both mitotic rate and Ki-67 index are used and these are discordant, it is currently recommended that the higher grade be used to assign classification.¹³
- The pathologist should report the actual parameters used to assign grade (ie, mitotic rate, proliferation index) so clinicians have the necessary information to make informed treatment decisions.
- Ki-67 immunohistochemistry should be analyzed and/or counted in the areas of highest activity referred to as “hot spots.”

Note: All recommendations are category 2A unless otherwise indicated.

Clinical Trials: NCCN believes that the best management of any patient with cancer is in a clinical trial. Participation in clinical trials is especially encouraged.

References



PRINCIPLES OF PATHOLOGY FOR DIAGNOSIS AND REPORTING OF NEUROENDOCRINE TUMORS

REFERENCES

- ¹ Klimstra DS, Modlin IR, Coppola D, et al. The pathologic classification of neuroendocrine tumors: a review of nomenclature, grading and staging systems. *Pancreas* 2010;39:707-712.
- ² Koo J, Mertens RB, Mirocha JM, et al. Value of Islet 1 and PAX8 in identifying metastatic neuroendocrine tumors of pancreatic origin. *Modern Pathology* 2012; 25:893-901.
- ³ Travis WD, Brambilla E, Burke AP, et al. WHO Classification of Tumours of the Lung, Pleura, Thymus and Heart. IARC, Lyon; 2015.
- ⁴ Rindi G, Kloppel G, Alhman H, et al. TNM staging of foregut (neuro)endocrine tumors: a consensus proposal including a grading system. *Virchows Arch* 2006;449:395-401.
- ⁵ Washington MK, Tang LH, Berlin J, et al. Protocol for the examination of specimens from patients with neuroendocrine tumors (carcinoid tumors) of the colon and rectum. *Arch Pathol Lab Med* 2010;134:176-180.
- ⁶ Strosberg JR, Coppola D, Klimstra DS, et al. The NANETS consensus guidelines for the diagnosis and management of poorly differentiated (high-grade) extrapulmonary neuroendocrine carcinomas. *Pancreas* 2010;39:799-800.
- ⁷ Boudreaux JP, Klimstra DS, Hassan MM et al. The NANETS consensus guideline for the diagnosis and management of neuroendocrine tumors: well-differentiated neuroendocrine tumors of the jejunum, ileum, appendix, and cecum. *Pancreas* 2010;39:753-766.
- ⁸ Anthony LB, Strosberg JR, Klimstra DS et al. The NANETS consensus guidelines for the diagnosis and management of gastrointestinal neuroendocrine tumors (NETs): well-differentiated NETs of the distal colon and rectum. *Pancreas* 2010;39:767-774.
- ⁹ Bosman F, Carneiro F, Hruban R, and Theise ND. WHO Classification of tumours of the digestive system. Lyon, France: IARC Press; 2010.
- ¹⁰ Oberg K and Castellano D. Current knowledge on diagnosis and staging of neuroendocrine tumors. *Cancer Metastasis Rev* 2011;30S:S3-S7.
- ¹¹ Lloyd RV, Osamaru RY, Klöppel G, et al. WHO Classification of Tumours of Endocrine Organs. IARC, Lyon, 2017.
- ¹² Klimstra DS, Modlin IR, Adsay NV, et al. Pathology reporting of neuroendocrine tumors: application of the Delphic consensus process to the development of a minimum pathology data set. *Am J Surg Pathol* 2010;34:300-313.
- ¹³ Rindi G, Bordi C, La Rosa S, et al. Gastroenteropancreatic (neuro)endocrine neoplasms: The histology report. *Digestive and Liver Disease* 2011;43S:S356-S360.

Note: All recommendations are category 2A unless otherwise indicated.

Clinical Trials: NCCN believes that the best management of any patient with cancer is in a clinical trial. Participation in clinical trials is especially encouraged.



PRINCIPLES OF IMAGING

Anatomic Imaging

- Cross-sectional imaging should include the primary site of disease. Either CT or MRI is appropriate.
- The liver is a common metastatic site for NET, and these metastatic lesions are often hypervascular. Therefore, multiphasic imaging of the liver with contrast enhancement (arterial and portal venous phase) should be performed whenever possible. Following arterial-phase imaging of the liver, imaging of the abdomen and pelvis can be performed in the portal-venous phase of enhancement. Oral contrast may be helpful to delineate discrete lesions within the bowel.
- Without a known tumor or specific clinical concern, imaging of the chest is optional for GI NET and imaging of the brain is generally not required for well-differentiated NET.
- For metastatic well-differentiated NET, anatomic imaging should generally be performed every 12 weeks–12 months based on clinical or pathologic signs of aggressiveness.
- Consider MRI over CT to minimize radiation risk.
- MRI preferred for pregnant patients.

Functional Imaging^a

- Evaluation with somatostatin receptor (SSR) imaging to assess receptor status and distant disease is appropriate. This is especially important for determining whether a patient may benefit from SSR-directed therapy.
 - ▶ SSR-based imaging options include SSR-PET/CT or SSR-PET/MRI, or octreotide SPECT/CT (only if SSR-PET is not available)
 - ▶ Appropriate SSR-PET tracers include 68Ga-DOTATATE, 68Ga-DOTATOC, or 64Cu-DOTATATE.
 - ▶ SSR-positive if uptake in measurable lesions is greater than liver.

- Whenever possible, SSR-PET/CT should be performed in combination with contrast-enhanced CT or MRI (dual-phase hepatic CT or MRI imaging preferred) to minimize the total number of imaging studies. The contrast-enhanced CT or MRI is vital to identify lesions that are SSR-negative as well as those that are SSR-positive.
- Octreotide SPECT/CT is much less sensitive for defining SSR-positive disease than SSR-PET/CT, and typically cannot be done in combination with multiphase CT or MRI. Therefore, SSR-PET/CT or SSR-PET/MRI is preferred.
- In selected cases where high-grade NET or poorly differentiated neuroendocrine carcinoma is documented or suspected or where disease is growing rapidly, FDG-PET/CT may be useful to identify high-grade active disease.
- As with SSR-PET/CT, combining FDG-PET with dual-phase liver CT or MRI is preferred.

Surveillance

- After potentially curative surgery, surveillance is recommended for at least 10 years for most patients. In certain cases, surveillance may be extended beyond 10 years based on risk factors such as age and risk of recurrence. However, data are limited on the optimal surveillance schedule beyond 10 years.

Transthoracic Echocardiogram (ECHO)^b to Assess for Carcinoid (NET-related) Heart Disease

- Echocardiogram (transthoracic echocardiography, TTE) is important for the evaluation of carcinoid heart disease (CHD) and should include morphologic evaluation of the valves (especially tricuspid and pulmonic) and the right heart.

^a Data on the role of functional imaging in pheochromocytoma/paraganglioma is evolving and the preferred method remains unclear.

^b Castillo JC, Maib T, Zacks JS, Adams DH. Echocardiography in functional midgut neuroendocrine tumors: When and how often. Rev Endocr Metab Disord 2017;18:411-421.

Note: All recommendations are category 2A unless otherwise indicated.

Clinical Trials: NCCN believes that the best management of any patient with cancer is in a clinical trial. Participation in clinical trials is especially encouraged.



NCCN Guidelines Version 4.2021

Neuroendocrine and Adrenal Tumors

PRINCIPLES OF BIOCHEMICAL TESTING¹⁻¹⁰

- Some NETs can secrete specific neuroendocrine hormones. Hormonal workup should be guided by the presence of symptoms of the excess hormone. Screening for hormones in asymptomatic individuals is not routinely required.
- Proton pump inhibitors, other drugs, some medical conditions, and certain foods are known to cause false elevations in serum gastrin and chromogranin A.
- If MEN2 is suspected, then patients should be evaluated for pheochromocytoma/paraganglioma prior to any procedures.⁹
- In select cases, chromogranin A may have prognostic value but treatment decisions are not based solely on changes in chromogranin.

	Location	Clinical Symptoms	Testing
NETs of Gastrointestinal Tract, Lung, and Thymus	Primary tumors in GI tract (ileum, appendix, rectum), lung, or thymus	<ul style="list-style-type: none"> • Primary tumors in the GI tract usually are not associated with symptoms of hormone secretion unless extensive metastasis. • Symptoms of hormone secretion may include flushing, diarrhea, cardiac valvular fibrosis, and bronchoconstriction. • Bronchial/thymic tumors may be associated with classic carcinoid syndrome as well as Cushing syndrome. 	<ul style="list-style-type: none"> • 24-hour urine or plasma 5-HIAA <ul style="list-style-type: none"> ▸ Foods to avoid for 48 hours prior to and during testing: avocados, bananas, cantaloupe, eggplant, pineapples, plums, tomatoes, hickory nuts/pecans, plantains, kiwi, dates, grapefruit, honeydew, or walnuts. • Test for Cushing syndrome (NE-C, 2 of 3)
PanNET: PPoma	Pancreas	Clinically silent	• Serum pancreatic polypeptide (category 3)
PanNET: Insulinoma	Pancreas	Hypoglycemia	<ul style="list-style-type: none"> • While hypoglycemic: <ul style="list-style-type: none"> ▸ Serum insulin ▸ Pro-insulin ▸ C-peptide • See Workup for insulinoma (PanNET-3)
PanNET: VIPoma	Most common in pancreas, can be extra pancreatic	Diarrhea, hypokalemia	Serum VIP
PanNET: Glucagonoma	Pancreas	Flushing, diarrhea, hyperglycemia, dermatitis, hypercoagulable state	Serum glucagon
PanNET: Gastrinoma	Pancreas or duodenum	Gastric ulcers, duodenal ulcers, diarrhea	Serum gastrin ^a

^a Basal, stimulated as indicated.

Note: All recommendations are category 2A unless otherwise indicated.

Clinical Trials: NCCN believes that the best management of any patient with cancer is in a clinical trial. Participation in clinical trials is especially encouraged.

References



NCCN Guidelines Version 4.2021

Neuroendocrine and Adrenal Tumors

PRINCIPLES OF BIOCHEMICAL TESTING¹⁻¹⁰

	Location	Symptoms	Testing
Pheochromocytoma/Paraganglioma	Adrenal or extra-adrenal sympathetic or parasympathetic chain	Hypertension, tachycardia, sweating, syncope	<ul style="list-style-type: none"> • Plasma free or 24-hour urine fractionated metanephrines^d • Cervical paragangliomas: consider serum and urine catecholamines or methoxytyramine (the metabolite of dopamine)^c
Pituitary Tumor	Pituitary (part of MEN1)	May be asymptomatic, depends on the hormone secreted	<ul style="list-style-type: none"> • Serum IGF-1 (category 2B) • Serum prolactin • LH/FSH • Alpha subunits • TSH (free T4) • Screen for Cushing syndrome
Cushing Syndrome^b	Adrenal, pituitary, or ectopic (often bronchial or thymic)	Central weight gain, striae, hypertension, hyperglycemia, depression, hirsutism	<ul style="list-style-type: none"> • Screen for hypercortisolemia with 1 of the following tests^e: <ul style="list-style-type: none"> ▶ 1 mg overnight dexamethasone suppression test ▶ 2–3 midnight salivary cortisols ▶ 24-hour urinary free cortisol • Confirmatory testing if positive • Plasma ACTH
Hyperaldosteronism	Adrenal	Hypertension, hypokalemia	<ul style="list-style-type: none"> • Screening: Suppressed renin/renin activity in association with an elevated plasma aldosterone level (> 15 ng/dL)¹¹ • Confirmatory testing if positive^c
Suspected or Confirmed Adrenocortical Carcinoma	Adrenal	Symptoms of Cushing syndrome or hyperaldosteronism (see above) Androgen excess symptoms	<ul style="list-style-type: none"> • See workup above for Cushing syndrome or hyperaldosteronism • Testosterone • DHEA-S

^b For additional information on biochemical testing for Cushing syndrome, refer to the Endocrine Society's Clinical Practice Guidelines for the Treatment of Cushing's Syndrome: Nieman LK, Biller BMK, Findling JW, et al. Treatment of Cushing's Syndrome: An Endocrine Society Clinical Practice Guideline. J Clin Endocrinol Metab 2015;100:2807-2831.

^c 24-hour urine for aldosterone, sodium and potassium should be considered for definitive diagnosis.

^d Some drugs may interfere with testing results, including: acetaminophen, labetalol, sotalol, α -methyl dopa, tricyclic antidepressants, buspirone, phenoxybenzamine, MAO inhibitors, sympathomimetics, cocaine, sulfasalazine, and levodopa. (Lenders J, Duh QY, Eisenhofer G, et al. Guidelines on pheochromocytoma and paraganglioma. J Clin Endocrinol Metab June 2014;99:1915-1942)

^e Petrosal vein sampling can be considered to differentiate adrenal from pituitary and ectopic causes..

Note: All recommendations are category 2A unless otherwise indicated.

Clinical Trials: NCCN believes that the best management of any patient with cancer is in a clinical trial. Participation in clinical trials is especially encouraged.

References



PRINCIPLES OF BIOCHEMICAL TESTING REFERENCES

- ¹ Kaltsas G, Androulakis, II, de Herder WW, Grossman AB. Paraneoplastic syndromes secondary to neuroendocrine tumours. *Endocr Relat Cancer* 2010;17:R173-193.
- ² Oberg K. Diagnostic work-up of gastroenteropancreatic neuroendocrine tumors. *Clinics (Sao Paulo)* 2012;67 Suppl 1:109-112.
- ³ Van Der Horst-Schrivers AN, Osinga TE, Kema IP, et al. Dopamine excess in patients with head and neck paragangliomas. *Anticancer Res* 2010;30:5153-5158.
- ⁴ Raines D, Chester M, Diebold AE, et al. A prospective evaluation of the effect of chronic proton pump inhibitor use on plasma biomarker levels in humans. *Pancreas* 2012;41:508-511.
- ⁵ Lenders JW, Duh QY, Eisenhofer G, et al. Pheochromocytoma and paraganglioma: an endocrine society clinical practice guideline. *J Clin Endocrinol Metab* 2014;99:1915-1942.
- ⁶ Cryer PE, Axelrod L, Grossman AB, et al. Evaluation and management of adult hypoglycemic disorders: an Endocrine Society Clinical Practice Guideline. *J Clin Endocrinol Metab* 2009;94:709-728.
- ⁷ Nieman LK, Biller BM, Findling JW, et al. The diagnosis of Cushing's syndrome: an Endocrine Society Clinical Practice Guideline. *J Clin Endocrinol Metab* 2008;93:1526-1540.
- ⁸ Funder JW, Carey RM, Mantero F, et al. Case detection, diagnosis, and treatment of patients with primary aldosteronism: an endocrine society clinical practice guideline. *J Clin Endocrinol Metab* 2016;101:1889-1916.
- ⁹ Thakker RV, Newey PJ, Walls GV, et al. Clinical practice guidelines for multiple endocrine neoplasia type 1 (MEN1). *J Clin Endocrinol Metab* 2012;97:2990-3011.
- ¹⁰ Modlin IM, Oberg K, Taylor A, et al. Neuroendocrine tumor biomarkers: current status and perspectives. *Neuroendocrinology* 2014;100:265-277.
- ¹¹ Young WF Jr. Diagnosis and treatment of primary aldosteronism: practical clinical perspectives. *J Intern Med* 2019;285:126-148.

Note: All recommendations are category 2A unless otherwise indicated.

Clinical Trials: NCCN believes that the best management of any patient with cancer is in a clinical trial. Participation in clinical trials is especially encouraged.

**SURGICAL PRINCIPLES FOR MANAGEMENT OF NEUROENDOCRINE TUMORS**

- **Standard oncologic surgery (eg, distal pancreatectomy/splenectomy or pancreaticoduodenectomy) is appropriate for most resectable, non-metastatic pancreatic NETs. However, there are additional considerations for following circumstances:**
 - ▶ **Tumor enucleation should be considered primarily for insulinomas, which are highly symptomatic (hypoglycemic) but rarely malignant. Peripheral insulinomas should be considered for enucleation/ local resection or spleen-preserving distal pancreatectomy, when technically feasible.**
 - ▶ **For patients with small (<2 cm) low-grade NETs, decisions on surgery versus active surveillance need to be individualized, based on tumor size/characteristics and patient characteristics:**
 - ◊ **Tumors <1 cm have a lower malignant potential than tumors measuring 1–2 cm.**
 - ◊ **Other radiographic characteristics of small tumors (homogeneous, well-circumscribed) may also correlate with benign behavior.**
 - ◊ **Patient characteristics such as age and comorbidities are important when determining whether surveillance is appropriate.**
- **Resection for larger (>2 cm) or malignant-appearing non-functional and functional PanNETs (ie, glucagonoma, VIPoma, somatostatinoma) should include total removal of the tumor with negative margins (including adjacent organs) and regional lymph nodes. Tumors of the head are generally treated with pancreaticoduodenectomy (Whipple procedure); tumors of the body and tail are treated with distal pancreatectomy and splenectomy or spleen-preserving surgery. Generally surgery will include splenectomy, but with benign insulinoma spleen preservation should be considered.**
- **Resection of gastrointestinal NETs should include adequate regional lymph node resection (including all palpable disease where feasible) and thorough exploration of synchronous primary tumors (15%–30% incidence).**
- **Resection of recurrent locoregional disease, isolated distant metastases, or a previously unresectable tumor that has regressed should be considered for selected patients with adequate performance status.**
- **Cytoreductive surgery for distant metastatic disease (typically but not exclusively hepatic) is routinely recommended in patients in whom >90% of disease can be safely resected by surgery with or without ablation. This strategy is particularly appropriate for patients with relatively indolent metastatic small bowel NETs, and less appropriate for patients in whom rapid progression of disease is expected after surgery. Patients who are symptomatic from hormonal syndromes, such as carcinoid syndrome, typically derive palliation from cytoreductive surgery.**
- **Cholecystectomy is recommended when performing surgery for advanced NETs in patients anticipated to receive long-term octreotide therapy, as these patients are at higher risk of developing biliary symptoms and cholecystitis.**
- **Liver-directed therapies (eg, liver resection, thermal ablation, chemoembolization) for hepatic metastases from NETs following pancreaticoduodenectomy are associated with increased risk for cholangitis and liver abscess.**
- **Octreotide therapy should be administered parenterally prior to induction of anesthesia in patients with functional NETs to prevent carcinoid crisis.**
- **All patients who might require splenectomy should receive preoperative trivalent vaccine (ie, pneumococcus, haemophilus influenzae b, meningococcal group C).**
- **For MEN1-related surgical principles, see [MEN1-A](#).**

Note: All recommendations are category 2A unless otherwise indicated.

Clinical Trials: NCCN believes that the best management of any patient with cancer is in a clinical trial. Participation in clinical trials is especially encouraged.



PRINCIPLES OF GENETIC RISK ASSESSMENT AND COUNSELING HEREDITARY ENDOCRINE NEOPLASIAS

- The decision to offer genetic testing involves three related stages:
 - 1) Pre-test counseling prior to ordering testing;
 - 2) Consideration of the most appropriate testing strategy; and
 - 3) Testing result disclosure and post-test counseling.
- It is recommended that a genetic counselor, medical geneticist, endocrinologist, oncologist, surgeon, oncology nurse, or other health professional with expertise and experience in cancer genetics be involved at each stage whenever possible. Clinicians without direct referral access to the appropriate expertise should be aware of the telehealth genetic counseling options available. These resources can be found through the National Society of Genetic Counselors (NSGC) “Find a Genetic Counselor” tool (www.nsgc.org).

1) Pre-Test Counseling:

- Pre-test counseling includes the following elements:
 - ▶ Evaluation of patient’s knowledge, needs/concerns, and goals for familial risk assessment.
 - ▶ Detailed family history (including cancers/tumors and age at diagnosis, as well as clinical symptoms that can indicate an underlying endocrine neoplasia) in first-, second-, and third-degree family members on each side of the family.
 - ▶ Detailed past medical history and review of systems, including:
 - ◊ Documentation of prior genetic testing results for patients and their family members; and
 - ◊ Personal cancer/tumor history including age of diagnosis and treatment.
 - ▶ Focused physical examination (conducted by qualified clinician) when indicated.
 - ▶ Generation of differential diagnosis and educating the patient of inheritance pattern, penetrance, variable expressivity, and the possibility of genetic heterogeneity.
 - ▶ Discussion of possible genetic testing result outcomes, including positive (pathogenic or likely pathogenic), negative, and variants of unknown significance.
 - ▶ Discussion of the clinical implications of testing results to the patient.
 - ▶ Discussion of the clinical implications of testing results to potentially affected family members and their available options for pursuing risk assessment, testing, and management.
 - ▶ Cost of genetic testing.
 - ▶ Current legislation regarding genetic discrimination and the privacy of genetic information.

Note: All recommendations are category 2A unless otherwise indicated.

Clinical Trials: NCCN believes that the best management of any patient with cancer is in a clinical trial. Participation in clinical trials is especially encouraged.



PRINCIPLES OF GENETIC RISK ASSESSMENT AND COUNSELING HEREDITARY ENDOCRINE NEOPLASIAS

2) Considerations When Determining the Most Appropriate Testing Strategy:

- The introduction of multigene testing for hereditary cancer/tumor predisposition syndromes has rapidly altered the clinical approach to genetic testing of at-risk patients and their families.
- Given the possible overlap in clinical presentation amongst hereditary endocrine neoplasias, multigene panel testing may be more efficient and cost-effective in many situations.
- As commercially available tests differ in the specific genes analyzed, variant classification, and other factors (eg, methods of DNA/RNA analysis or option to reflex from a narrow to a larger panel; provision of financial assistance for cascade testing of relatives), it is important to consider the indication for testing and the expertise of the laboratory when choosing the specific laboratory and test panel.
- The interpretation of genetic testing remains subjective and complex. The interpretations can differ based on interlaboratory classification rules, access to unique case-level data, and other evidence. Additionally, variants may need to be reconsidered and reclassified as additional data emerge in the field.
- Genetic testing performed to identify somatic mutations arising in malignant cells is often not designed to detect germline variants and may thus be inadequate for evaluation of an underlying hereditary endocrine neoplasia syndrome.
- Testing for unaffected family members when no affected member is available should be considered. Significant limitations of interpreting test results should be discussed.

3) Post-Test Counseling Includes the Following Elements:

- Discussion of results and implications for patient and/or family members
- Interpretation of results in context of personal and family history
- Likely pathogenic variants are usually clinically managed similarly to pathogenic variants, while patients with variants of unknown significance (VUS) and likely benign variants should be managed based on the cancers/tumors in the family
- For patients with positive results:
 - ▶ Discussion of recommended medical management
 - ▶ Discussion of the importance of notifying family members and offering materials/resources for information and testing at-risk family members
 - ▶ For many hereditary endocrine neoplasia syndromes, testing of children is indicated since screening interventions often start in childhood or adolescence
 - ▶ Discussion of available resources such as high-risk clinics, disease-specific support groups, and research studies
 - ▶ For patients of reproductive age, advise about options for prenatal diagnosis and assisted reproduction, including pre-implantation genetic diagnosis
 - ▶ Consider carrier status implications of certain autosomal recessive disorders
- For patients with negative results:
 - ▶ Discussion of possible etiologies for their personal/family history including sporadic, multifactorial, or unidentified hereditary factors
 - ▶ For patients with a clinical diagnosis of an endocrine neoplasia condition (such as MEN1) and negative genetic testing, consider following the related surveillance recommendations for patient and first-degree family members

Note: All recommendations are category 2A unless otherwise indicated.

Clinical Trials: NCCN believes that the best management of any patient with cancer is in a clinical trial. Participation in clinical trials is especially encouraged.



PRINCIPLES OF GENETIC RISK ASSESSMENT AND COUNSELING HEREDITARY ENDOCRINE NEOPLASIAS

4) Criteria for Genetic Risk Evaluation for Hereditary Endocrine Neoplasia Syndromes

- Recommend evaluation in a patient with any of the following:^a
 - ▶ Adrenal cortical carcinoma (ACC)
 - ▶ Paraganglioma (PGL)/Pheochromocytoma (PCC)
 - ▶ Gastrinoma (duodenal/pancreatic or type 2 gastric NET)
 - ▶ Multifocal pancreatic neuroendocrine tumors.
 - ▶ Parathyroid adenoma or primary hyperparathyroidism before age 30, multiple parathyroid adenomas, multigland hyperplasia (without obvious secondary causes), or recurrent primary hyperparathyroidism
 - ▶ Clinical suspicion for MEN2 due to the presence of medullary thyroid cancer or other combination of MEN2-related features. [See Overview of Hereditary Endocrine Neoplasia Syndromes \(NE-E 4 of 7\).](#)
 - ▶ A mutation identified on tumor genomic testing that has clinical implications if also identified in the germline (eg, tumor analysis shows mutation in *BRCA1/2* or mismatch repair gene).
 - ▶ Close blood relative with a known pathogenic variant/likely pathogenic variant in a cancer susceptibility gene.
 - ▶ A first-degree relative meeting one of the above criteria but not available for testing.
- Recommend evaluation in a patient with clinical suspicion for MEN1 due to 2 or more of the following, or 1 AND a family history of 1 or more of the following:
 - ◊ Primary hyperparathyroidism
 - ◊ Duodenal/pancreatic neuroendocrine tumor
 - ◊ Pituitary adenoma
 - ◊ Foregut carcinoid (bronchial, thymic, or gastric)
- Consider evaluation in a patient with duodenal/pancreatic neuroendocrine tumor at any age.^b

^a Genetic testing may be a consideration for patients with other combinations of tumors or cancers in the patient and/or their family members.

^b Studies of unselected patients with pancreatic neuroendocrine tumors have identified germline variants in 16-17% of cases. However, these studies involved relatively small cohorts of patients. (Raj N, et al. JCO Precis Oncol. 2018;2018:PO.17.00267; Scarpa A, et al. Nature. 2017 Mar 2;543(7643):65-71).

Note: All recommendations are category 2A unless otherwise indicated.

Clinical Trials: NCCN believes that the best management of any patient with cancer is in a clinical trial. Participation in clinical trials is especially encouraged.



NCCN Guidelines Version 4.2021

Neuroendocrine and Adrenal Tumors

PRINCIPLES OF GENETIC RISK ASSESSMENT AND COUNSELING HEREDITARY ENDOCRINE NEOPLASIAS

Overview of Hereditary Endocrine Neoplasia Syndromes

Syndrome (Gene) ^c	Endocrine Neoplasia Manifestations	Other Manifestations	Surveillance
Hereditary paraganglioma/pheochromocytoma syndrome (MAX, SDHA, SDHAF2, SDHB, SDHC, SDHD, or TMEM127)	Paraganglioma ^c Pheochromocytoma ^c	GIST (SDHx) Renal cell cancer (SDHx)	See NE-E (7 of 7) NCCN Guidelines for Kidney Cancer (HRCC-B)
Multiple endocrine neoplasia type 1 (MEN1)^{d,e}	Parathyroid adenoma/hyperplasia (>95%) Pancreatic (functioning) or duodenal neuroendocrine tumors (20%–80%) ▶ Gastrinoma 20%–61% ▶ Insulinoma 7%–31% ▶ Glucagonoma 1%–5% ▶ VIPoma/somatostatinoma <2% Pituitary adenomas (30%–40%) Gastric carcinoids (7%–35%) Bronchial/thymic carcinoids (<8%) Adrenal adenomas (27%–36%)	Angiofibromas Collagenomas Lipomas Meningiomas	See MEN1-2^e and MEN1-A^e
Multiple endocrine neoplasia type 2 (RET)^f	Medullary thyroid cancer (≤98%) Pheochromocytoma (≤50%) Parathyroid adenoma/hyperplasia (≤25%) MEN2A, rare in MEN2B)	MEN2A: • Cutaneous lichens amyloidosis • Hirschsprung disease MEN2B: • Intestinal ganglioneuromas • Mucosal neuromas • Marfanoid habitus	See MEN2-1 and NE-E (7 of 7)^g NCCN Guidelines for Thyroid Cancer (MEDU-4 and MEDU-5)

Note: This resource is not intended to be an exhaustive list of hereditary endocrine neoplasias. Specific scenarios may warrant consideration of less common conditions such as Carney complex, Carney triad, Currarino syndrome, or polycythemia-paraganglioma-somatostatinoma syndrome.

^c Penetrance estimates and tumor locations vary significantly by gene. For patients with pathogenic variants in the SDHD, SDHAF2, and possibly MAX genes, tumor risks are mostly a concern when the variant is paternally inherited.

^d 10% of cases have de novo MEN1 mutations.

^e Thakker RV, Newey PJ, Walls GV, et al. Clinical practice guidelines for multiple endocrine neoplasia type 1 (MEN1). J Clin Endocrinol Metab 2012;97:2990-3011.

^f 50% of cases have de novo RET mutations; therefore, even if a family history is not suggestive of a hereditary syndrome, genetic testing for RET mutations should still be performed on the affected individual.

^g Wells SA Jr, Asa SL, Dralle H, et al. Revised American Thyroid Association guidelines for the management of medullary thyroid carcinoma. Thyroid. 2015;25(6):567-610.

Note: All recommendations are category 2A unless otherwise indicated.

Clinical Trials: NCCN believes that the best management of any patient with cancer is in a clinical trial. Participation in clinical trials is especially encouraged.



NCCN Guidelines Version 4.2021

Neuroendocrine and Adrenal Tumors

PRINCIPLES OF GENETIC RISK ASSESSMENT AND COUNSELING HEREDITARY ENDOCRINE NEOPLASIAS

Overview of Hereditary Endocrine Neoplasia Syndromes

Syndrome (Gene)	Endocrine Neoplasia Manifestations	Other Manifestations	Surveillance
Multiple endocrine neoplasia type 4 (CDKN1B)^g	Parathyroid adenoma/hyperplasia Pituitary adenomas Pancreatic or duodenal neuroendocrine tumors Papillary thyroid cancer	Meningiomas	Not available ^e
Neurofibromatosis type 1 (NF1)	Pheochromocytoma (3%) Pancreatic neuroendocrine tumors (rare)	Neurofibromas Skin lesions (CAL and freckling) Lisch nodules Gliomas GIST	NCCN Guidelines for Genetic/Familial High-Risk Assessment: Breast, Ovarian, and Pancreatic AAP Health Supervision Guidelines ^h
Tuberous sclerosis complex (TSC1 and TSC2)	Pituitary adenomas (rare) Parathyroid adenoma/hyperplasia (rare) Pancreatic neuroendocrine tumors (rare)	Skin lesions CNS tumors/cancers Renal angiomyolipomas Clear cell renal cancer Cardiac rhabdomyomas Lymphangioleiomyomatosis	NCCN Guidelines for Kidney Cancer (HRCC-B)
von Hippel-Lindau syndrome (VHL)	Pheochromocytoma (10%–20%) Paraganglioma (10%–20%) Pancreatic neuroendocrine tumors (5%–17%)	Hemangioblastomas (retinal or CNS) Clear cell renal cancer Endolymphatic sac tumors Cystadenomas	See NE-E (7 of 7) and PanNET-6 VHLA Handbook ⁱ NCCN Guidelines for Kidney Cancer (HRCC-B)

Note: This resource is not intended to be an exhaustive list of hereditary endocrine neoplasias. Specific scenarios may warrant consideration of less common conditions such as Carney complex, Carney triad, Currarino syndrome, or polycythemia-paraganglioma-somatostatinoma syndrome.

^e Thakker RV, Newey PJ, Walls GV, et al. Clinical practice guidelines for multiple endocrine neoplasia type 1 (MEN1). J Clin Endocrinol Metab 2012;97:2990-3011.

^g MEN4 is a newly described endocrine neoplasia. Therefore, penetrance estimates and surveillance guidelines are not available. Given the clinical overlap with MEN1, consideration can be given to following MEN1-related surveillance recommendations in patients with MEN4.

^h Miller, D. T., et al. (2019). Health Supervision for Children With Neurofibromatosis Type 1. Pediatrics 143(5): e20190660.

ⁱ The VHL Alliance. The VHL Handbook: What you need to know about VHL. 6th ed. 2020.

Note: All recommendations are category 2A unless otherwise indicated.

Clinical Trials: NCCN believes that the best management of any patient with cancer is in a clinical trial. Participation in clinical trials is especially encouraged.



PRINCIPLES OF GENETIC RISK ASSESSMENT AND COUNSELING HEREDITARY ENDOCRINE NEOPLASIAS

Hereditary Cancer Predisposition Syndromes Associated with ACC

Syndrome (Gene)	Other Cancer/Tumor Associations	Surveillance Recommendations
Li-Fraumeni syndrome (<i>TP53</i>)	Sarcoma, brain cancer, breast cancer, leukemia	NCCN Guidelines for Genetic/Familial High-Risk Assessment: Breast, Ovarian, and Pancreatic
Lynch syndrome (<i>MLH1</i>, <i>EPCAM</i>/<i>MSH2</i>, <i>MSH6</i>, <i>PMS2</i>)	Colon, endometrial, gastric, ovarian, and other cancers	NCCN Guidelines for Genetic/Familial High-Risk Assessment: Breast, Ovarian, and Pancreatic NCCN Guidelines for Genetic/Familial High-Risk Assessment: Colorectal
Multiple endocrine neoplasia type 1 (<i>MEN1</i>)	Parathyroid adenoma/hyperplasia, duodenal/pancreatic neuroendocrine tumors, pituitary adenomas, bronchial/thymic carcinoids	See MEN1-2 and MEN1-A
Familial adenomatous polyposis (<i>APC</i>)	Colon polyposis/cancer, duodenal/periampullary polyposis/cancer, thyroid cancer	NCCN Guidelines for Genetic/Familial High-Risk Assessment: Colorectal

Note: All recommendations are category 2A unless otherwise indicated.

Clinical Trials: NCCN believes that the best management of any patient with cancer is in a clinical trial. Participation in clinical trials is especially encouraged.

**PRINCIPLES OF GENETIC RISK ASSESSMENT AND COUNSELING**
HEREDITARY ENDOCRINE NEOPLASIAS**PCC/PGL-specific Screening Recommendations for Patients with Confirmed Hereditary Syndromes^{h-k}****Hereditary paraganglioma/pheochromocytoma (PGL/PCC) syndrome^l**

- **Surveillance starting at 6–8 years of age:**
 - **Blood pressure monitoring at all medical visits.**
 - **Annual measurement of plasma free metanephrines or 24-hour urine for fractionated metanephrines.**
 - **Cross-sectional imaging of skull base to pelvis every 2 years. Whole body MRI (if available) or other non-radiation-containing imaging procedures. If whole body MRI not available, may consider abdominal MRI, skull base and neck MRI, and chest CT.^m**

Multiple endocrine neoplasia type 2ⁿ

- **Surveillance starting by age 11 years for children in the American Thyroid Association high risk (ATA-H) and highest risk (ATA-HST) categories and by age 16 years in children in the ATA-moderate risk (ATA-MOD) category:**
 - **Annual measurement of plasma free metanephrines or 24-hour urine for fractionated metanephrines.**
 - **Adrenal imaging with CT or MRI is indicated in patients with positive biochemical results.**

von Hippel-Lindau syndrome (*VHL*)

- **Blood pressure monitoring at all medical visits starting at age 2 years.**
- **Annual measurement of plasma-free metanephrines (preferred) or 24-hour urine for fractionated metanephrines starting at age 5 years.**
- **Abdominal MRI (preferred) or CT with and without IV contrast every 2 years starting at age 15 years.**

Surgical Recommendations for Patients with Confirmed Hereditary Syndromes

- **Preoperative alert: Patients with a suspected or known diagnosis of a hereditary PGL/PCC syndrome should have blood and/or urine screening for tumors prior to any surgical procedures.**
- **Patients with hereditary PGL/PCC, multiple endocrine neoplasia type 2, and *VHL* have an appreciable risk for bilateral tumors. Consideration should be given to cortical-sparing adrenalectomy.**

^h Rednam SP, Erez A, Druker H, et al. Von Hippel Lindau and Hereditary Pheochromocytoma/Paraganglioma Syndroms: Clinical Features, Genetics, and Surveillance Recommendations in Childhood. Clin Cancer Res. 2017;23(12):e68-e75. doi:10.1158/1078-0432.CCR-17-0547.

ⁱ Muth A, Crona J, Gimm O, et al. Genetic testing and surveillance guidelines in hereditary pheochromocytoma and paraganglioma. J Intern Med. 2019;285(2):187-204. doi:10.1111/joim.12869.

^j Tufton N, Sahdev A, Akker SA. Radiological Surveillance Screening in Asymptomatic Succinate Dehydrogenase Mutation Carriers. J Endocr Soc. 2017;1(7):897-907. Published 2017 Jun 6. doi:10.1210/js.2017-00230.

^k Neumann HPH, Young WF Jr, Eng C. Pheochromocytoma and Paraganglioma. N Engl J Med. 2019;381(6):552-565. doi:10.1056/NEJMra1806651

^l SDHD, SDHAF2, and MAX patients are most at risk if the pathogenic variant was paternally inherited. Recommend following the above recommendations if the parent of origin is unknown. Consider screening for patients with maternally inherited variants as case reports of tumor occurrence exist.

^m Available data suggests SDHAF2 patients are primarily at risk for head and neck tumors and MAX patients are primarily at risk for adrenal tumors. Therefore, consideration can be given to more targeted imaging in these cohorts.

ⁿ Wells SA Jr, Asa SL, Dralle H, et al. Revised American Thyroid Association guidelines for the management of medullary thyroid carcinoma. Thyroid 2015;25:567-610.

Note: All recommendations are category 2A unless otherwise indicated.

Clinical Trials: NCCN believes that the best management of any patient with cancer is in a clinical trial. Participation in clinical trials is especially encouraged.



NCCN Guidelines Version 4.2021

Neuroendocrine and Adrenal Tumors

PRINCIPLES OF SYSTEMIC ANTI-TUMOR THERAPY

Locoregionally Advanced and/or Metastatic Neuroendocrine Tumors of the Gastrointestinal Tract (Well-Differentiated Grade 1/2), Lung, and Thymus

- Systemic therapy may not be appropriate for every patient with locoregionally advanced or metastatic disease. Consider multidisciplinary discussion to determine the best choice of treatment, including: observation for patients with stable disease with mild tumor burden, hepatic regional therapy for patients with liver-predominant metastases, cytoreductive surgery, or systemic therapy, which may be appropriate considerations.
- Currently, there are no data to support a specific sequence of regional versus systemic therapy, and no data to guide sequencing of the following systemic therapy options.
- There is no known role for systemic treatment in the adjuvant setting for NETs.
- Doses and schedules are subject to appropriate modifications depending on the circumstances.
- For management of hormone-related symptoms for GI tumors, see [NET-11](#). For management of carcinoid syndrome, see [NET-12](#).

Neuroendocrine Tumors of the Gastrointestinal Tract (Well-Differentiated Grade 1/2)^{a,b,c}

	Preferred Regimens	Other Recommended Regimens	Useful in Certain Circumstances
Locoregional Advanced Disease and/or Distant Metastases (if progression on octreotide or lanreotide) ^c	<ul style="list-style-type: none"> • Everolimus^{d,1,2} • PRRT with 177Lu-dotatate (if SSR-positive imaging and progression on octreotide/lanreotide) (category 1 for progressive mid-gut tumors)^e 	<ul style="list-style-type: none"> • None 	<ul style="list-style-type: none"> • Consider (listed in alphabetical order): <ul style="list-style-type: none"> ▶ Cytotoxic chemotherapy, if no other options feasible (all category 3): Anticancer agents such as 5-fluorouracil (5-FU), capecitabine, dacarbazine, oxaliplatin, streptozocin, and temozolomide can be used in patients with progressive metastases for whom there are no other treatment options. (See Discussion for details.)

^aFor symptom control, octreotide 150–250 mcg SC TID or octreotide LAR 20–30 mg IM or lanreotide 120 mg SC every 4 weeks. Dose and frequency may be further increased for symptom control as needed. Therapeutic levels of octreotide would not be expected to be reached for 10–14 days after LAR injection. Short-acting octreotide can be added to octreotide LAR for rapid relief of symptoms or for breakthrough symptoms.

^bThe PROMID trial showed an antitumor effect of octreotide in advanced neuroendocrine tumors of the midgut.³ The CLARINET trial showed an antitumor effect of lanreotide in advanced, well-differentiated metastatic grade 1 and grade 2 GEP NETs.⁴

^cIf disease progression, treatment with octreotide or lanreotide should be continued in patients with functional tumors and may be used in combination with any of the systemic therapy options. For details on the administration of octreotide or lanreotide with 177Lu-dotatate, see [NE-G](#).

^dSafety and effectiveness of everolimus in the treatment of patients with carcinoid syndrome have not been established.

^eSee [Principles of PRRT with 177Lu-dotatate \(NE-G\)](#).

Note: All recommendations are category 2A unless otherwise indicated.

Clinical Trials: NCCN believes that the best management of any patient with cancer is in a clinical trial. Participation in clinical trials is especially encouraged.

References



NCCN Guidelines Version 4.2021

Neuroendocrine and Adrenal Tumors

PRINCIPLES OF SYSTEMIC ANTI-TUMOR THERAPY

Locoregionally Advanced and/or Metastatic Neuroendocrine Tumors of the Gastrointestinal Tract (Well-Differentiated Grade 1/2), Lung, and Thymus

- Systemic therapy may not be appropriate for every patient with locoregionally advanced or metastatic disease. Consider multidisciplinary discussion to determine the best choice of treatment, including: observation for patients with stable disease with mild tumor burden, hepatic regional therapy for patients with liver-predominant metastases, cytoreductive surgery, or systemic therapy, which may be appropriate considerations.
- Currently, there are no data to support a specific sequence of regional versus systemic therapy and no data to guide sequencing of the following systemic therapy options.
- There is no known role for systemic treatment in the adjuvant setting for NETs.
- Doses and schedules are subject to appropriate modifications depending on the circumstances.
- For management of hormone-related symptoms for GI tumors, see [NET-11](#). For management of carcinoid syndrome, see [NET-12](#).

Bronchopulmonary/Thymus Neuroendocrine Tumors

	Preferred Regimens	Other Recommended Regimens	Useful in Certain Circumstances
Distant Metastases (clinically significant tumor burden and low grade/progression/intermediate grade [atypical] or symptomatic) ^{f,c}	<ul style="list-style-type: none"> • Clinical trial • Everolimus^{d,1,2} (category 1 for bronchopulmonary NET) • Octreotide LAR³ or lanreotide⁴ (if SSR-positive and/or hormonal symptoms) 	<ul style="list-style-type: none"> • None 	<ul style="list-style-type: none"> • PRRT with 177Lu-dotatate (if SSR-positive imaging and progression on octreotide or lanreotide)^e • Temozolomide^{5,6} ± capecitabine^{9,7-9} • Cisplatin + etoposide^{9,10,11} • Carboplatin + etoposide^{9,11,12}

^c If disease progression, treatment with octreotide or lanreotide should be continued in patients with functional tumors and may be used in combination with any of the systemic therapy options. For details on the administration of octreotide or lanreotide with 177Lu-dotatate, see [NE-G](#).

^d Safety and effectiveness of everolimus in the treatment of patients with carcinoid syndrome have not been established.

^e See [Principles of PRRT with 177Lu-dotatate \(NE-G\)](#).

^f Chemoradiation is thought to have most efficacy for tumors with atypical histology or tumors with higher mitotic and proliferative indices (eg, Ki-67). There are limited data on the efficacy of chemoradiation for unresectable IIIA or IIIB low-grade lung neuroendocrine tumors; however, some panel members consider chemoradiation in this situation.

^g Can be considered for intermediate-grade/atypical tumors with Ki-67 proliferative index and mitotic index in the higher end of the defined spectrum.

Note: All recommendations are category 2A unless otherwise indicated.

Clinical Trials: NCCN believes that the best management of any patient with cancer is in a clinical trial. Participation in clinical trials is especially encouraged.

References



PRINCIPLES OF SYSTEMIC ANTI-TUMOR THERAPY

Locoregionally Advanced and/or Metastatic Pancreatic Neuroendocrine Tumors (Well-Differentiated Grade 1/2)

- Systemic therapy may not be appropriate for every patient with locoregionally advanced or metastatic disease. Consider multidisciplinary discussion to determine the best choice of treatment, including: observation for patients with stable disease with mild tumor burden, hepatic regional therapy for patients with liver-predominant metastases, cytoreductive surgery, or systemic therapy.
- Currently, there are no data to support a specific sequence of regional versus systemic therapy and no data to guide sequencing of the following systemic therapy options.
- There is no known role for systemic treatment in the adjuvant setting for PanNETs.
- Doses and schedules are subject to appropriate modifications depending on the circumstances.
- For management of hormone-related symptoms and complications with octreotide or lanreotide, see [PanNET-1](#) through [PanNET-5](#).

Pancreatic Neuroendocrine Tumors (Well-Differentiated Grade 1/2)

	Preferred Regimens	Other Recommended Regimens	Useful in Certain Circumstances
Locoregional Advanced Disease and/or Distant Metastases	<ul style="list-style-type: none"> • Everolimus¹³ (category 1 for progressive disease) 10 mg by mouth, daily • Octreotide^{a,b} LAR or lanreotide^{a,5} (if SSR-positive imaging) • Sunitinib¹⁴ (category 1 for progressive disease) 37.5 mg by mouth, daily • Temozolomide + capecitabine¹⁵ (preferred when tumor response is needed for symptoms or debulking) • PRRT with 177Lu-dotatate (if SSR-positive imaging and progression on octreotide or lanreotide)^e 	<ul style="list-style-type: none"> • Cytotoxic chemotherapy options considered in patients with bulky, symptomatic, and/or progressive disease include: <ul style="list-style-type: none"> ◊ 5-FU + doxorubicin + streptozocin (FAS)¹⁶ ◊ Streptozocin + doxorubicin¹⁷ ◊ Streptozocin + 5-FU¹⁸ ◊ FOLFOX (leucovorin + 5-FU + oxaliplatin)¹⁹ ◊ CAPEOX (capecitabine + oxaliplatin)²⁰ 	<ul style="list-style-type: none"> • Consider belzutifan in the setting of germline <i>VHL</i> alteration in patients with progressive PanNETs^{h,21}

^a For symptom control, octreotide 150–250 mcg SC TID or octreotide LAR 20–30 mg IM or lanreotide 120 mg SC every 4 weeks. Dose and frequency may be further increased for symptom control as needed. Therapeutic levels of octreotide would not be expected to be reached for 10–14 days after LAR injection. Short-acting octreotide can be added to octreotide LAR for rapid relief of symptoms or for breakthrough symptoms.

^b The PROMID trial showed an antitumor effect of octreotide in advanced neuroendocrine tumors of the midgut.¹ The CLARINET trial showed an antitumor effect of lanreotide in advanced, well-differentiated metastatic grade 1 and grade 2 GEP NETs.²

^e See [Principles of PRRT with 177Lu-dotatate \(NE-G\)](#).

^h The study excluded patients with prior systemic anticancer therapy, including anti-vascular endothelial growth factor therapy, patients needing immediate surgical intervention for tumor treatment, or patients with evidence of metastatic disease on screening imaging.

Note: All recommendations are category 2A unless otherwise indicated.

Clinical Trials: NCCN believes that the best management of any patient with cancer is in a clinical trial. Participation in clinical trials is especially encouraged.

References



PRINCIPLES OF SYSTEMIC ANTI-TUMOR THERAPY

Poorly Differentiated Neuroendocrine Carcinoma/Large or Small Cell (Extrapulmonary)

Poorly Differentiated Neuroendocrine Carcinoma/Large or Small Cell (Extrapulmonary)

Resectable disease:

- Cisplatin + etoposide¹⁰
- Carboplatin + etoposide²²
- FOLFOX
- FOLFIRI
- Temozolomide ± capecitabine

Locoregional Unresectable/Metastatic Disease:

- Cisplatin + etoposide¹⁰
- Carboplatin + etoposide²²
- Cisplatin + irinotecan
- Carboplatin + irinotecan
- FOLFOX
- FOLFIRI
- FOLFIRINOX^{23,24}
- Temozolomide ± capecitabine
- Nivolumab + ipilimumab (category 2B) (only for metastatic disease with progression)²⁵
- Pembrolizumabⁱ

Chemoradiation (concurrent/sequential) for locoregional unresectable disease

- Cisplatin + etoposide
- Carboplatin + etoposide

ⁱ Pembrolizumab can be considered for patients with mismatch repair-deficient (dMMR), microsatellite instability-high (MSI-H), or advanced tumor mutational burden-high (TMB-H) tumors (as determined by an FDA-approved test) that have progressed following prior treatment and have no satisfactory alternative treatment options.

Note: All recommendations are category 2A unless otherwise indicated.

Clinical Trials: NCCN believes that the best management of any patient with cancer is in a clinical trial. Participation in clinical trials is especially encouraged.

[References](#)

**PRINCIPLES OF SYSTEMIC ANTI-TUMOR THERAPY**
REFERENCES

- ¹ Pavel ME, Baudin E, Oberg KE, et al. Efficacy of everolimus plus octreotide LAR in patients with advanced neuroendocrine tumor and carcinoid syndrome: final overall survival from the randomized, placebo-controlled phase 3 RADIANT-2 study. *Ann Oncol* 2017;28:1569-1575.
- ² Pavel ME, Singh S, Strosberg JR, et al. Health-related quality of life for everolimus versus placebo in patients with advanced, non-functional, well-differentiated gastrointestinal or lung neuroendocrine tumours (RADIANT-4): a multicentre, randomised, double-blind, placebo-controlled, phase 3 trial. *Lancet Oncol* 2017;18:1411-1422.
- ³ Rinke A, Muller HH, Schade-Brittinger C, et al. Placebo-controlled, double-blind, prospective, randomized study on the effect of octreotide LAR in the control of tumor growth in patients with metastatic neuroendocrine midgut tumors: a report from the PROMID Study Group. *J Clin Oncol* 2009;27:4656-4663.
- ⁴ Caplin ME, Pavel M, Cwikla JB, et al. Lanreotide in metastatic enteropancreatic neuroendocrine tumors. *N Engl J Med* 2014;371:224-233.
- ⁵ Crona J, Fanola I, Lindholm DP, et al. Effect of temozolomide in patients with metastatic bronchial carcinoids. *Neuroendocrinology*. 2013;98:151-155.
- ⁶ Ekeblad S, Sundin A, Janson ET, et al. Temozolomide as monotherapy is effective in treatment of advanced malignant neuroendocrine tumors. *Clin Cancer Res* 2007;13:2986-2991.
- ⁷ Al-Toubah T, Morse B, Strosberg J. Capecitabine and temozolomide in advanced lung neuroendocrine neoplasms. *Oncologist* 2020;25:e48-e52.
- ⁸ Papaxoinis G, Kordatou Z, McCallum L, et al. Capecitabine and temozolomide in patients with advanced pulmonary carcinoid tumours. *Neuroendocrinology* 2020;110:413-421.
- ⁹ Fine RL, Gulati AP, Krantz BA, et al. Capecitabine and temozolomide (CAPTEM) for metastatic well differentiated neuroendocrine cancers: The Pancreas Center at Columbia University experience. *Cancer Chemother Pharmacol* 2013;71:663-670.
- ¹⁰ Iwasa S, Morizane C, Okusaka T, et al. Cisplatin and etoposide as first-line chemotherapy for poorly differentiated neuroendocrine carcinoma of the hepatobiliary tract and pancreas. *Jpn J Clin Oncol* 2010;40:313-318.
- ¹¹ Chong CR, Wirth LJ, Nishino M, et al. Chemotherapy for locally advanced and metastatic pulmonary carcinoid tumors. *Lung Cancer* 2014;86:241-246.
- ¹² Rossi A, Di Maio M, Chiodini P, et al. Carboplatin- or cisplatin-based chemotherapy in first-line treatment of small-cell lung cancer: the COCIS meta-analysis of individual patient data. *J Clin Oncol* 2012;30:1692-1698.
- ¹³ Yao JC, Shah MH, Ito T, et al. Everolimus for advanced pancreatic neuroendocrine tumors. *N Engl J Med* 2011;364:514-523.
- ¹⁴ Raymond E, Dahan L, Raoul JL, et al. Sunitinib malate for the treatment of pancreatic neuroendocrine tumors. *N Engl J Med* 2011;364:501-13.
- ¹⁵ Strosberg JR, Fine RL, Choi J, et al. First-line chemotherapy with capecitabine and temozolomide in patients with metastatic pancreatic endocrine carcinomas. *Cancer* 2011;117:268-275.
- ¹⁶ Kouvaraki MA, Ajani JA, Hoff P, et al. Fluorouracil, doxorubicin, and streptozocin in the treatment of patients with locally advanced and metastatic pancreatic endocrine carcinomas. *J Clin Oncol* 2004;22:4762-4771.
- ¹⁷ Moertel CG, Lefkopoulo M, Lipsitz S, Hahn RG, Klaassen D. Streptozocin-doxorubicin, streptozocin-fluorouracil or chlorozotocin in the treatment of advanced islet-cell carcinoma. *N Engl J Med* 1992;326:519-523.
- ¹⁸ Sun W, Lipsitz S, Catalano P, Mailliard JA, Haller DG. Phase II/III study of doxorubicin with fluorouracil compared with streptozocin with fluorouracil or dacarbazine in the treatment of advanced carcinoid tumors: Eastern Cooperative Oncology Group Study E1281. *J Clin Oncol* 2005;23:4897-4904.
- ¹⁹ Kunz PL, Balise RR, Fehrenbacher L, et al. Oxaliplatin-fluoropyrimidine chemotherapy plus bevacizumab in advanced neuroendocrine tumors: an analysis of 2 phase II trials. *Pancreas*. 2016;45:1394-1400.
- ²⁰ Spada F, Antonuzzo L, Marconcini R, et al. Oxaliplatin-based chemotherapy in advanced neuroendocrine tumors: clinical outcomes and preliminary correlation with biological factors. *Neuroendocrinology*. 2016;103:806-814.
- ²¹ Jonasch E, Donskov F, Iliopoulos O, et al. Belzutifan for renal cell carcinoma in von Hippel-Lindau disease. *N Engl J Med* 2021;385:2036-2046.
- ²² Frizziero M, Spada F, Lamarca A, et al. Carboplatin in combination with oral or intravenous etoposide for extra-pulmonary, poorly-differentiated neuroendocrine carcinomas. *Neuroendocrinology* 2019;109:100-112.
- ²³ Zhu J, Strosberg JR, Dropkin E, Strickler JH. Treatment of high-grade metastatic pancreatic neuroendocrine carcinoma with FOLFIRINOX. *J Gastrointest Cancer* 2015;46:166-169.

Note: All recommendations are category 2A unless otherwise indicated.**Clinical Trials:** NCCN believes that the best management of any patient with cancer is in a clinical trial. Participation in clinical trials is especially encouraged.[Continued](#)



PRINCIPLES OF SYSTEMIC ANTI-TUMOR THERAPY REFERENCES

- ²⁴ Borghesani M, Reni A, Zaninotto E, et al. Outcomes of upfront treatment with mFOLFIRINOX regimen in G3 GEP-NENs: A monocentric retrospective experience. Paper presented at: 18th Annual ENETS Conference for the Diagnosis and Treatment of Neuroendocrine Tumor Disease; February 25-27, 2021; Virtual Conference.
- ²⁵ Klein O, Kee D, Markman B, et al. Immunotherapy of ipilimumab and nivolumab in patients with advanced neuroendocrine tumors: A subgroup analysis of the CA209-538 Clinical Trial for Rare Cancers. Clin Cancer Res 2020;26:4454-4459.

Note: All recommendations are category 2A unless otherwise indicated.

Clinical Trials: NCCN believes that the best management of any patient with cancer is in a clinical trial. Participation in clinical trials is especially encouraged.



PRINCIPLES OF PEPTIDE RECEPTOR RADIONUCLIDE THERAPY (PRRT) WITH 177LU-DOTATATE¹⁻¹⁰

- Lutetium 177Lu-dotatate is a radiolabeled SSA used as PRRT.
- It is approved by the FDA for the treatment of SSR-positive gastroenteropancreatic (GEP) NETs, including foregut, midgut, and hindgut NET in adults.^{1,2}
- Currently there are no randomized data, but there are reports of treatment efficacy and favorable outcomes when PRRT is used for PanNETs, pheochromocytomas, paragangliomas, and bronchopulmonary/thymic NETs.³⁻¹⁰ If feasible, participation in clinical trials of PRRT is strongly recommended for patients with such rare groups of NET.

Key Eligibility:

- Well-differentiated NET
- SSR expression of NET as detected by SSR-PET/CT or SSR-PET/MR.^{a,b,c}
- Adequate bone marrow, renal and hepatic function

Preparing Eligible Patients for 177Lu-dotatate

- Do not administer long-acting SSAs (such as lanreotide, octreotide) for 4–6 weeks prior to each 177Lu-dotatate treatment. Administer short-acting octreotide as needed for symptom control of carcinoid syndrome; discontinue at least 24 hours prior to initiating 177Lu-dotatate.
- Counsel patients about the risks of:
 - Radiation exposure to themselves and others
 - Myelosuppression
 - Secondary myelodysplastic syndrome (MDS) and leukemia
 - Renal toxicity
 - Hepatic toxicity
 - Embryo-fetal toxicity
 - Infertility
 - Neuroendocrine hormonal crisis or carcinoid crisis: flushing, diarrhea, hypotension, bronchoconstriction or other signs and symptoms
 - Nausea/vomiting (related to amino acid infusion required as part of therapy)
- Discuss radiation safety precautions during and after 177Lu-dotatate.
- Verify pregnancy status in females of reproductive potential.
- Advise on use of effective contraception for up to 7 months (females) and 4 months (males) after last dose of 177Lu-dotatate.

Dose and Administration

- 177Lu-dotatate is administered intravenously (IV) via peripheral IV at a dose of 200 mCi over 30–40 minutes every 8 weeks for a total of 4 treatments.
- Amino acid solution:

^a See [Principles of Imaging \(NE-B\)](#).

^b PET/CT or PET/MRI of skull base to mid-thigh with IV contrast when possible. Data are limited on the optimal timing of scans following administration of SSAs.

^c SSR PET tracers include: 68Ga-DOTATATE, 64Cu-DOTATATE, 68Ga-DOTATOC.

Note: All recommendations are category 2A unless otherwise indicated.

Clinical Trials: NCCN believes that the best management of any patient with cancer is in a clinical trial. Participation in clinical trials is especially encouraged.

[Continued](#)

**PRINCIPLES OF PEPTIDE RECEPTOR RADIONUCLIDE THERAPY (PRRT) WITH 177LU-DOTATATE¹⁻¹⁰**

- ▶ IV infusion of amino acids is a critical part of 177Lu-dotatate therapy for nephroprotection.
- ▶ Amino acids are administered 30 minutes before, concurrently with, and 3 hours after 177Lu-dotatate.
- ▶ Commercial amino acid formulations infused at high rates are more emetogenic than compounded amino acids.
- ▶ Solutions containing only arginine/lysine are only available through compounding pharmacies, but are much less emetogenic than commercial amino acid solutions. Options for amino acids are as follows:
 - ◊ Arginine 2.5%/lysine 2.5% in 1000 mL NaCl infused at 250 mL/h for 4 hours.
 - ◊ Commercial amino acid formulation (typically containing approximately 20 amino acids) mixed in sterile water for a total volume of approximately 2000 mL. Infusion rate can be increased to roughly 300–500 mL/h, as tolerated. Recommend starting at low rate of 50 mL/h and increasing by 10 mL/h every 10 minutes as tolerated based on symptoms such as nausea. 177Lu-dotatate infusion should begin after at least 250 mL of amino acids have been infused.
- Aggressive antiemetic prophylaxis is recommended with a 5-HT₃ receptor antagonist with or without an NK1 receptor blocker. [See NCCN Guidelines for Antiemesis.](#)

Post-treatment Instructions

- Detailed instructions on post-treatment radiation-risk reduction strategies should be provided per institutional radiation safety guidelines.
- Complete blood count (CBC), serum chemistry including renal and hepatic functions should be monitored.
- SSAs (octreotide or lanreotide) can be administered 4–24 hours after each 177Lu-dotatate treatment.

Timing of SSAs (Octreotide or Lanreotide) in Relation to 177Lu-dotatate

- Most patients treated with PRRT will have progressed on a first-line SSA.
- Generally, patients with hormonally functional tumors should continue octreotide or lanreotide along with 177Lu-dotatate. It is unclear whether patients with nonfunctional tumors benefit from continuation of SSA treatment during and after 177Lu-dotatate treatment.
- There are theoretical concerns regarding the competition between SSAs and 177Lu-dotatate for SSR binding. Therefore, the following is recommended:
 - ▶ Do not administer long-acting SSAs for 4–6 weeks prior to each 177Lu-dotatate treatment.
 - ▶ Stop short-acting SSAs 24 hours before each 177Lu-dotatate treatment.
 - ▶ SSAs (short- and long-acting) can be resumed 4–24 hours after each 177Lu-dotatate treatment.

Note: All recommendations are category 2A unless otherwise indicated.

Clinical Trials: NCCN believes that the best management of any patient with cancer is in a clinical trial. Participation in clinical trials is especially encouraged.

References



PRINCIPLES OF PEPTIDE RECEPTOR RADIONUCLIDE THERAPY (PRRT) WITH ¹⁷⁷LU-DOTATATE

REFERENCES

- ¹ National Institutes of Health. Lutetium ¹⁷⁷Lu dotatate package insert. Available at: <https://dailymed.nlm.nih.gov/dailymed/drugInfo.cfm?setid=72d1a024-00b7-418a-b36e-b2cb48f2ab55>. Accessed April 13, 2021.
- ² Strosberg J, El-Haddad G, Wolin E, et al. Phase 3 trial of ¹⁷⁷Lu-dotatate for midgut neuroendocrine tumors. *N Engl J Med* 2017;376:125-135.
- ³ Brabander T, van der Zwan WA, Teunissen JJM, et al. Long-term efficacy, survival, and safety of [¹⁷⁷Lu-DOTA⁰,Tyr³] octreotate in patients with gastroenteropancreatic and bronchial neuroendocrine tumors. *Clin Cancer Res* 2017;23:4617-4624.
- ⁴ Baum RP, Kulkarni HR, Singh A, et al. Results and adverse events of personalized peptide receptor radionuclide therapy with ⁹⁰Yttrium and ¹⁷⁷Lutetium in 1048 patients with neuroendocrine neoplasms. *Oncotarget* 2018;9:16932-16950.
- ⁵ Sharma N, Naraev BG, Engelman EG, et al. Peptide receptor radionuclide therapy outcomes in a North American cohort with metastatic well-differentiated neuroendocrine tumors. *Pancreas* 2017;46:151-156.
- ⁶ Katona BW, Rocco GA, Soulen MC, et al. Efficacy of peptide receptor radionuclide therapy in a United States-based cohort of metastatic neuroendocrine tumor patients: Single-institution retrospective analysis. *Pancreas* 2017;46:1121-1126.
- ⁷ Kong G, Grozinsky-Glasberg S, Hofman MS, et al. Efficacy of peptide receptor radionuclide therapy for functional metastatic paraganglioma and pheochromocytoma. *J Clin Endocrinol Metab* 2017;102:3278-3287.
- ⁸ Vyakaranam AR, Crona J, Norlén O, et al. Favorable outcome in patients with pheochromocytoma and paraganglioma treated with ¹⁷⁷Lu-DOTATATE. *Cancers (Basel)* 2019;11:909.
- ⁹ Jaiswal SK, Sarathi V, Menon SS, et al. ¹⁷⁷Lu-DOTATATE therapy in metastatic/inoperable pheochromocytoma-paraganglioma. *Endocr Connect* 2020;9:864-873.
- ¹⁰ Mirvis E, Toumpanakis C, Mandair D, et al. Efficacy and tolerability of peptide receptor radionuclide therapy (PRRT) in advanced metastatic bronchial neuroendocrine tumours (NETs). *Lung Cancer* 2020;150:70-75.

Note: All recommendations are category 2A unless otherwise indicated.

Clinical Trials: NCCN believes that the best management of any patient with cancer is in a clinical trial. Participation in clinical trials is especially encouraged.

**PRINCIPLES OF LIVER-DIRECTED THERAPY FOR NEUROENDOCRINE TUMOR METASTASES**

Liver-directed therapy consists of three categories of treatment:

Surgical resection (which may include intraoperative thermal ablation of lesions); see [Surgical Principles For Management of Neuroendocrine Tumors \(NE-D\)](#)

Hepatic arterial embolization, including bland transarterial embolization [TAE], chemoembolization [TACE], and radioembolization [TARE]

Percutaneous thermal ablation

Indications for Hepatic Arterial Embolization

- Embolization is recommended for well-differentiated NETs with liver-dominant, unresectable metastases that are:
 - Symptomatic on an SSA or following another form of systemic therapy
 - Progressive on an SSA or following another form of systemic therapy
 - Presenting with bulky liver disease; embolization may be employed as debulking therapy without waiting for progression.
- Objective radiologic response rates vary widely in retrospective studies, but average approximately 60%, with symptom palliation in approximately 85% of patients with hormonal syndromes.
- Relative contraindications include significant baseline liver dysfunction (jaundice, ascites) and a liver tumor burden >70%. Prior Whipple surgery or biliary instrumentation (sphincterotomy, stent) increases the risk of liver abscess due to biliary bacterial colonization; infectious complications occur in about 20% of cases following TAE/TACE and 8% after TARE, even with broad-spectrum antibiotic coverage.

Embolization Modalities

- TAE and TACE
 - There are no completed randomized studies comparing TAE with conventional TACE and both are acceptable.
 - Drug-eluting embolics are associated with increased hepatobiliary toxicity in the NET population, and are not recommended.
 - In patients with bilobar disease, TAE/TACE is generally performed over at least two procedures, approximately one month apart. Patients with very high liver tumor burden may require three or four embolizations to safely treat the entire liver. Short-acting octreotide should be administered pre-embolization for patients with hormonal syndromes. Overnight observation is typically appropriate to monitor and treat symptoms of post-embolization syndrome such as pain and nausea and exacerbation of hormone-related symptoms.
- TARE may be considered particularly in the following scenarios:
 - Lobar or segmental (less than lobular) disease distribution.
 - Patients with prior Whipple surgery or biliary tract instrumentation (lower risk of hepatobiliary infection than TAE/TACE).¹⁻⁴
 - TARE is better tolerated than TAE/TACE, but late radioembolization-induced chronic hepatotoxicity (RECHT) may occur in long-term survivors, and is particularly a concern among patients undergoing bilobar radioembolization.
 - To date there is no evidence for or against the safety of sequencing TARE and PRRT.^{5,6}

Ablative Therapy (category 2B)

- Percutaneous thermal ablation, often using microwave energy (radiofrequency and cryoablation are also acceptable), can be considered for oligometastatic liver disease, generally up to four lesions each smaller than 3 cm. Feasibility considerations include safe percutaneous imaging-guided approach to the target lesions, and proximity to vessels, bile ducts, or adjacent non-target structures that may require hydro- or aero-dissection for displacement.

Note: All recommendations are category 2A unless otherwise indicated.

Clinical Trials: NCCN believes that the best management of any patient with cancer is in a clinical trial. Participation in clinical trials is especially encouraged.

References



PRINCIPLES OF LIVER-DIRECTED THERAPY FOR NEUROENDOCRINE TUMOR METASTASES

REFERENCES

- ¹ Devulapalli KK, Fidelman N, Soulen MC, et al. 90Y radioembolization for hepatic Malignancy in patients with previous biliary intervention: Multicenter analysis of hepatobiliary infections. Radiology 2018;288:774-781.
- ² Patel S, Tuite CM, Mondschein JI, Soulen MC. Effectiveness of an aggressive antibiotic regimen for chemoembolization in patients with previous biliary intervention. J Vasc Interv Radiol 2006;17:1931-1934.
- ³ Kim W, Clark TW, Baum RA, Soulen MC. Risk factors for liver abscess formation after hepatic chemoembolization. J Vasc Interv Radiol 2001;12:965-968.
- ⁴ Cholapranee A, van Houten D, Deitrick G, et al. Risk of liver abscess formation in patients with prior biliary intervention following yttrium-90 radioembolization. Cardiovasc Interv Radiol 2015;38:397-400.
- ⁵ Braat AJAT, Ahmadzadehfar H, Kappadath SC, et al. Radioembolization with 90Y resin microspheres of neuroendocrine liver metastases after initial peptide receptor radionuclide therapy. Cardiovasc Interv Radiol 2020;43:246-253.
- ⁶ Braat AJAT, Bruijnen RCG, van Rooij R, et al. Additional holmium-166 radioembolisation after lutetium-177-dotatate in patients with neuroendocrine tumour liver metastases (HEPAR PLuS): a single-centre, single-arm, open-label, phase 2 study. Lancet Oncol 2021;22:561-570.

Note: All recommendations are category 2A unless otherwise indicated.

Clinical Trials: NCCN believes that the best management of any patient with cancer is in a clinical trial. Participation in clinical trials is especially encouraged.

**PRINCIPLES OF HORMONE CONTROL****Carcinoid Syndrome**

- Carcinoid syndrome (CS) primarily occurs in patients with metastatic well-differentiated NETs originating in the distal small intestine and proximal colon (midgut). CS can also be secondary to pulmonary NETs and rarely pancreatic NETs. Serotonin along with other vasoactive substances contributes to the syndrome.
- Signs and symptoms include flushing, diarrhea, wheezing (rare), and CHD (in patients with highly elevated serotonin levels).
 - Serotonin is thought to be the most important factor in the etiology of CS diarrhea and CHD, but the etiology of flushing is less well understood.
 - Refractory flushing or diarrhea is defined as suboptimal symptom control in the setting of long-acting SSAs (octreotide or lanreotide) used in approved doses.
 - It is important to note that diarrhea can be multifactorial: other common causes include direct side effects from SSAs, pancreatic exocrine insufficiency from SSA use resulting in steatorrhea, bile malabsorption from ileocectomy or cholecystectomy, and short-gut symptom.
- In patients with CS, invasive procedures should only be performed in centers with experienced anesthesiologists.

Symptom Management

- CS-diarrhea and flushing
 - Long-acting SSA (octreotide LAR and lanreotide) are highly active for control of both flushing and diarrhea.
 - Telotristat ethyl 250 mg TID is specifically recommended for patients with refractory diarrhea secondary to CS (usually with proven elevated serotonin or 5-HIAA), in combination with long-acting SSA. Symptomatic benefit can sometimes be delayed for several weeks after initiation of the drug.
 - Patients who experience symptom exacerbation towards the end of each 4-week SSA cycle can often benefit from more frequent administration (ie, every 3 weeks). Dose escalation can also sometimes benefit patients with refractory symptoms.
 - Short-acting octreotide, given subcutaneously, administered at doses of 150–250 mcg every 8 hours as needed, can be prescribed to patients with suboptimal control of flushing and/or diarrhea.
 - Serotonin antagonists such as ondansetron can improve refractory CS diarrhea in refractory patients.
 - Treatments that effectively cytoreduce secretory metastatic tumors are likely to palliate hormonal symptoms. For patients with liver-dominant disease, surgical cytoreduction or hepatic arterial embolization are highly effective at control of flushing and/or diarrhea. PRRT with ¹⁷⁷Lu-dotatate has been associated with delay in diarrhea progression.
 - Nonspecific antidiarrheals (ie, loperamide, diphenoxylate/atropine, tincture of opium) and cyproheptadine can be beneficial for management of refractory diarrhea, regardless of cause.
 - Cyproheptadine can be considered for control of flushing for patients who cannot tolerate SSA.
- Non CS-diarrhea
 - In patients who develop diarrhea/steatorrhea exacerbation while on SSA, a trial of pancreatic enzymes for pancreatic exocrine insufficiency should be considered.
 - Patients with persistent diarrhea after ileocectomy or cholecystectomy, especially if associated with urgency, can be treated empirically with bile acid binding drugs such as cholestyramine.
 - For patients with presumed short-gut syndrome, suggest referral to appropriate gastroenterologist expert.
 - Nonspecific antidiarrheals (ie, loperamide, diphenoxylate/atropine, tincture of opium) and cyproheptadine can be beneficial for management of refractory diarrhea, regardless of cause.
- CHD
 - CHD should be monitored by a cardiologist with expertise in the disease as the echocardiographic diagnosis of CHD can be challenging. Valve replacement (typically tricuspid and pulmonary) is indicated for symptomatic patients.

Note: All recommendations are category 2A unless otherwise indicated.

Clinical Trials: NCCN believes that the best management of any patient with cancer is in a clinical trial. Participation in clinical trials is especially encouraged.

**PRINCIPLES OF HORMONE CONTROL****Pancreatic Neuroendocrine Tumors**

- Medical, surgical, and interventional treatments that effectively cytoreduce secretory tumors are likely to also palliate hormonal symptoms. The following recommendations pertain to non-cytotoxic treatments, which can reduce hormonal secretions or mitigate secretory effects.

Hormone	Management
Gastrin	<ul style="list-style-type: none"> • Manage gastric hypersecretion with high-dose proton pump inhibitors, generally given two times a day. • Consider octreotide or lanreotide.
Insulin	<ul style="list-style-type: none"> • Stabilize glucose levels with diet and/or diazoxide or everolimus. • Octreotide or lanreotide can be considered but only if tumor expresses SSRs. In the absence of SSRs, octreotide or lanreotide can profoundly worsen hypoglycemia.
VIP	<ul style="list-style-type: none"> • Octreotide or lanreotide are the first-line management for control of hormone symptoms. • Correct electrolyte imbalance (K⁺, Mg²⁺, HCO₃⁻) and dehydration. • Corticosteroids can be effective in SSR-refractory patients.
Glucagon	<ul style="list-style-type: none"> • Octreotide or lanreotide are the first-line management for control of hormone symptoms. • Treat hyperglycemia and diabetes, as appropriate.

Note: All recommendations are category 2A unless otherwise indicated.

Clinical Trials: NCCN believes that the best management of any patient with cancer is in a clinical trial. Participation in clinical trials is especially encouraged.



American Joint Committee on Cancer (AJCC) TNM Staging System for Neuroendocrine Tumors of the Stomach (NET G1 and G2, and rare well-differentiated G3) (8th ed., 2017)

**Table 1. Definitions for T, N, M
Stomach**

T Primary Tumor

TX Primary tumor cannot be assessed

T0 No evidence of primary tumor

T1* Invades the lamina propria or submucosa and less than or equal to 1 cm in size

T2* Invades the muscularis propria or greater than 1 cm in size

T3* Invades through the muscularis propria into subserosal tissue without penetration of overlying serosa

T4* Invades visceral peritoneum (serosa) or other organs or adjacent structures

*Note: For any T, add (m) for multiple tumors [TX(#) or TX(m), where X = 1–4 and # = number of primary tumors identified**]; for multiple tumors with different Ts, use the highest.

**Example: If there are two primary tumors, one of which penetrates only the subserosa, we define the primary tumor as either T3(2) or T3(m).

N Regional Lymph Nodes

NX Regional lymph nodes cannot be assessed

N0 No regional lymph node metastasis

N1 Regional lymph node metastasis

M Distant Metastasis

M0 No distant metastasis

M1 Distant metastasis

M1a Metastasis confined to liver

M1b Metastases in at least one extrahepatic site (e.g., lung, ovary, nonregional lymph node, peritoneum, bone)

M1c Both hepatic and extrahepatic metastases

Table 2. AJCC Prognostic Stage Groups

	T	N	M
Stage I	T1	N0	M0
Stage II	T2, T3	N0	M0
Stage III	T1, T2, T3	N1	M0
	T4	N0, N1	M0
Stage IV	Any T	Any N	M1

[Continued](#)

Used with permission of the American College of Surgeons, Chicago, Illinois. The original source for this information is the AJCC Cancer Staging Manual, Eighth Edition (2017) published by Springer International Publishing.



American Joint Committee on Cancer (AJCC)

TNM Staging System for Well-Differentiated Neuroendocrine Tumors of the Duodenum and Ampulla of Vater (8th ed., 2017)

Table 3. Definitions for T, N, M
Duodenum/Ampulla

T Primary Tumor

TX Primary tumor not assessed

T1 Tumor invades the mucosa or submucosa only and is ≤1 cm (duodenal tumors);
Tumor ≤1 cm and confined within the sphincter of Oddi (ampullary tumors)

T2 Tumor invades the muscularis propria or is >1 cm (duodenal);
Tumor invades through sphincter into duodenal submucosa or muscularis propria,
or is >1 cm (ampullary)

T3 Tumor invades the pancreas or peripancreatic adipose tissue

T4 Tumor invades the visceral peritoneum (serosa) or other organs

Note: Multiple tumors should be designated as such (and the largest tumor should be used to assign the T category):

- If the number of tumors is known, use T(#); e.g., pT3(4)N0M0.
- If the number of tumors is unavailable or too numerous, use the suffix *m* —T(m)—e.g., pT3(m)N0M0.

N Regional Lymph Nodes

NX Regional lymph nodes cannot be assessed

N0 No regional lymph node involvement

N1 Regional lymph node involvement

M Distant Metastasis

M0 No distant metastasis

M1 Distant metastases

M1a Metastasis confined to liver

M1b Metastases in at least one extrahepatic site (e.g., lung,
ovary, nonregional lymph node, peritoneum, bone)

M1c Both hepatic and extrahepatic metastases

Table 4. AJCC Prognostic Stage Groups

	T	N	M
Stage I	T1	N0	M0
Stage II	T2	N0	M0
	T3	N0	M0
Stage III	T4	N0	M0
	Any T	N1	M0
Stage IV	Any T	Any N	M1

[Continued](#)

Used with permission of the American College of Surgeons, Chicago, Illinois. The original source for this information is the AJCC Cancer Staging Manual, Eighth Edition (2017) published by Springer International Publishing.



American Joint Committee on Cancer (AJCC)

TNM Staging System for Neuroendocrine Tumors of the Jejunum and Ileum (small bowel [NET G1 and G2, and rare well-differentiated G3] arising in the jejunum and ileum.) (8th ed., 2017)

**Table 5. Definitions for T, N, M
Jejunum/Ileum**

T Primary Tumor

- TX** Primary tumor cannot be assessed
- T0** No evidence of primary tumor
- T1*** Invades lamina propria or submucosa and less than or equal to 1 cm in size
- T2*** Invades muscularis propria or greater than 1 cm in size
- T3*** Invades through the muscularis propria into subserosal tissue without penetration of overlying serosa
- T4*** Invades visceral peritoneum (serosal) or other organs or adjacent structures

Note:* For any T, add (m) for multiple tumors [TX(#) or TX(m), where X = 1–4, and # = number of primary tumors identified]; for multiple tumors with different T, use the highest.

***Example:* If there are two primary tumors, only one of which invades through the muscularis propria into subserosal tissue without penetration of overlying serosa (jejunal or ileal), we define the primary tumor as either T3(2) or T3(m).

N Regional Lymph Nodes

- NX** Regional lymph nodes cannot be assessed
- N0** No regional lymph node involvement metastasis has occurred
- N1** Regional lymph node metastasis less than 12 nodes
- N2** Large mesenteric masses (>2 cm) and/or extensive nodal deposits (12 or greater), especially those that encase the superior mesenteric vessels

M Distant Metastasis

- M0** No distant metastasis
- M1** Distant metastasis
- M1a** Metastasis confined to liver
- M1b** Metastases in at least one extrahepatic site (e.g., lung, ovary, nonregional lymph node, peritoneum, bone)
- M1c** Both hepatic and extrahepatic metastases

Used with permission of the American College of Surgeons, Chicago, Illinois. The original source for this information is the AJCC Cancer Staging Manual, Eighth Edition (2017) published by Springer International Publishing.

Table 6. AJCC Prognostic Stage Groups

	T	N	M
Stage I	T1	N0	M0
Stage II	T2	N0	M0
	T3	N0	M0
Stage III	T1	N1, N2	M0
	T2	N1, N2	M0
	T3	N1, N2	M0
	T4	N0	M0
	T4	N1, N2	M0
Stage IV	Any T	Any N	M1

[Continued](#)



American Joint Committee on Cancer (AJCC)

TNM Staging System for Neuroendocrine Tumors of the Colon and Rectum [neuroendocrine tumor G1 and G2, and rare well-differentiated G3] (8th ed., 2017)

**Table 7. Definitions for T, N, M
Colon and Rectum**

T*	Primary Tumor
TX	Primary tumor cannot be assessed
T0	No evidence of primary tumor
T1	Tumor invades the lamina propria or submucosa and is ≤2 cm
T1a	Tumor <1 cm in greatest dimension
T1b	Tumor 1–2 cm in greatest dimension
T2	Tumor invades the muscularis propria or is >2 cm with invasion of the lamina propria or submucosa
T3	Tumor invades through the muscularis propria into subserosal tissue without penetration of overlying serosa
T4	Tumor invades the visceral peritoneum (serosa) or other organs or adjacent structures
*Note: For any T, add “(m)” for multiple tumors [TX(#) or TX(m), where X = 1–4 and # = number of primary tumors identified**]; for multiple tumors with different T, use the highest.	
**Example: If there are two primary tumors, only one of which invades through the muscularis propria into the subserosal tissue without penetration of the overlying serosa, we define the primary tumor as either T3(2) or T3(m).	
N	Regional Lymph Nodes
NX	Regional lymph nodes cannot be assessed
N0	No regional lymph node metastasis has occurred
N1	Regional lymph node metastasis
M	Distant Metastasis
M0	No distant metastasis
M1	Distant metastasis
M1a	Metastasis confined to liver
M1b	Metastases in at least one extrahepatic site (e.g., lung, ovary, nonregional lymph node, peritoneum, bone)
M1c	Both hepatic and extrahepatic metastases

Table 8. AJCC Prognostic Groups

	T	N	M
Stage I	T1	N0	M0
Stage IIA	T2	N0	M0
Stage IIB	T3	N0	M0
Stage IIIA	T4	N0	M0
Stage IIIB	T1	N1	M0
	T2	N1	M0
	T3	N1	M0
	T4	N1	M0
Stage IV	TX, T0	Any N	M1
	T1	Any N	M1
	T2	Any N	M1
	T3	Any N	M1
	T4	Any N	M1

Note: For multiple synchronous tumors, the highest T category should be used and the multiplicity or the number of tumors should be indicated in parenthesis, e.g., T3(2) or T3(m).

[Continued](#)

Used with permission of the American College of Surgeons, Chicago, Illinois. The original source for this information is the AJCC Cancer Staging Manual, Eighth Edition (2017) published by Springer International Publishing.



American Joint Committee on Cancer (AJCC)

TNM Staging System for Neuroendocrine Tumors of the Pancreas [well-differentiated neuroendocrine tumors arising in the pancreas] (8th ed., 2017)

Table 9. Definitions for T, N, M Pancreatic

T Primary Tumor

TX Tumor cannot be assessed

T1 Tumor limited to the pancreas,* <2 cm

T2 Tumor limited to the pancreas,* 2–4 cm

T3 Tumor limited to the pancreas,* >4 cm; or tumor invading the duodenum or common bile duct

T4 Tumor invading adjacent organs (stomach, spleen, colon, adrenal gland) or the wall of large vessels (celiac axis or the superior mesenteric artery)

**Limited to the pancreas* means there is no invasion of adjacent organs (stomach, spleen, colon, adrenal gland) or the wall of large vessels (celiac axis or the superior mesenteric artery). Extension of tumor into peripancreatic adipose tissue is NOT a basis for staging.

Note: Multiple tumors should be designated as such (the largest tumor should be used to assign T category):

- If the number of tumors is known, use T(#); e.g., pT3(4) N0 M0.
- If the number of tumors is unavailable or too numerous, use the *m* suffix, T(m); e.g., pT3(m) N0 M0.

N Regional Lymph Nodes

NX Regional lymph nodes cannot be assessed

N0 No regional lymph node involvement

N1 Regional lymph node involvement

M Distant Metastasis

M0 No distant metastasis

M1 Distant metastases

M1a Metastasis confined to liver

M1b Metastases in at least one extrahepatic site (e.g., lung, ovary, nonregional lymph node, peritoneum, bone)

M1c Both hepatic and extrahepatic metastases

Table 10. AJCC Prognostic Stage Groups

	T	N	M
Stage I	T1	N0	M0
Stage II	T2	N0	M0
	T3	N0	M0
Stage III	T4	N0	M0
	Any T	N1	M0
Stage IV	Any T	Any N	M1

[Continued](#)

Used with permission of the American College of Surgeons, Chicago, Illinois. The original source for this information is the AJCC Cancer Staging Manual, Eighth Edition (2017) published by Springer International Publishing.



American Joint Committee on Cancer (AJCC)

TNM Staging System for Neuroendocrine Tumors of the Appendix [NET G1 and G2, and rare well-differentiated G3] (8th ed., 2017)

**Table 11. Definitions for T, N, M
Appendiceal Neuroendocrine Tumors**

T Primary Tumor

TX Primary tumor cannot be assessed

T0 No evidence of primary tumor

T1 Tumor 2 cm or less in greatest dimension

T2 Tumor more than 2 cm but less than or equal to 4 cm

T3 Tumor more than 4 cm or with subserosal invasion or involvement of the mesoappendix

T4 Tumor perforates the peritoneum or directly invades other adjacent organs or structures (excluding direct mural extension to adjacent subserosa of adjacent bowel), e.g., abdominal wall and skeletal muscle

N Regional Lymph Nodes

NX Regional lymph nodes cannot be assessed

N0 No regional lymph node metastasis

N1 Regional lymph node metastasis

M Distant Metastasis

M0 No distant metastasis

M1 Distant metastasis

M1a Metastasis confined to liver

M1b Metastases in at least one extrahepatic site (e.g., lung, ovary, nonregional lymph node, peritoneum, bone)

M1c Both hepatic and extrahepatic metastases

Table 12. AJCC Prognostic Stage Groups

	T	N	M
Stage I	T1	N0	M0
Stage II	T2	N0	M0
	T3	N0	M0
Stage III	T1	N1	M0
	T2	N1	M0
	T3	N1	M0
	T4	N0	M0
	T4	N1	M0
Stage IV	TX, T0	Any N	M1
	T1	Any N	M1
	T2	Any N	M1
	T3	Any N	M1
	T4	Any N	M1

[Continued](#)

Used with permission of the American College of Surgeons, Chicago, Illinois. The original source for this information is the AJCC Cancer Staging Manual, Eighth Edition (2017) published by Springer International Publishing.



American Joint Committee on Cancer (AJCC)

TNM Staging System for Adrenal – Neuroendocrine Tumors [Pheochromocytoma and paraganglioma] (8th ed., 2017)

**Table 13. Definitions for T, N, M
Adrenal**

T Primary Tumor

TX Primary tumor cannot be assessed

T1 PH <5 cm in greatest dimension, no extra-adrenal invasion

T2 PH ≥5 cm or PG-sympathetic of any size, no extra-adrenal invasion

T3 Tumor of any size with local invasion into surrounding tissues (e.g., liver, pancreas, spleen, kidneys)

PH: within adrenal gland

PG Sympathetic: functional

PG Parasympathetic: nonfunctional, usually in the head and neck region

Note: Parasympathetic Paraganglioma are not staged because they are largely benign.

N Regional Lymph Nodes

NX Regional lymph nodes cannot be assessed

N0 No regional lymph node metastasis

N1 Regional lymph node metastasis

M Distant Metastasis

M0 No distant metastasis

M1 Distant metastasis

M1a Distant metastasis to only bone

M1b Distant metastasis to only distant lymph nodes/liver or lung

M1c Distant metastasis to bone plus multiple other sites

**Table 14. AJCC Prognostic Stage Groups
Pheochromocytoma/Sympathetic Paraganglioma**

	T	N	M
Stage I	T1	N0	M0
Stage II	T2	N0	M0
Stage III	T1	N1	M0
	T2	N1	M0
	T3	Any N	M0
Stage IV	Any T	Any N	M1

[Continued](#)

Used with permission of the American College of Surgeons, Chicago, Illinois. The original source for this information is the AJCC Cancer Staging Manual, Eighth Edition (2017) published by Springer International Publishing.



**American Joint Committee on Cancer (AJCC)
TNM Staging System for Adrenal Cortical Carcinoma (8th ed., 2017)**

**Table 15. Definitions for T, N, M
Adrenal Cortical Carcinoma**

T Primary Tumor

- TX** Primary tumor cannot be assessed
- T0** No evidence of primary tumor
- T1** Tumor ≤5 cm in greatest dimension, no extra-adrenal invasion
- T2** Tumor >5 cm, no extra-adrenal invasion
- T3** Tumor of any size with local invasion but not invading adjacent organs
- T4** Tumor of any size that invades adjacent organs (kidney, diaphragm, pancreas, spleen, or liver) or large blood vessels (renal vein or vena cava)

N Regional Lymph Nodes

- NX** Regional lymph nodes cannot be assessed
- N0** No regional lymph node metastasis
- N1** Metastasis in regional lymph node(s)

M Distant Metastasis

- M0** No distant metastasis
- M1** Distant metastasis

G Histologic Grade

- LG** Low grade (≤20 mitoses per 50 HPF)
- HG** High grade (>20 mitosis per 50 HPF); *TP53* or *CTNNB* mutation

Table 16. AJCC Prognostic Stage Groups

	T	N	M
Stage I	T1	N0	M0
Stage II	T2	N0	M0
Stage III	T1	N1	M0
	T2	N1	M0
	T3	Any N	M0
	T4	Any N	M0
Stage IV	Any T	Any N	M1

[Continued](#)

Used with permission of the American College of Surgeons, Chicago, Illinois. The original source for this information is the AJCC Cancer Staging Manual, Eighth Edition (2017) published by Springer International Publishing.

**American Joint Committee on Cancer (AJCC)****TNM Staging System for Lung (8th ed., 2017) [carcinomas of the lung, including non–small cell and small cell carcinomas, and bronchopulmonary carcinoid tumors].****Table 17. Definitions for T, N, M****Lung**

T	Primary Tumor
TX	Primary tumor cannot be assessed, or tumor proven by the presence of malignant cells in sputum or bronchial washings but not visualized by imaging or bronchoscopy
T0	No evidence of primary tumor
Tis	Carcinoma <i>in situ</i> Squamous cell carcinoma <i>in situ</i> (SCIS) Adenocarcinoma <i>in situ</i> (AIS): adenocarcinoma with pure lepidic pattern, ≤3 cm in greatest dimension
T1	Tumor ≤3 cm in greatest dimension, surrounded by lung or visceral pleura, without bronchoscopic evidence of invasion more proximal than the lobar bronchus (i.e., not in the main bronchus)
T1mi	Minimally invasive adenocarcinoma: adenocarcinoma (≤3 cm in greatest dimension) with a predominantly lepidic pattern and ≤5 mm invasion in greatest dimension
T1a	Tumor ≤1 cm in greatest dimension. A superficial, spreading tumor of any size whose invasive component is limited to the bronchial wall and may extend proximal to the main bronchus also is classified as T1a, but these tumors are uncommon.
T1b	Tumor >1 cm but ≤2 cm in greatest dimension
T1c	Tumor >2 cm but ≤3 cm in greatest dimension
T2	Tumor >3 cm but ≤5 cm or having any of the following features: <ul style="list-style-type: none"> • Involves the main bronchus regardless of distance to the carina, but without involvement of the carina • Invades visceral pleura (PL1 or PL2) • Associated with atelectasis or obstructive pneumonitis that extends to the hilar region, involving part or all of the lung T2 tumors with these features are classified as T2a if ≤4 cm or if the size cannot be determined and T2b if >4 cm but ≤5 cm.
T2a	Tumor >3 cm but ≤4 cm in greatest dimension
T2b	Tumor >4 cm but ≤5 cm in greatest dimension
T3	Tumor >5 cm but ≤7 cm in greatest dimension or directly invading any of the following: parietal pleural (PL3), chest wall (including superior sulcus tumors), phrenic nerve, parietal pericardium; or separate tumor nodule(s) in the same lobe as the primary
T4	Tumor >7 cm or tumor of any size invading one or more of the following: diaphragm, mediastinum, heart, great vessels, trachea, recurrent laryngeal nerve, esophagus, vertebral body, or carina; separate tumor nodule(s) in an ipsilateral lobe different from that of the primary

[Continued](#)

Used with permission of the American College of Surgeons, Chicago, Illinois. The original source for this information is the AJCC Cancer Staging Manual, Eighth Edition (2017) published by Springer International Publishing.



American Joint Committee on Cancer (AJCC)

TNM Staging System for Lung (8th ed., 2017) [carcinomas of the lung, including non–small cell and small cell carcinomas, and bronchopulmonary carcinoid tumors].

Table 17. Definitions for T, N, M (continued)

Lung

N Regional Lymph Nodes

NX Regional lymph nodes cannot be assessed

N0 No regional lymph node metastasis

N1 Metastasis in ipsilateral peribronchial and/or ipsilateral hilar lymph nodes and intrapulmonary nodes, including involvement by direct extension

N2 Metastasis in ipsilateral mediastinal and/or subcarinal lymph node(s)

N3 Metastasis in contralateral mediastinal, contralateral hilar, ipsilateral or contralateral scalene, or supraclavicular lymph node(s)

M Distant Metastasis

M0 No distant metastasis

M1 Distant metastasis

M1a Separate tumor nodule(s) in a contralateral lobe; tumor with pleural or pericardial nodules or malignant pleural or pericardial effusion. Most pleural (pericardial) effusions with lung cancer are a result of the tumor. In a few patients, however, multiple microscopic examinations of pleural (pericardial) fluid are negative for tumor, and the fluid is nonbloody and not an exudate. If these elements and clinical judgment dictate that the effusion is not related to the tumor, the effusion should be excluded as a staging descriptor.

M1b Single extrathoracic metastasis in a single organ (including involvement of a single nonregional node)

M1c Multiple extrathoracic metastases in a single organ or in multiple organs

Table 18. AJCC Prognostic Stage Groups

	T	N	M
Occult Carcinoma	TX	N0	M0
Stage 0	Tis	N0	M0
Stage IA1	T1mi, T1a	N0	M0
Stage IA2	T1b	N0	M0
Stage IA3	T1c	N0	M0
Stage IB	T2a	N0	M0
Stage IIA	T2b	N0	M0
Stage IIB	T1a, T1b, T1c T2a, T2b	N1	M0
	T3	N0	M0
Stage IIIA	T1a, T1b, T1c T2a, T2b	N2	M0
	T3	N1	M0
	T4	N0, N1	M0
Stage IIIB	T1a, T1b, T1c T2a, T2b	N3	M0
	T3	N2	M0
	T4	N2	M0
Stage IIIC	T3	N3	M0
	T4	N3	M0
Stage IVA	Any T	Any N	M1a
	Any T	Any N	M1b
Stage IVB	Any T	Any N	M1c

[Continued](#)

Used with permission of the American College of Surgeons, Chicago, Illinois. The original source for this information is the AJCC Cancer Staging Manual, Eighth Edition (2017) published by Springer International Publishing.



American Joint Committee on Cancer (AJCC)

TNM Staging System for Thymus (8th ed., 2017) [including thymoma, thymic carcinoma, thymic neuroendocrine tumors, combined thymic carcinoma]

Table 19. Definitions for T*,, N*, M Thymus**

T*,**	Primary Tumor
TX	Primary tumor cannot be assessed
T0	No evidence of primary tumor
T1	Tumor encapsulated or extending into the mediastinal fat; may involve the mediastinal pleura
T1a	Tumor with no mediastinal pleura involvement
T1b	Tumor with direct invasion of mediastinal pleura
T2	Tumor with direct invasion of the pericardium (either partial or full thickness)
T3	Tumor with direct invasion into any of the following: lung, brachiocephalic vein, superior vena cava, phrenic nerve, chest wall, or extrapericardial pulmonary artery or veins
T4	Tumor with invasion into any of the following: aorta (ascending, arch, or descending), arch vessels, intrapericardial pulmonary artery, myocardium, trachea, esophagus
N*	Regional Lymph Nodes
NX	Regional lymph nodes cannot be assessed
N0	No regional lymph node metastasis
N1	Metastasis in anterior (perithymic) lymph nodes
N2	Metastasis in deep intrathoracic or cervical lymph nodes

*Involvement must be microscopically confirmed in pathological staging, if possible.

**T categories are defined by “levels” of invasion; they reflect the highest degree of invasion regardless of how many other (lower-level) structures are invaded. T1, level 1 structures: thymus, anterior mediastinal fat, mediastinal pleura; T2, level 2 structures: pericardium; T3, level 3 structures: lung, brachiocephalic vein, superior vena cava, phrenic nerve, chest wall, hilar pulmonary vessels; T4, level 4 structures: aorta (ascending, arch, or descending), arch vessels, intrapericardial pulmonary artery, myocardium, trachea, esophagus.

M	Distant Metastasis
M0	No pleural, pericardial, or distant metastasis
M1	Pleural, pericardial, or distant metastasis
M1a	Separate pleural or pericardial nodule(s)
M1b	Pulmonary intraparenchymal nodule or distant organ metastasis

Table 20. AJCC Prognostic Stage Groups

	T	N	M
Stage I	T1a, b	N0	M0
Stage II	T2	N0	M0
Stage IIIA	T3	N0	M0
Stage IIIB	T4	N0	M0
Stage IVA	Any T	N1	M0
	Any T	N0, N1	M1a
Stage IVB	Any T	N2	M0, M1a
	Any T	Any N	M1b

[Continued](#)

Used with permission of the American College of Surgeons, Chicago, Illinois. The original source for this information is the AJCC Cancer Staging Manual, Eighth Edition (2017) published by Springer International Publishing.



American Joint Committee on Cancer (AJCC)

TNM Staging System for Ampulla of Vater (8th ed., 2017) [applies to all primary carcinomas that arise in the ampulla or on the duodenal papilla, including high-grade neuroendocrine carcinomas such as small cell carcinoma and large cell neuroendocrine carcinoma]

Table 21. Definitions for T, N, M

Ampulla of Vater (high-grade neuroendocrine carcinoma)

T Primary Tumor

TX Primary tumor cannot be assessed

T0 No evidence of primary tumor

Tis Carcinoma *in situ*

T1 Tumor limited to ampulla of Vater or sphincter of Oddi or tumor invades beyond the sphincter of Oddi (perisphincteric invasion) and/or into the duodenal submucosa

T1a Tumor limited to ampulla of Vater or sphincter of Oddi

T1b Tumor invades beyond the sphincter of Oddi (perisphincteric invasion) and/or into the duodenal submucosa

T2 Tumor invades into the muscularis propria of the duodenum

T3 Tumor directly invades the pancreas (up to 0.5 cm) or tumor extends more than 0.5 cm into the pancreas, or extends into peripancreatic or periduodenal tissue or duodenal serosa without involvement of the celiac axis or superior mesenteric artery

T3a Tumor directly invades pancreas (up to 0.5 cm)

T3b Tumor extends more than 0.5 cm into the pancreas, or extends into peripancreatic tissue or periduodenal tissue or duodenal serosa without involvement of the celiac axis or superior mesenteric artery

T4 Tumor involves the celiac axis, superior mesenteric artery, and/or common hepatic artery, irrespective of size

N Regional Lymph Nodes

NX Regional lymph nodes cannot be assessed

N0 No regional lymph node metastasis

N1 Metastasis to one to three regional lymph nodes

N2 Metastasis to four or more regional lymph nodes

M Distant Metastasis

M0 No distant metastasis

M1 Distant metastasis

Table 22. AJCC Prognostic Stage Groups

	T	N	M
Stage 0	Tis	N0	M0
Stage IA	T1a	N0	M0
Stage IB	T1b, T2	N0	M0
Stage IIA	T3a	N0	M0
Stage IIB	T3b	N0	M0
Stage IIIA	T1a, T1b, T2, T3a, T3b	N1	M0
Stage IIIB	T4	Any N	M0
	Any T	N2	M0
Stage IV	Any T	Any N	M1

Used with permission of the American College of Surgeons, Chicago, Illinois. The original source for this information is the AJCC Cancer Staging Manual, Eighth Edition (2017) published by Springer International Publishing.



NCCN Categories of Evidence and Consensus

Category 1	Based upon high-level evidence, there is uniform NCCN consensus that the intervention is appropriate.
Category 2A	Based upon lower-level evidence, there is uniform NCCN consensus that the intervention is appropriate.
Category 2B	Based upon lower-level evidence, there is NCCN consensus that the intervention is appropriate.
Category 3	Based upon any level of evidence, there is major NCCN disagreement that the intervention is appropriate.

All recommendations are category 2A unless otherwise indicated.

NCCN Categories of Preference

Preferred intervention	Interventions that are based on superior efficacy, safety, and evidence; and, when appropriate, affordability.
Other recommended intervention	Other interventions that may be somewhat less efficacious, more toxic, or based on less mature data; or significantly less affordable for similar outcomes.
Useful in certain circumstances	Other interventions that may be used for selected patient populations (defined with recommendation).

All recommendations are considered appropriate.



NCCN Guidelines Version 4.2021 Neuroendocrine and Adrenal Tumors

Discussion

This discussion section corresponds to the NCCN Guidelines for Neuroendocrine and Adrenal Tumors. Last updated: December 14th, 2021.

Table of Contents

Overview	MS-2	Pheochromocytomas/Parangliomas	MS-36
Literature Search Criteria and Guidelines Update Methodology	MS-2	Multiple Endocrine Neoplasia	MS-40
Histologic Classification and Staging of Neuroendocrine and Adrenal Tumors	MS-3	MEN1	MS-40
Histologic Classification	MS-3	MEN2 and Familial MTC.....	MS-44
Staging	MS-4	Future Trial Design	MS-46
Pathologic Reporting	MS-5	References	MS-48
Other Potential Prognostic Markers	MS-5		
Principles of Genetic Risk Assessment and Counseling	MS-5		
Sporadic Neuroendocrine Tumors	MS-6		
Neuroendocrine Tumors of the Gastrointestinal Tract (Well-Differentiated Grade 1/2), Lung, and Thymus	MS-6		
Neuroendocrine Tumors of the Pancreas (Well-Differentiated Grade 1/2)	MS-19		
Neuroendocrine Tumors of Unknown Primary.....	MS-27		
Well-Differentiated Grade 3 Neuroendocrine Tumors.....	MS-28		
Poorly Differentiated Neuroendocrine Carcinomas/Large or Small Cell Carcinomas or Unknown Primary	MS-30		
Adrenal Gland Tumors	MS-32		



NCCN Guidelines Version 4.2021

Neuroendocrine and Adrenal Tumors

Overview

Neuroendocrine tumors (NETs) are thought to arise from cells throughout the diffuse endocrine system. They comprise a broad family of tumors, the most common of which are in the gastrointestinal (GI) tract, lungs and bronchi [so-called bronchopulmonary], thymus, and pancreas. Sites of origin within the GI tract include the stomach, small intestine, appendix, and rectum.^{1,2} Other NETs include those arising in the parathyroid, thyroid, adrenal, and pituitary glands.

An analysis of the SEER database estimated that the incidence of NETs in the United States was 6.98 cases per 100,000 people in the year 2012.² This analysis suggested that the incidence of NETs is increasing, and that the prevalence of individuals with NETs in the United States may exceed 170,000. Other independent analyses of the SEER database also found that the incidence of GI NETs increased from 1975 to 2008.^{3,4} The reasons for this increase are unclear, although it seems likely that improved diagnosis and classification is one factor.⁵

Most NETs seem to be sporadic and risk factors for sporadic NETs are poorly understood. NETs may also arise in the context of inherited genetic syndromes, including multiple endocrine neoplasia types 1 (MEN1), 2 (MEN2), and 4 (MEN4), and succinate dehydrogenase (SDHx) mutations. NETs have also been associated with other conditions, including von Hippel-Lindau (VHL) disease, tuberous sclerosis complex, and neurofibromatosis.^{6,7} MEN1, associated with mutations in the *menin* gene, is characterized by multiple tumors of the parathyroid, pituitary, and pancreatic glands.⁸ MEN2, associated with mutations in the *RET* proto-oncogene, is characterized by the development of medullary thyroid cancer, pheochromocytoma (often bilateral), and hyperparathyroidism.⁹ NETs have also been associated with other conditions, including VHL disease, tuberous sclerosis complex, and neurofibromatosis.^{6,7}

Patients with NETs can have symptoms attributable to hormonal hypersecretion. These symptoms include intermittent flushing and diarrhea in patients with GI NETs,¹⁰ bronchospasm and wheezing in lung NETs,¹⁰ hypertension in patients with pheochromocytoma or paraganglioma,¹¹ and symptoms attributable to secretion of insulin, glucagon, gastrin, and other peptides in patients with pancreatic NETs.¹² Patients with hormonal symptoms are considered to have “functional” tumors, and those without symptoms are considered to have “nonfunctional” tumors.

Appropriate diagnosis and treatment of NETs often involves collaboration between specialists in multiple disciplines, using specific biochemical, radiologic, and surgical methods. Specialists include pathologists, endocrinologists, radiologists (including nuclear medicine specialists), and medical, radiation, and surgical oncologists.

These guidelines discuss the diagnosis and management of both sporadic and hereditary neuroendocrine and adrenal tumors and are intended to assist with clinical decision-making. Most of the guideline sections pertain to well-differentiated, low- to intermediate-grade tumors, although well-differentiated high-grade tumors and poorly differentiated/ large or small cell carcinomas are also addressed (see *Poorly Differentiated Neuroendocrine Carcinomas/Large or Small Cell Carcinomas or Unknown Primary*, below). Medical practitioners should note that unusual patient scenarios (presenting in <5% of patients) are not specifically discussed in these guidelines.

Literature Search Criteria and Guidelines Update Methodology

Prior to the update of this version of the NCCN Guidelines for Neuroendocrine Tumors, an electronic search of the PubMed database was performed to obtain key literature published in the field since the previous Guidelines update, using the following search terms:



NCCN Guidelines Version 4.2021

Neuroendocrine and Adrenal Tumors

neuroendocrine tumor OR adrenal cancer OR carcinoid OR pheochromocytoma OR paraganglioma OR Multiple Endocrine Neoplasia. The PubMed database was chosen as it remains the most widely used resource for medical literature and indexes peer-reviewed biomedical literature.¹³

The search results were narrowed by selecting studies in humans published in English. Results were confined to the following article types: Clinical Trial, Phase II; Clinical Trial, Phase III; Practice Guideline; Randomized Controlled Trial; Meta-Analysis; Systematic Reviews; and Validation Studies.

The data from key PubMed articles as well as articles from additional sources deemed as relevant to these guidelines as discussed by the panel during the Guidelines update have been included in this version of the Discussion section. Recommendations for which high-level evidence is lacking are based on the panel's review of lower-level evidence and expert opinion.

The complete details of the development and update of the NCCN Guidelines are available at www.NCCN.org.

Histologic Classification and Staging of Neuroendocrine and Adrenal Tumors

NETs are generally subclassified by site of origin, stage, and histologic characteristics.

Histologic Classification

Neuroendocrine neoplasms (NENs) are divided into NETs and neuroendocrine carcinomas (NECs). The 2019 WHO classification of NENs includes significant updates.¹⁴ Previously, the GI NENs and the pancreatic NENs were classified separately; now they share a common classification scheme.^{14,15} NETs are well-differentiated while NECs are

poorly differentiated neoplasms. Well differentiated NETs are further classified into 3 categories: low-grade (G1); intermediate-grade (G2); high-grade (G3). All poorly differentiated NECs are G3 but not all G3 NENs are poorly differentiated. Some tumors can have mixed, both well and poorly differentiated histology and are termed as mixed neuroendocrine-non-neuroendocrine neoplasms (MiNENs).

Tumor differentiation and tumor grade often correlate with mitotic count and Ki-67 proliferation index. In fact, most commonly used histologic classification schemes, including the European Neuroendocrine Tumor Society (ENETS), World Health Organization (WHO) systems, and the International Agency for Research on Cancer, incorporate mitotic rate and Ki-67 index.^{12,15-19} Numerous studies have confirmed that increased mitotic rate and high Ki-67 index are associated with a more aggressive clinical course and worse prognosis.²⁰⁻²³ In GI and pancreatic NETs, well-differentiated, low-grade tumors have a mitotic count of less than 2/10 high-power field (HPF) and/or a Ki-67 index of less than 3%. Well-differentiated, intermediate-grade tumors have a mitotic count of 2 to 20/10 HPF and/or a Ki-67 index of 3% to 20%. In high-grade well-differentiated tumors, the mitotic count exceeds 20/10 HPF and/or the Ki-67 index exceeds 20%.

Grade is generally defined by mitotic count and/or Ki-67 index, whichever is higher. If both mitotic rate and Ki-67 index are used and these are discordant, it is currently recommended that the higher grade be used to assign classification.²⁴⁻²⁶ Ki-67 immunohistochemistry should be analyzed and/or counted in the areas of highest activity referred to as "hot spots". A key recommendation is that tumor differentiation, mitotic rate, and Ki-67 index should all be included in the pathology report. Doing so allows the treating physician to factor these data into the clinical picture to make appropriate treatment decisions in GI and pancreatic NENs. The current grading of lung NENs does not rely on Ki-67.²⁷



NCCN Guidelines Version 4.2021

Neuroendocrine and Adrenal Tumors

The classification of lung and thymus NETs varies from that of gastroenteropancreatic NETs in some classification systems, and in particular does not include Ki-67 and includes the assessment of necrosis. Well-differentiated NETs of the lung and thymus are considered typical (low-grade, <2 mitoses/10 HPF and no necrosis) or atypical (intermediate grade, 2–10 mitoses/10 HPF and/or foci of necrosis), using histologic criteria.²⁸

High-grade, poorly differentiated lung and thymus NECs are of either small cell or large cell cytology, with greater than 10 mitoses/10 HPF and extensive foci of necrosis.^{26,29-31}

Considerable debate remains as to the most appropriate Ki-67 proliferative threshold for the determination of tumor grade and consequent treatment decisions.^{32,33} A retrospective database review of 252 patients with high-grade GI NEC suggested that platinum-based chemotherapy is most active in those with a Ki-67 index of greater than or equal to 55%.³⁴ These results suggest that a higher Ki-67 cutoff than is currently recommended may be more appropriate to classify tumors as high grade. Conversely, for low-grade tumors, some studies have suggested that the currently accepted cutoff may be too low. An analysis of data from 274 patients with pancreatic NETs found that a 5% Ki-67 cutoff (rather than 2%) was the optimal prognostic indicator.³⁵ A comparable analysis based on 691 patients with jejunal-ileocecal NETs similarly found that a threshold of 5 mitoses/10 HPF provided better prognostic information than one of 2 mitoses/10 HPF.³⁶

Staging

NETs are staged according to the AJCC tumor (T), node (N), metastasis (M) staging system. The AJCC introduced its first TNM staging system for the classification of NETs in its 7th edition of the AJCC Cancer Staging Manual.³⁷ The T and N definitions and other staging definitions were

revised in the 8th edition of the AJCC Cancer Staging Manual.³⁸ The 8th edition also added the first staging system for thymic tumors and adrenal NETs (including staging for pheochromocytoma and paraganglioma).³⁸ NETs of the stomach, duodenum/ampulla, jejunum/ileum, appendix, colon/rectum, and pancreas have separate staging systems. The association of tumor stage with prognosis has been confirmed in analyses of the SEER database and the National Cancer Database.³⁹⁻⁴⁵ An analysis of 691 patients with jejunal-ileocecal NETs treated at the Moffitt Cancer Center between 2000 and 2010 revealed 5-year survival rates of 100%, 100%, 91%, and 72% for stages I through IV, respectively, further validating the TNM staging system.³⁶ Of note, however, this analysis also suggested that, unlike other malignancies, primary tumor size and depth of invasion had little bearing on survival in early-stage disease.³³ Similar results were reported in a separate analysis of 6792 small intestine NETs in the SEER database, which found that outcomes were similar for patients with T1 and T2 tumors.⁴⁶ These results have been supported in additional analyses, confirming that the presence of lymph node and distant metastases have the strongest effect on survival.^{47,48}

NETs of the lungs and bronchi are staged in the same manner as more common lung carcinomas. As in lung carcinoma, more advanced tumor stage for NETs of the lungs and bronchi is associated with worse prognosis.^{37,38}

The TNM staging system for the classification of pancreatic NETs in the 8th edition of the AJCC Cancer Staging Manual is separate from exocrine pancreatic carcinoma.^{37,38} The primary tumor (T) is differentiated based on size and involvement of major vessels or other organs (see *Staging* in the guidelines). A retrospective analysis of 425 patients with pancreatic NETs treated at the Moffitt Cancer Center between 1999 and 2010 validated the AJCC 2017 classification system, with 5-year overall survival (OS) rates of 92%, 84%, 81%, and 57% for stages I through IV, respectively ($P <$



NCCN Guidelines Version 4.2021

Neuroendocrine and Adrenal Tumors

.001).⁴⁹ Although the trends of this analysis are consistent with population-based studies, the survival rates from this analysis were significantly higher than those seen in population-based studies.^{50,51} For example, in the SEER database analysis of pancreatic NETs, the 5-year survival rate for patients with metastatic disease was only 19.5%.⁵¹

Pathologic Reporting

In addition to information on histologic classification and stage, the margin status (positive or negative) and the presence of vascular or perineural invasion should be included in the pathology report; some studies have suggested that these factors may also have prognostic significance.^{52,53}

Whether or not tumors are associated with symptoms of hormone hypersecretion ("functioning" or "non-functioning") is a clinical rather than histologic diagnosis. The presence of hormone-staining granules without a clinical syndrome does not make a tumor "functioning." Thus, functional status is usually not included in the pathology report.

Other Potential Prognostic Markers

Chromogranin A is a secreted protein that may be elevated in patients with NETs; elevated levels have been associated with poorer prognosis. In select cases, chromogranin A may have prognostic value but treatment decisions are not based solely on changes in chromogranin. The neuroendocrine neoplasms test (NETest) is a blood-based biomarker test that measures the expression level of multiple analytes.⁵⁴ It can help in the identification of small bowel, pancreas, and bronchopulmonary neuroendocrine neoplasms, as well as pheochromocytomas and paragangliomas. In a validation study, the NETest demonstrated high sensitivity (>95%) in patients with well-differentiated, metastatic NETs.⁵⁵ The molecular basis of NETs remains poorly understood, and additional molecular predictors of outcome remain investigational. One study found that overexpression of mammalian target of rapamycin (mTOR) or its

downstream targets was associated with shorter OS in 195 neuroendocrine tissue samples (15% were located in the pancreas; 85% were GI carcinoids).⁵⁶ Small bowel carcinoid (neuroendocrine) tumors have been found to have recurrent mutations in the cyclin-dependent kinase inhibitor, CDKN1B (p27),⁵⁷ and loss of CDKN1B expression has been reported to be an adverse prognostic factor in gastroenteropancreatic NETs.⁵⁸ Circulating tumor cells (CTCs) have also been studied as possible prognostic markers, based on the idea that tumor cells in the blood would be indicative of more disseminated disease. Another study found that the presence of greater than or equal to 1 CTC in 7.5 mL of blood was independently associated with worse progression-free survival (PFS) and OS in patients with varying pretreated metastatic NETs from various primary sites.⁵⁹

More research is required, however, before these and other new molecular assays are routinely used in the clinic. A multinational consensus meeting of experts concluded that, to date, no single currently available biomarker is sufficient as a diagnostic, prognostic, or predictive marker in patients with NETs.⁶⁰

Principles of Genetic Risk Assessment and Counseling

In the 2021 guidelines, the panel included a new principles of genetic risk assessment and counseling for hereditary endocrine neoplasias. This section outlines how to go about genetic counseling, provides an overview of clinical manifestations associated with these disorders, and advises the readers of resources that can be accessed for more information (eg, how to find a genetic counselor, see *Principles of Genetic Risk Assessment and Counseling* in the algorithm). Recommendations are provided regarding pre-test counseling, considerations when determining the most appropriate testing strategy, post-test counseling, and criteria for genetic risk evaluation for hereditary endocrine neoplasia syndromes.



NCCN Guidelines Version 4.2021

Neuroendocrine and Adrenal Tumors

Genetic risk evaluation is recommended in patients with any of the following: 1) adrenocortical carcinoma (ACC); 2) paraganglioma/pheochromocytoma; 3) gastrinoma (duodenal/pancreatic or type 2 gastric NET); 4) multifocal pancreatic NETs; 5) parathyroid adenoma or primary hyperparathyroidism before age 30, multiple parathyroid adenomas, multigland hyperplasia (without obvious secondary causes), or recurrent primary hyperparathyroidism; 6) clinical suspicion for MEN2 due to the presence of medullary thyroid cancer or other combination of MEN2-related features; 7) a mutation identified on tumor genomic testing that has clinical implications if also identified in the germline (eg, tumor analysis shows a mutation in *BRCA1/2* or mismatch repair (MMR) gene); 8) a close blood relative with a known pathogenic variant/likely pathogenic variant in a cancer susceptibility gene; 9) a first-degree relative meeting one of the above criteria but not available for testing; and 10) clinical suspicion for MEN1 due to 2 or more of the following, or 1 of the following and a family history of 1 or more of the following: primary hyperparathyroidism, duodenal/pancreatic NET, pituitary adenoma, or foregut carcinoid (bronchial, thymic, or gastric). Genetic risk evaluation should be considered at any age in patients with duodenal/pancreatic NET.

Genetic syndromes covered in this section include hereditary paraganglioma/pheochromocytoma syndrome; MEN1, MEN2, and MEN4; neurofibromatosis type 1; tuberous sclerosis complex; and VHL syndrome. Some resources are also listed for hereditary cancer predisposition syndromes associated with ACCs such as Li-Fraumeni syndrome, Lynch syndrome, MEN1, and familial adenomatous polyposis (see *Principles of Genetic Risk Assessment and Counseling* in the algorithm). Additional screening recommendations are also provided for patients with hereditary paraganglioma/pheochromocytoma, MEN2, and VHL syndrome.

Sporadic Neuroendocrine Tumors

Neuroendocrine Tumors of the Gastrointestinal Tract (Well-Differentiated Grade 1/2), Lung, and Thymus

Approximately one-third of neuroendocrine (carcinoid) tumors arise in the lungs or thymus, and two-thirds arise in the GI tract. Sites of origin within the GI tract include the stomach, small intestine, appendix, and rectum.^{1,2} The prognosis for patients with NETs varies according to the stage at diagnosis, histologic classification, and primary site of the tumor (see *Histologic Classification and Staging of Neuroendocrine and Adrenal Tumors*, above).

NETs of the GI tract, lung, or thymus may secrete various hormones and vasoactive peptides. Bronchial and thymic NETs have been associated with adrenocorticotrophic hormone (ACTH) production and are a cause of Cushing syndrome.^{61,62} NETs arising in the small intestine or appendix are more commonly associated with carcinoid syndrome, related to the secretion of serotonin, histamine, or tachykinins into the systemic circulation causing episodic flushing and diarrhea.⁶³ Approximately 50% to 66% of patients with carcinoid syndrome develop valvular cardiac complications consisting of tricuspid regurgitation and/or pulmonary stenosis.⁶⁴

The metabolic products released by intestinal NETs are rapidly destroyed by liver enzymes in the portal circulation. Thus, the classical syndrome, occurring in approximately 8% to 28% of patients with NETs,^{65,66} is not usually observed unless liver metastases or rarely retroperitoneal disease have occurred, in which case hepatic metastases release metabolic products directly into the systemic circulation via the hepatic veins.

These guidelines address seven major subtypes of NETs of the GI tract, lung, and thymus: 1) jejunal/ileal/colon, 2) duodenal, 3) appendix, 4) rectal, 5) gastric, 6) bronchopulmonary, and 7) thymus.



NCCN Guidelines Version 4.2021

Neuroendocrine and Adrenal Tumors

Evaluation of Neuroendocrine Tumors of the Gastrointestinal Tract (Well-Differentiated Grade 1/2), Lung, and Thymus

Patients who present with suspected NETs of the GI tract, lung, or thymus should be evaluated with imaging studies to assess disease burden and possible primary location. Commonly used techniques include CT and MRI. NETs of the GI tract, lung, and thymus are highly vascular and can appear isodense with liver on conventional CT scan, depending on contrast phase. Multiphase CT or MRI scans with contrast should therefore be used for evaluation of liver metastasis. Chest CT scans with or without contrast are also recommended as appropriate to assess for lung metastases.

Because most NETs overexpress high-affinity receptors for somatostatin,^{63,67} a peptide hormone generated by the hypothalamus that blocks the release of growth hormones,⁶⁸ somatostatin receptor (SSR)-based imaging may be considered in the initial evaluation of patients with NETs. Such imaging can provide useful information on overall tumor burden and location; additionally, positive imaging confirms the presence of SSRs, which can have therapeutic implications. A major advance in imaging NETs came with the 2016 FDA approval of PET/CT imaging using the radiolabeled somatostatin analog gallium-68 (68Ga) DOTATATE. Several studies have shown the diagnostic utility, safety, specificity, and high sensitivity of 68Ga-DOTATATE PET/CT.⁶⁹⁻⁷³ A systematic review and meta-analysis of 22 studies determined that 68Ga-DOTATATE had a pooled sensitivity and specificity of 91% and 94%, respectively, for the initial diagnosis of NETs.⁷⁴ One study even showed that it was able to more correctly identify patients for peptide receptor radiotherapy than ¹¹¹indium-diethylenetriaminepentaacetic acid (¹¹¹In-DTPA) scintigraphy.⁷⁵ The 2018 Appropriate Use Criteria for Somatostatin Receptor PET Imaging in NETs recommends the use of SSR PET over ¹¹¹In-DTPA scintigraphy.^{69-71,76} Unless otherwise indicated, the preferred SSR-based imaging in this discussion includes SSR-PET/CT or SSR-PET/MRI

imaging using 68Ga-DOTATATE, 68Ga-DOTATOC, or 64Cu-DOTATATE. SSR scintigraphy using ¹¹¹In-octreotide (with SPECT/CT) is appropriate only if SSR-PET is not available. SSR-PET imaging is more sensitive than SSR scintigraphy for determining SSR status. Data are limited on whether long-acting SSR inhibition interferes with 68Ga-DOTATATE PET/CT scans, but one study⁷⁷ showed that timing does not make a difference.

Additional imaging recommendations vary by disease site and include colonoscopy, endoscopic ultrasound (EUS), and/or esophagogastroduodenoscopy (EGD) as appropriate for duodenal and gastric NETs; endorectal ultrasound for rectal NETs; and bronchoscopy and brain MRI, as appropriate for bronchopulmonary NETs.

Biochemical evaluation can also be helpful in the initial diagnostic evaluation, particularly in patients who have clinical symptoms that are suggestive of hormone hypersecretion. Evaluation of serotonin secretion, using a 24-hour urine or plasma collection for 5-hydroxyindoleacetic acid (5-HIAA), is generally recommended in patients with metastatic lung or GI NETs, particularly if carcinoid syndrome, manifested by symptoms of flushing and diarrhea, is suspected. Screening for hormones in asymptomatic individuals is not routinely recommended.

Chromogranin A is sometimes used as a biochemical marker in non-functioning tumors. Whereas one meta-analysis calculated the sensitivity and specificity of chromogranin A to be 73% and 95%, respectively, for diagnosis of NETs,⁷⁸ others have questioned its value. Chromogranin A is elevated in patients with renal or hepatic impairment and in patients receiving proton pump inhibitors (PPIs), and in general should not be relied upon in isolation as a diagnostic test. In 2021, the panel removed chromogranin A from the algorithm as it lacks specificity and test values can fluctuate, which can lead to false-positive results. Unlike chromogranin A, the NETest scores are not impacted by the use of PPIs.⁵⁴ However, the panel did not include NETest in the algorithm as there are no randomized



NCCN Guidelines Version 4.2021

Neuroendocrine and Adrenal Tumors

or phase II data for NETest. While these tests can be useful for select patients, test results alone should not be used to guide treatment decisions.

Genetic counseling and testing for inherited genetic syndromes should be considered. A workup for Cushing syndrome and carcinoid syndrome (discussed in *Evaluation and Treatment of Cushing Syndrome*, below) may also be indicated in cases of bronchopulmonary or thymic NETs if signs and symptoms of hypercortisolemia are suspected. Details of the evaluation and diagnosis of a patient with Cushing syndrome from a bronchial NET have been published.⁷⁹

Management of Locoregional Disease

The management of locoregional NETs of the GI tract, lung, and thymus depends on tumor size, primary site, and the general condition of the patient. Resection is the primary treatment approach for most localized NETs of the GI tract, lung, and thymus. Although symptoms of hormone hypersecretion are more common in patients with metastatic disease, for patients with locoregional disease and symptoms of hormone hypersecretion, symptom control with octreotide or lanreotide is paramount. Octreotide and lanreotide also may be considered for tumor control in patients with locoregional disease who have SSR-positive imaging (see *Management of Locoregional Advanced and/or Distant Metastatic Gastrointestinal Tract (Well-Differentiated Grade 1/2), Neuroendocrine Tumors or of the Bronchopulmonary or Thymic Neuroendocrine Tumors*, below). Specific recommendations for management of NET subtypes are described herein.

Gastric Neuroendocrine Tumors

Three types of gastric NETs are recognized: type 1 (associated with chronic atrophic gastritis or high gastric pH); type 2 (associated with antrum-sparing type A Zollinger-Ellison syndrome); and type 3 (sporadic and unifocal)⁸⁰ Types 1 and 2 gastric NETs are both associated with

hypergastrinemia; the major difference between them is that patients with type 1 gastric NETs generally have antrum-sparing atrophic gastritis with a loss of the usual negative feedback loop on the gastrin-producing cells of the antrum by acid, resulting in hypergastrinemia and excess stimulation of the endocrine cells of the fundus, and patients with type 2 gastric NETs have evidence of acid hypersecretion secondary to gastrinoma (Zollinger-Ellison syndrome).⁸⁰ Type 1 gastric NETs pursue an indolent course, with a rate of metastases of less than 5%. Evidence suggestive of type 1 disease includes a histologic diagnosis of atrophic gastritis on gastric biopsy, elevated gastric pH, vitamin B12 deficiency, and positive anti-intrinsic factor antibodies (not all tests need to be done to make a diagnosis). For rare type 1 tumors that are greater than 2 cm, the workup should include multiphasic CT or MRI of the abdomen performed with contrast. Type 2 tumors are rare and occur in the setting of gastrinoma in which elevated gastrin levels produce gastric neuroendocrine hyperplasia and multifocal gastric NETs. A SEER-based analysis of 3523 patients with gastric neuroendocrine neoplasms found a 5-year OS rate of 53.7%.⁸¹

Endoscopic surveillance and endoscopic resection of prominent tumors is recommended for patients with locoregional type 1 gastric NETs every 2 to 3 years or as clinically indicated. For locoregional type 2 gastric NETs, the primary gastrinoma should, in general, be resected. If the primary tumor is not resected, endoscopic surveillance and endoscopic resection of prominent gastric NETs should be considered and/or octreotide or lanreotide can be given. Gastric acid hypersecretion should be managed with high-dose PPIs. Patients with non-metastatic gastric NETs and normal gastrin levels (type 3) often have more aggressive tumors and are usually treated with radical resection of the tumor and regional lymphadenectomy. For early-stage, smaller tumors, endoscopic or wedge resection can be considered if there is no evidence of regional lymphadenopathy on EUS or other imaging.⁸² Endoscopic resection should be reserved for small (<1 cm), superficial, low-grade tumors.



NCCN Guidelines Version 4.2021

Neuroendocrine and Adrenal Tumors

Thymic Neuroendocrine Tumors

The 5-year survival rate of thymic NETs is 62%.⁸³ Localized (stage I–II) and locoregional (stage III A/B) NETs in the thymus are generally treated with surgical resection without adjuvant therapy if they have been completely resected with negative margins. There are limited data on the utility of radiation with or without cytotoxic chemotherapy in patients with unresectable disease or in the setting of incomplete resection or positive margins.^{84,85} Observation may be considered for patients with incomplete resection and/or positive margins. Radiation therapy (RT) (category 3) is considered in select cases by some panel members to be an option for low-grade (typical carcinoid) tumors. If tumors are intermediate grade (atypical carcinoid), treatment with RT with or without systemic therapy should be considered given evidence that radiation and cytotoxic chemotherapy appear to have greater efficacy in tumors with higher mitotic and proliferative indices. For atypical carcinoid or intermediate disease, the data are extrapolated from small cell lung cancer recommendations. Cytotoxic chemotherapy options include cisplatin with etoposide or carboplatin with etoposide.

Bronchopulmonary Neuroendocrine Tumors

Neuroendocrine tumors are most commonly located in the lung or bronchus and account for 30.6% of NETs.⁸⁶ Surgery, including lobectomy or other anatomic resection and mediastinal node dissection or sampling, is recommended for patients with stage I, II, and IIIA bronchopulmonary tumors. If surgery is contraindicated, thermal ablation or stereotactic body RT (SBRT) is recommended. If surgery is feasible and the disease is in stage I, II, or low-grade IIIA, patients may be monitored under surveillance procedures as described (see *Surveillance of Resected Neuroendocrine Tumors of the Gastrointestinal Tract (Well-Differentiated Grade 1/2), Lung, and Thymus*, below). If the stage IIIA disease is intermediate grade, observation is an option. Cytotoxic chemotherapy (category 2B) may be considered and includes cisplatin with etoposide, carboplatin with

etoposide, or temozolomide. There are limited data on the effectiveness of adjuvant therapy in this setting. Response rates in small studies with less than 40 patients with atypical NETs found a 19% to 22% response rate when patients were treated with any chemotherapy.⁸⁷⁻⁸⁹ Otherwise, efficacy has been extrapolated from small cell lung cancer trials.⁹⁰⁻⁹²

Management of Locoregional Disease, Bronchopulmonary or Thymic Neuroendocrine Tumors

If surgical resection is not medically feasible for patients with low-grade, stage IIIA/B/C bronchopulmonary disease or stage IIIA/B thymic disease, then observation (if asymptomatic) or systemic therapy are recommended. Systemic therapy options include octreotide or lanreotide, if the patient is SSR-positive and/or has hormonal symptoms, everolimus, temozolomide with or without capecitabine, and RT. If the stage IIIA/B/C bronchopulmonary disease or stage IIIA/B thymic disease in this setting is intermediate grade (atypical carcinoid), additional treatment options from those listed above include RT in the presence or absence of concurrent systemic therapy (cisplatin/etoposide or carboplatin/etoposide), or systemic therapy alone.^{87,88,93} Observation is also an option (if asymptomatic and non-progressive).

Neuroendocrine Tumors of the Duodenum, Small Intestine, and Colon

For non-functioning, localized lesions arising in the duodenum, endoscopic resection is preferred if feasible. Transduodenal local excision with regional lymphadenectomy, and pancreatoduodenectomy are other options for primary treatment of non-metastatic duodenal NETs. If endoscopic resection was performed, follow-up upper endoscopy (EGD) should be performed as appropriate.

For patients presenting with tumors in the jejunum, ileum, or colon, surgical resection(s) of the bowel with regional lymphadenectomy is recommended. The surgical procedure should include careful examination of the entire bowel, because multiple synchronous lesions may be present.



NCCN Guidelines Version 4.2021

Neuroendocrine and Adrenal Tumors

In addition, the proximity to or involvement of the superior mesenteric artery and superior mesenteric vein should be assessed during surgery.

Appendiceal Neuroendocrine Tumors

Most appendiceal NETs are identified incidentally, during appendectomy performed for appendicitis. Most appendiceal NETs have well-differentiated histology, and for most appendiceal tumors less than or equal to 2 cm, simple appendectomy is sufficient because metastases are uncommon.^{94,95}

However, some controversy exists regarding the management of appendiceal NETs measuring less than 2 cm with more aggressive histologic features. A population-based study analyzing the SEER database found evidence that lymph node metastases can develop in some patients with appendiceal NETs 2 cm or smaller.⁹⁶ Some NCCN Member Institutions thus consider more aggressive treatment for 1- to 2-cm tumors with poor prognostic features, such as lymphovascular or mesoappendiceal invasion or atypical histologic features. In a retrospective case series that included 79 patients with appendiceal carcinoid (neuroendocrine) tumors, small-vessel invasion was a risk factor for metastases in patients with tumors less than 2 cm.⁹⁷

Patients with tumors greater than 2 cm, an incomplete resection, or positive nodes/margins are at risk for locoregional or distant metastases. These patients should be staged with abdominal/pelvic CT or MRI scans with intravenous (IV) contrast. To make an unequivocal diagnosis, SSR-based imaging may be considered if there are equivocal CT findings. If no distant disease is identified, a right hemicolectomy should be considered. Results from a systematic review and meta-analysis with 261 patients suggest that a right hemicolectomy was beneficial in appendiceal NETs greater than 2 cm.⁹⁸ Additionally, a small proportion of appendiceal NETs may also contain evidence of adenocarcinoma (ie, “adenocarcinoid” or

“goblet cell carcinoid”). These tumors should be managed according to the NCCN Guidelines for Colon Cancer (available at www.NCCN.org).

Neuroendocrine Tumors of the Rectum

An analysis of the SEER database revealed that patients with NET tumors of the rectum had the best prognosis (HR, 1.87; 95% CI, 1.76-1.98).⁸⁶ The treatment of rectal lesions is based on the size of the primary tumor. For small (<1 cm) and incidental lesions, complete endoscopic resection with negative margins may be sufficient, but for resection with indeterminate margins and low grade (G1), endoscopy at 6 to 12 months by endoscopy is recommended to assess for residual disease. If endoscopy results determine residual disease or intermediate grade after endoscopy, or if the small incidental tumors have indeterminate margins and intermediate grade (G2), the pathway for all other rectal tumors should be followed. All other rectal lesions should be staged using rectal MRI or endorectal ultrasound. If the lesion is less than or equal to 2 cm or minimally invasive (T1), endoscopic or transanal excision is recommended. Given the higher risk of invasion with larger tumors, examination under anesthesia (EUA) and/or EUS before the procedure should be considered for tumors 1 to 2 cm in size. A retrospective review found that metastases were present in 66% of 87 patients with well-differentiated rectal NETs of 11 to 19 mm.⁹⁹

Tumors larger than 2 cm or that are node positive, those with invasion of the muscularis propria (T2–T4), or those associated with lymph node metastases should be treated with low anterior resection or, in rare cases, an abdominoperineal resection.¹⁰⁰

Surveillance of Resected Neuroendocrine Tumors of the Gastrointestinal Tract (Well-Differentiated Grade 1/2), Lung, and Thymus

Surveillance of bronchopulmonary and GI NETs should include complete patient history and physical (H&P) examination and a multiphasic CT or an MRI scan with contrast (usually abdominal with or without pelvis). For patients with primary lung and thymic tumors, chest CT scans with or



NCCN Guidelines Version 4.2021

Neuroendocrine and Adrenal Tumors

without contrast are recommended. Surveillance imaging of the chest may also be considered if clinically indicated in patients with primary GI tumors. Most patients with NETs of the jejunum/ileum/colon; duodenum, rectum, and thymus; and type 3 gastric NETs with normal gastrin levels should be reevaluated 12 weeks to 12 months after resection (earlier if the patient is symptomatic). After 1-year post-resection, follow-up should occur every 12 to 24 months for up to 10 years post-resection. After 10 years, surveillance should be considered as clinically indicated. If initial scans are negative, the frequency of follow-up scans may decrease. For high-grade tumors, more frequent surveillance may be appropriate.

Relevant biochemical evaluations can also be performed based on pre-resection findings. Elevated levels of chromogranin A have been associated with recurrence.¹⁰¹⁻¹⁰³ In addition, an analysis of a large prospective database showed that chromogranin A levels elevated twice the normal limit or higher were associated with shorter survival times for patients with metastatic NETs (HR, 2.8; 95% CI, 1.9–4.0; $P < .001$).¹⁰⁴ Chromogranin A levels can be elevated in several concurrent medical conditions, including renal or hepatic insufficiency, and are also commonly elevated in the setting of concurrent PPIs. Several panelists therefore caution that rising chromogranin A levels in an asymptomatic patient with a tumor that looks stable on imaging does not necessarily indicate that a patient should be initiated on a new therapy.

5-HIAA, a metabolite of serotonin, in a 24-hour urine or plasma sample may also be considered as a biochemical marker in some cases, particularly in patients with metastatic small-intestinal NETs. A systematic review and meta-analysis revealed a predictive role of urinary 5-HIAA for mortality.¹⁰⁵ During monitoring of patients after treatment of a NET, decreasing levels of 5-HIAA indicate a response to treatment, whereas increasing or excessive concentration indicates that the treatment has not been successful. However, a patient with symptoms may still have a NET

even if the concentration of 5-HIAA is normal. Diet and a variety of drugs can affect the 5-HIAA test. Therefore, patients should be advised not to eat avocados, bananas, cantaloupe, eggplant, pineapples, plums, tomatoes, hickory nuts/pecans, plantains, kiwi, dates, grapefruit, honeydew, or walnuts for 48 hours before the start of and during urine collection. Medications that can increase 5-HIAA include acetaminophen, ephedrine, diazepam, nicotine, glyceryl guaiacolate (an ingredient found in some cough medicines), and phenobarbital.

SSR-based imaging or 18F-fluorodeoxyglucose (FDG)-PET/CT scans (for high-grade tumors) are not routinely recommended for surveillance after definitive resection, but may be indicated to assess disease location and disease burden for comparison in cases of subsequent possible recurrence.

In specific cases, follow-up recommendations for patients with resected GI NETs differ from the above general recommendations. For rectal tumors smaller than 1 cm and negative margins, prognosis is excellent and no follow-up is usually required. Follow-up endoscopies with rectal MRI or endorectal ultrasound are recommended for rectal tumors that are between 1 and 2 cm, 6 and 12 months after primary therapy, and then as clinically indicated.

For appendiceal tumors 2 cm or smaller without aggressive features, no surveillance is indicated. Patients with small, well-differentiated appendiceal NETs are at very low risk for recurrence,¹⁰⁶⁻¹⁰⁸. However, because recurrences have rarely been reported even after resection of small appendiceal tumors, any patients with symptoms of hormone hypersecretion should be more fully evaluated.

For hypergastrinemic patients with type 1 gastric NETs, follow-up endoscopies are recommended every 2 to 3 years or as clinically indicated. For hypergastrinemic patients with type 2 gastric NETs, follow-



NCCN Guidelines Version 4.2021

Neuroendocrine and Adrenal Tumors

up endoscopies should be considered. If clinically indicated, imaging studies should also be performed. Because gastrin levels remain persistently high in patients with atrophic gastritis, gastrin levels are generally uninformative in patients with type 1 gastric NETs. After baseline gastrin, the panel does not recommend following gastrin and chromogranin A levels for type 1 tumors.

Evaluation of Locoregional Advanced Disease and/or Distant Metastatic Gastrointestinal Tract (Well-Differentiated Grade 1/2), Bronchopulmonary, and Thymic Neuroendocrine Tumors

Baseline imaging recommendations for patients suspected to have distant metastatic disease include multiphase technique CT or MRI.^{109,110} The most common sites of metastases from intestinal NETs include regional/mesenteric lymph nodes, liver, and bones. When evaluating locoregional advanced and/or metastatic NETs of the GI tract, lung, and thymus, or for suspected carcinoid syndrome, abdominal/pelvic multiphase CT or MRI scans with IV contrast and chest CT scans with contrast are recommended. Chest CT scans may be performed with or without contrast when evaluating for metastases from primary tumors in other sites.

SSR-based imaging, if not already done, is recommended to assess the SSR status of locoregional advanced and/or metastatic NETs of the GI tract, lung, or thymus, if treatment with octreotide or lanreotide is being considered. Poorly differentiated bronchopulmonary or thymic tumors may have less avidity for 68Ga-DOTATATE PET/CT;¹¹¹ therefore, FDG-PET/CT or PET/MRI may be considered for NETs that are poorly differentiated or have atypical histology. If carcinoid syndrome is suspected, a cardiology consultation and echocardiogram are recommended to assess whether the patient has carcinoid heart disease, and SSR-based imaging may be considered to assess the SSR status of NETs.¹¹² The echocardiogram may include a comprehensive assessment of the right-sided and left-sided valves using two-dimensional, color-flow

and continuous wave Doppler assessment, standard assessment of right and left heart size and function, and two-dimensional and color-flow assessment of the atrial septum with an agitated saline injection if left-sided valve disease is present.¹¹³ The comprehensive assessment of the right-sided and left-sided valves has three components: 1) tricuspid valve assessment using parasternal inflow, short axis, and apical 4-chamber views; 2) pulmonary valve assessment using parasternal outflow, short axis, and apical or subcostal outflow views; and 3) left-sided valves using standard parasternal and apical views.

Twenty-four-hour urine or plasma 5-HIAA may also be considered, and then repeated over time to monitor subsequent disease progression. As previously mentioned, if carcinoid syndrome is suspected, evaluation of serotonin secretion, using a 24-hour urine or plasma collection for 5-HIAA, is recommended. Bronchial and thymic tumors may also be associated with hypersecretion of ACTH that causes the development of Cushing syndrome;¹¹⁴ therefore, if clinically indicated, patients should be screened for hypercortisolemia. If Cushing syndrome is suspected, see discussion below (see *Evaluation and Treatment of Cushing Syndrome*, below).

Management of Locoregional Advanced and/or Distant Metastatic Gastrointestinal Tract (Well-Differentiated Grade 1/2) Neuroendocrine Tumors

Somatostatin Analogs for Control of Symptoms and Tumor Growth

Patients who have metastatic NETs and carcinoid syndrome should be treated with octreotide or lanreotide.¹¹⁵ The long-acting release (LAR) formulation of octreotide is commonly used for the chronic management of symptoms in patients with carcinoid syndrome. Standard doses of octreotide LAR are 20 to 30 mg intramuscularly every 4 weeks. Dose and frequency may be further increased for symptom control as needed. Therapeutic levels are not achieved for 10 to 14 days after LAR injection. Octreotide (usually 150–250 mcg subcutaneously three times daily) can



NCCN Guidelines Version 4.2021

Neuroendocrine and Adrenal Tumors

be added to octreotide LAR for rapid relief of symptoms or for breakthrough symptoms.¹¹⁶⁻¹¹⁸

Lanreotide has a similar mechanism of action as octreotide, but is administered as a deep subcutaneous injection. Several studies have shown it to be effective at controlling symptoms of hormone secretion in patients with GI NETs, gastrinomas, or tumors secreting vasoactive intestinal polypeptide (VIPomas).¹¹⁹⁻¹²³ The multinational phase III ELECT trial randomized 115 patients with carcinoid syndrome who were either naïve to or responsive to octreotide to receive 120 mg of lanreotide or placebo and evaluated the number of days patients required use of rescue octreotide.¹²⁴ Patients in the lanreotide arm required less frequent rescue octreotide than those in the placebo arm (33.7% vs. 48.5%; $P = .017$). Overall, lanreotide treatment improved symptom control, irrespective of prior octreotide use.^{124,125}

If carcinoid syndrome is poorly controlled, telotristat may be considered for persistent symptoms (eg, diarrhea), after ruling out non-carcinoid syndrome causes. Patients should be evaluated for pancreatic exocrine deficiency and bile acid diarrhea. Telotristat or telotristat ethyl is a small-molecule tryptophan hydroxylase (TPH) inhibitor, which decreases urinary 5-HIAA levels and the frequency of bowel movements (BMs) in patients with carcinoid syndrome.^{126,127} It was approved by the FDA in February 2017 and the recommendation to use telotristat for persistent diarrhea in this context is based on the results of the TELESTAR study. The TELESTAR study was a multicenter, randomized, double-blind, placebo-controlled phase III trial of 135 patients with metastatic NETs and a documented history of carcinoid syndrome, who were experiencing an average of 4 or more BMs a day while receiving stable-dose somatostatin analog therapy for at least 3 months prior to enrollment in the study.¹²⁸ Patients were randomized to receive placebo, telotristat ethyl (250 mg), or telotristat ethyl (500 mg) in a 1:1:1 ratio three times per day orally for 12

weeks during a double-blind treatment period. From baseline to week 12, mean BM frequency reductions per day for placebo, telotristat ethyl (250 mg), and telotristat ethyl (500 mg) were -0.9, -1.7, and -2.1, respectively. In addition, both telotristat dosages significantly decreased mean urinary 5-HIAA compared to placebo at week 12 ($P < .001$).¹²⁸ Compared to placebo, treatment with telotristat at either dosage did not result in a statistically significant change in the number of observed flushing episodes;¹²⁸ therefore, additional options should be considered to manage other symptoms associated with carcinoid syndrome. In the TELEPRO real-world study, patients given telotristat ethyl had a decrease in diarrhea and other carcinoid syndrome symptoms.¹²⁹ Additional therapies that may be considered to achieve disease control are hepatic arterial embolization, cytoreductive surgery for liver-predominant disease, or other systemic therapy based on disease site.

During treatment for carcinoid syndrome, a cardiology consultation and echocardiogram to assess whether the patient has carcinoid heart disease should also be performed every 2 to 3 years,¹¹⁵ or as clinically indicated. Cardiac heart disease is frequent in patients with carcinoid syndrome; in one study, 59% of patients with carcinoid syndrome were diagnosed with tricuspid regurgitation.^{130,131} A study of 250 patients with carcinoid syndrome showed that patients with 5-HIAA levels of 300 μmol or greater (57 mg) over 24 hours and with 3 or more flushing episodes per day were more likely to have carcinoid heart disease.¹³² To monitor disease control and/or progression, surveillance imaging of the abdomen and pelvis using multiphasic CT or MRI every 12 weeks to 12 months and chest CT scans with or without contrast should be performed as clinically indicated.

In patients with GI tract primary tumors who have clinically significant tumor burden or progressive disease, initiation of either octreotide LAR or lanreotide is recommended to potentially control tumor growth if they are not already receiving it. The recommendation to consider octreotide LAR



NCCN Guidelines Version 4.2021

Neuroendocrine and Adrenal Tumors

in these patients is based on the results of the PROMID study, a placebo-controlled phase III trial of 85 patients with metastatic midgut NETs (proliferative index, Ki-67, up to 2%), which showed median times to tumor progression of 14.3 and 6 months in the octreotide LAR and placebo groups, respectively ($P = .000072$).¹³³ After 6 months of treatment, stable disease was observed in 66.7% of patients in the octreotide LAR group and in 37.2% of patients in the placebo group. Results of long-term survival of patients in the PROMID study¹³⁴ found that median OS was not significantly different between the arms (83.7 months in the placebo arm and 84.7 months in the octreotide arm; HR, 0.83; 95% CI, 0.44–1.46; $P = .51$).¹³⁵ However, post-study treatment included octreotide LAR in 38 of 43 patients in the placebo arm, possibly confounding interpretation of long-term survival results.

The recommendation that lanreotide be considered for control of tumor growth in patients with clinically significant tumor burden or progressive disease is based on results of the CLARINET study. The CLARINET study randomized 204 patients with locally advanced or metastatic nonfunctioning pancreatic or intestinal NETs (proliferative index, Ki-67, up to 10%) to receive either lanreotide or placebo and followed patients for PFS. Results from this trial showed that treatment with lanreotide for 2 years resulted in an improvement in PFS over placebo (PFS, not reached vs. 18 months; HR, 0.47; 95% CI, 0.30–0.73; $P < .001$).¹³⁶ Subsequent data from a pre-planned interim analysis of the open-label extension of the CLARINET study estimated PFS in patients treated with lanreotide at 32.8 months (95% CI, 30.9–68.0).¹³⁷ The difference in the reported median PFS between the PROMID and CLARINET studies is likely explained by a difference in the study populations, as the majority of the patients enrolled in the CLARINET trial had stable disease in the 3 to 6 months before randomization.¹³⁶ The long-term efficacy and safety of lanreotide was demonstrated in a 48-week phase II trial with Japanese patients with

NETs.¹³⁸ Stable disease was observed in 71.4% of patients while progressive disease was observed in 21.4% of patients.

Patients with clinically significant progression of metastatic bronchopulmonary and GI NETs can pursue several other options, as discussed below.

Resection of Metastatic Disease

In some cases, patients with limited hepatic metastases or other sites of disease can undergo complete resection of the primary tumor and metastases with curative intent. One study of 172 patients who underwent hepatic resection of metastatic NETs showed that long-term survival can be achieved in selected cases: the reported 10-year OS rate was 50.4%.¹³⁹ A systematic review reported 5-year OS rates ranging from 41% to 100% in patients undergoing hepatic resection.¹⁴⁰ Most patients with resected metastatic disease, however, will eventually experience recurrence.^{141,142} Noncurative debulking surgery can also be considered in select cases, especially if the patient is symptomatic either from tumor bulk or hormone production.

Resection of the primary site in the setting of unresectable metastases is generally not indicated if the primary site remains asymptomatic and is relatively stable.¹⁴⁰ However, taking a careful history is recommended as surgery may be an option for asymptomatic patients with previous, intermittent obstructions. A retrospective study did not find a survival improvement of resecting asymptomatic primary small bowel tumors.¹⁴³ However, it is not uncommon for patients with small bowel primary tumors to experience symptoms of intermittent abdominal pain from episodic bowel obstruction or bowel ischemia related to the primary tumor and surrounding fibrosis. Palliative small bowel resection is recommended in these patients.



NCCN Guidelines Version 4.2021

Neuroendocrine and Adrenal Tumors

If resection is performed and future treatment with octreotide or lanreotide is anticipated, a prophylactic cholecystectomy can be considered given the association between long-term treatment with somatostatin analogs and the development of biliary symptoms and gallstones.¹¹⁵

Liver-Directed Therapies for Metastatic Neuroendocrine Tumors of the Gastrointestinal Tract (Well-Differentiated Grade 1/2)

For patients with locoregional advanced, liver-predominant, progressive disease or patients with poorly controlled carcinoid syndrome, liver-directed therapies are recommended, mainly with the palliative goals of extending life and relieving hormonal symptoms.¹⁴⁴⁻¹⁴⁷

Cytoreductive surgery or ablative therapies such as radiofrequency ablation (RFA) or cryoablation may be considered if near-complete treatment of tumor burden can be achieved (category 2B).¹⁴⁸⁻¹⁵² Ablative therapy in this setting is non-curative. Data on the use of these interventions are emerging. For unresectable liver metastases, hepatic regional therapy (arterial embolization,¹⁵³ chemoembolization,¹⁵⁴⁻¹⁵⁶ or radioembolization [category 2B])¹⁵⁶⁻¹⁶⁰ is recommended. No single modality of embolization therapy has been shown to be superior to another, but there is a difference in both long-term and short-term toxicities among the different modalities. Palliative RT is recommended for symptomatic bone metastases.

Everolimus for Advanced Neuroendocrine Tumors of the Gastrointestinal Tract (Well-Differentiated Grade 1/2), Lung, and Thymus

For patients with progressive metastatic GI tract NETs or intermediate grade (atypical carcinoid) bronchopulmonary NETs, everolimus (category 1 for bronchopulmonary NET) is a recommended treatment option. However, the safety and effectiveness of everolimus in the treatment of patients with carcinoid syndrome have not been established. Everolimus is an inhibitor of mTOR and was well tolerated and showed evidence of antitumor effect in patients with advanced NETs when given with

octreotide LAR in a phase II trial.¹⁶¹ In the randomized phase III RADIANT-2 trial, 429 patients with advanced NETs and carcinoid syndrome were randomized to receive octreotide LAR with everolimus or placebo.¹⁶² Based on central review, patients receiving octreotide plus everolimus had a median PFS of 16.4 months, compared with 11.3 months for patients receiving octreotide alone ($P = .026$). This difference in the primary endpoint of PFS did not, however, meet the predefined threshold for statistical significance. An open-label extension of the RADIANT-2 trial allowed patients who had progressed or completed the double-blind core phase to take everolimus plus octreotide LAR. The median OS was not statistically different for patients receiving everolimus plus octreotide LAR (29.2 months) or placebo plus octreotide LAR (during the open-label extension; 35.2 months) at the final cutoff date.¹⁶³ Adverse events associated with everolimus included stomatitis, rash, fatigue, and diarrhea.^{162,163} Other side effects have also been described.¹⁶⁴⁻¹⁶⁶

A subsequent trial, RADIANT-4, was an international, double-blind, placebo-controlled, phase 3 trial that randomized 302 patients with progressive, non-functional lung or GI NETs 2:1 to receive everolimus or placebo.¹⁶⁷ In contrast to RADIANT-2, patients in RADIANT-4 were not receiving a somatostatin analog at the time of study enrollment and concurrent somatostatin analog was not a study requirement. Median PFS was 11.0 months (95% CI, 9.2–13.3) in the everolimus arm and 3.9 months (95% CI, 3.6–7.4) in the placebo arm. The hazard ratio for progression or death was 0.48 (95% CI, 0.35–0.67; $P < .001$). Drug-related grade 3/4 adverse events included stomatitis (9% vs. 0%), infections (7% vs. 0%), diarrhea (7% vs. 2%), anemia (4% vs. 1%), fatigue (3% vs. 1%), and hyperglycemia (3% vs. 0%). A real-world report highlights the outcomes of 169 pretreated patients with advanced NETs of the pancreas ($n = 85$) or other sites ($n = 84$) who received everolimus through a compassionate use program.¹⁶⁸ An increased risk of adverse events in patients who had received previous radiolabeled peptide therapy



NCCN Guidelines Version 4.2021

Neuroendocrine and Adrenal Tumors

or chemotherapy was noted. An exploratory analysis of a subgroup of patients with advanced, progressive, well-differentiated, non-functional lung NETs from RADIANT-4 reported improved PFS by central review (HR, 0.50; 95% CI, 0.28–0.88) in the everolimus arm (9.2 months) compared to the placebo arm (3.6 months).¹⁶⁹ Additionally, a secondary endpoint analysis of RADIANT-4 found that health-related quality-of-life outcomes were maintained in patients receiving everolimus and placebo, with no significant difference between them.¹⁷⁰

Systemic Therapy for Advanced Neuroendocrine Tumors of the Gastrointestinal Tract (Well-Differentiated Grade 1/2), Lung, and Thymus

Cytotoxic chemotherapy: The benefits associated with cytotoxic chemotherapy in patients with advanced NETs appear, at best, to be modest. Tumor response rates are generally low, and no PFS benefit has been clearly demonstrated.¹⁷¹

Capecitabine was tested in patients with metastatic carcinoid (neuroendocrine) tumors in a phase II trial; no objective responses were reported, although 13 of 19 patients were reported to have experienced stable disease.¹⁷² The combination of capecitabine and oxaliplatin was assessed in a phase II study, with response rates of 23% in patients with poorly differentiated NETs and 30% in well-differentiated disease.¹⁷³ 5-fluorouracil (5-FU) was assessed in the phase III E1281 trial in combination with streptozocin or doxorubicin.¹⁷⁴ Response rates in both arms were around 16%. Dacarbazine was given following progression, with a response rate of 8%. Responses to temozolomide in advanced NETs are rare.¹⁷⁵

A phase II trial assessed bevacizumab plus capecitabine and included 49 patients with advanced and/or metastatic GI NETs.¹⁷⁶ A PFS of 23.4 months was reported, with 18% of patients achieving a partial response and 70% achieving stable disease. Similar results were seen in 2 small trials of FOLFOX (fluorouracil, leucovorin, oxaliplatin) and CAPEOX

(capecitabine, oxaliplatin) combined with bevacizumab where a PFS of 19.3 months and 16.7 months, respectively, was reported.¹⁷⁷ However, these findings have not been confirmed in phase III studies.

The panel lists cytotoxic chemotherapy (namely 5-FU, capecitabine, dacarbazine, oxaliplatin, streptozocin, and temozolomide) for progressive NETs of the GI tract as a category 3 recommendation. While some panelists believe the toxicity of systemic therapy does not warrant its widespread use in this population, others believe that it is an important alternative for patients without other options for treatment. For patients with clinically significant bronchopulmonary or thymic tumor burden that is low or intermediate grade, temozolomide either administered alone or in combination with octreotide or lanreotide is an option to manage tumor burden and any associated symptoms.^{87,178} In a retrospective study of 31 patients with progressive metastatic bronchial NETs, temozolomide monotherapy was associated with partial responses in 14% of patients.¹⁷⁸ A small retrospective study examined the combination of temozolomide and capecitabine in patients with advanced lung NETs. The results showed an objective response rate (ORR) of 30%, with a median OS of 68 months (95% CI, 35.3 months–100.7 months) and a median PFS of 13 months (95% CI, 4.4 months–21.6 months).¹⁷⁹ Another study comprising 33 patients with advanced pulmonary carcinoids treated with temozolomide and capecitabine reported a median OS of 30.4 months and a median PFS of 9.0 months.¹⁸⁰

Radiolabeled Somatostatin Analogs for Advanced Neuroendocrine Tumors of the Gastrointestinal Tract (Well-Differentiated Grade 1/2), Lung, and Thymus

Several early studies initially reported that treatment with radiolabeled somatostatin analogs was associated with tumor responses in patients with advanced NETs.^{181–185} A prospective phase II study of radiopeptide therapy in 90 patients with metastatic NETs refractory to octreotide showed that treatment was associated with improvement in symptoms;



NCCN Guidelines Version 4.2021

Neuroendocrine and Adrenal Tumors

radiographic regression, however, was relatively uncommon.¹⁸⁶ Numerous large, non-randomized cohort analyses have also reported encouraging survival rates with this approach.¹⁸⁷⁻¹⁸⁹

A recent phase III study, NETTER-1, randomized 229 patients with advanced midgut NETs to receive treatment with either 177Lu-dotatate or high-dose octreotide. Results of this study showed that treatment with 177Lu-dotatate was associated with a significant improvement in PFS (not reached vs. 8.4 months; $P < .0001$).¹⁹⁰ Objective tumor responses were observed in 18% of patients who received 177Lu-dotatate versus 3% in the control group ($P < .001$). Another recent study examined the long-term efficacy, survival, and toxicity of 177Lu-dotatate in a group of 610 Dutch patients with metastatic gastroenteropancreatic and bronchial NETs.¹⁹¹ PFS and OS for all patients were 29 months [95% CI, 26–33 months] and 63 months (95% CI, 55–72 months), respectively.¹⁹¹ Other smaller studies also found improved OS (58.8 months, $n = 114$)¹⁹² and median PFS (20.1 months with typical disease and 15.7 months with atypical disease; $n = 34$)¹⁹³ with peptide receptor radionuclide therapy (PRRT) treatment in patients with advanced bronchopulmonary NETs.

PRRT with 177Lu-dotatate was approved by the FDA in January 2018 for the treatment of adult patients with unresectable, low- or intermediate-grade, locally advanced or metastatic gastroenteropancreatic NETs.¹⁹⁴ A meta-analysis of 18 studies with 1920 patients with unresectable metastatic NETs treated with 177Lu-dotatate PRRT found a pooled disease response rate of 29% to 31% and a combined disease control rate of 74% to 81%.¹⁹⁵ NCCN recommends considering PRRT with 177Lu-dotatate as a treatment option for some patients with advanced and/or metastatic GI tract, bronchopulmonary, and thymic NETs that are SSR-positive with imaging. Treatment with 177Lu-dotatate is recommended for patients with unresectable GI NETs that have progressed if there was SSR-positive imaging and progression on octreotide and lanreotide

(category 1 for mid-gut tumors). Treatment with 177Lu-dotatate is also recommended for patients with bronchopulmonary or thymic NETs, SSR-positive imaging, and disease progression while taking octreotide or lanreotide, if the tumor is either low grade (typical) with clinically significant tumor burden, or intermediate grade (atypical). Please see *Principles of Peptide Receptor Radionuclide Therapy (PRRT) with 177Lu-dotatate* in the algorithm for practical guidance and information, including patient eligibility, patient preparation for treatment, dose and administration of 177Lu-dotatate, post-treatment instructions, and timing of somatostatin analogues.

For patients with locoregional advanced disease and/or distant metastases of the GI tract, following progression on octreotide or lanreotide, everolimus and PRRT with 177Lu-dotatate are preferred regimens while the cytotoxic chemotherapy regimens listed above are “useful in certain circumstances.”

Use of Somatostatin Analogs with 177Lu-dotatate

Most patients treated with PRRT will have progressed on first-line somatostatin analog treatment. Patients with hormonally functional tumors should continue octreotide or lanreotide along with 177Lu-dotatate. It is unclear whether patients with nonfunctional tumors benefit from continuation of somatostatin analog treatment during and after 177Lu-dotatate treatment. A recent study looked at whether 68Ga-DOTATATE uptake before or after long-acting somatostatin analog treatment was affected in patients with NETs and found that the uptake in the primary tumor and metastatic sites were not compromised.⁷⁷ However, there are still theoretical concerns regarding the competition between somatostatin analogs and 177Lu-dotatate for SSR binding. Somatostatin analog treatment interruption may not be necessary, but the panel recommends the following adjustments. Concomitant use of long-acting somatostatin analogs such as lanreotide and octreotide is not recommended in the 4 to



NCCN Guidelines Version 4.2021

Neuroendocrine and Adrenal Tumors

6 weeks prior to each treatment with ¹⁷⁷Lu-dotatate. Additionally, short-acting somatostatin analogs should be stopped 24 hours before each ¹⁷⁷Lu-dotatate treatment. Somatostatin analogs (short- and long-acting) can be resumed 4 to 24 hours after each ¹⁷⁷Lu-dotatate treatment. IV infusion of amino acids is a critical part of ¹⁷⁷Lu-dotatate therapy for nephroprotection.

Liver Transplantation Considered Investigational for Liver Metastases of Neuroendocrine Tumors of the Gastrointestinal Tract (Well-Differentiated Grade 1/2)

Several series have now reported the results of liver transplantation patients with carcinoid tumors whose metastases are confined to the liver.¹⁹⁶⁻²⁰¹ Results from a multicenter database of 85 patients at 28 centers who underwent liver transplantation for NETs were also reported.²⁰² A meta-analysis showed that, while 5-year survival rates are encouraging, the majority of patients undergoing liver transplantation ultimately develop recurrence.²⁰³ The panel acknowledged the considerable associated risks and deemed liver transplantation to be investigational and not part of routine care at this time.

Management of Distant Metastatic Bronchopulmonary or Thymic Neuroendocrine Tumors

Lung NETs include a spectrum from low-grade typical NETs to intermediate-grade atypical NETs.²⁰⁴ If patients present with asymptomatic, low tumor burden that is low grade (typical carcinoid), they can be observed with chest CT scans with contrast and abdominal/pelvic multiphasic CT or MRI scans every 3 to 6 months. Alternatively, these patients can be treated with octreotide and lanreotide (if the patient is SSR-positive and/or has hormonal symptoms). No clear consensus exists on the timing of octreotide or lanreotide initiation in asymptomatic patients with metastatic NETs and low tumor burden. Although initiation of octreotide or lanreotide is an option in these patients, deferring initiation until evidence of tumor progression is seen may also be appropriate in

selected patients. The phase 3 RADIANT-2 trial included 44/429 patients with lung NETs and only nine of these were atypical carcinoids.⁸⁹ However, this study did not stratify according to the type of tumor; 33 patients received octreotide LAR + everolimus and 11 patients received octreotide LAR + placebo. As with GI primary tumors above, there is no clear consensus on the timing of initiation of octreotide or lanreotide in such patients and either approach may be appropriate in selected patients.

A clinical trial is preferred for patients with clinically significant tumor burden and low grade (typical carcinoid) disease, evidence of disease progression, intermediate grade (atypical carcinoid) disease, or symptomatic disease. Observation can be considered if asymptomatic or for tumors on the lower end of the proliferative index-defined spectrum. Treatment options include initiation of octreotide or lanreotide, if the patient is SSR-positive and/or has hormonal symptoms. Additional options include initiation of everolimus (based on the results of the RADIANT 4 study, described above) (category 1 for bronchopulmonary NET with distant metastases), PRRT with ¹⁷⁷Lu-dotatate (if the patient is SSR-positive and progresses on octreotide and lanreotide), and liver-directed therapy for liver-predominant disease. Cisplatin/etoposide, carboplatin/etoposide, or temozolomide,¹⁷⁸ with or without capecitabine,^{179,180} can be considered for intermediate grade (atypical tumors) with Ki-67 proliferative index and mitotic index in the higher end of the defined spectrum.⁸⁷ For symptom control, the addition of focal therapy, such as endobronchial therapy debulking or ablation, can be considered. A clinical trial, everolimus, octreotide, and lanreotide are preferred treatment options while PRRT with ¹⁷⁷Lu-dotatate and the chemotherapy regimens are listed as “useful in certain circumstances.”

Although rare, some patients may present with multiple lung nodules or tumorlets and widespread peripheral airway neuroendocrine cell



NCCN Guidelines Version 4.2021

Neuroendocrine and Adrenal Tumors

hyperplasia. In this case, a diagnosis of diffuse idiopathic pulmonary neuroendocrine cell hyperplasia (DIPNECH) can be made.²⁰⁴ This condition is generally indolent, and patients can be observed with chest CT scans without contrast every 12 to 24 months or as clinically indicated. If patients are symptomatic, treatment with octreotide or lanreotide (if SSR-positive and/or chronic cough/dyspnea is not responsive to inhalers) is recommended.

Neuroendocrine Tumors of the Pancreas (Well-Differentiated Grade 1/2)

According to a population-based study, malignant pancreatic NETs account for approximately 1% of pancreatic cancers by incidence and 10% of pancreatic cancers by prevalence.²⁰⁵ Although the peak incidence of occurrence is between ages 40 and 69 years, a significant number of patients diagnosed with pancreatic NETs are younger than 35 years.^{205,206} Based on an analysis of pancreatic NETs in the SEER database from 1973 to 2000, the annual incidence per 1 million was 1.8 in women and 2.6 in men.⁵¹ An estimated 40% to 91% of pancreatic NETs are nonfunctional. The remainder manifest with clinically evident hormonal symptoms.^{12,51} Consistent with these numbers, analysis of the NCCN NETs Outcomes Database found that 22% of patients with pancreatic NETs have a hormonal syndrome.⁶⁵ Of these functioning tumors, up to 70% are insulinomas, and only 10% are associated with metastases. Approximately 15% are glucagonomas. Gastrinomas and somatostatinomas account for another 10%; gastrinomas and somatostatinomas (80%–90%) are associated with a relatively high risk for metastases.²⁰⁶ The remaining rare pancreatic NETs include VIPoma and cholecystokinin-producing tumors.²⁰⁷

Pancreatic NETs occurring in patients with MEN1 are typically multiple and require different treatment strategies from those used for patients with sporadic pancreatic NETs, which are usually solitary (see MEN1,

below). Gastrinoma and insulinoma are the most common pancreatic NETs in patients with MEN1.²⁰⁸

Evaluation of Neuroendocrine Tumors of the Pancreas (Well-Differentiated Grade 1/2)

The recommended evaluation also includes an abdominal multiphasic CT or MRI scan (with or without pelvis). A chest CT scan with or without contrast may be included as appropriate. SSR-based imaging and EUS can also be considered if additional imaging is needed.²⁰⁹ Consideration of genetic counseling and testing for inherited genetic syndromes is recommended for all patients with pancreatic NETs. Personal and family history should also be evaluated in patients with pancreatic NETs for the possibility of MEN1 (see *Multiple Endocrine Neoplasia*, below) or other hereditary syndromes as appropriate.

Hormone-secreting tumors, even when very small, may result in significant clinical symptoms, and lesion identification can be difficult.²¹⁰ These cases often require additional imaging, such as EUS and somatostatin scintigraphy.

Because many pancreatic NETs secrete hormones, biochemical evaluation should also be considered in patients with pancreatic NETs.²⁰⁶ Biochemical evaluation is generally guided by the presence of symptoms that might indicate excess hormone secretion. Screening for hormones in asymptomatic individuals is not routinely recommended. However, chromogranin A is non-specific and is often elevated in all NETs. The range of symptoms associated with hormonal secretion is diverse. Classic syndromes include those associated with insulinomas, which secrete insulin, resulting in fasting or nocturnal hypoglycemia. Gastrinomas secrete gastrin, and patients often present with recurrent peptic ulcers. Glucagonomas are associated with the development of hyperglycemia or diabetes mellitus and/or migratory necrolytic erythema. Patients with somatostatinomas may also present with hyperglycemia or diabetes



NCCN Guidelines Version 4.2021

Neuroendocrine and Adrenal Tumors

mellitus and/or diarrhea/steatorrhea. VIPomas are characterized by watery diarrhea, hypokalemia, and achlorhydria (WDHA syndrome) from secretion of VIP. The guidelines describe appropriate tests for each of these situations. Non-functioning tumors are not accompanied by any symptoms or hormone secretion, but often have elevated pancreatic polypeptide (PP; category 3) and chromogranin A. PP has more utility than chromogranin A and can be useful in a prognostic setting but test results alone should not be used to guide treatment decisions.

Chromogranin A levels are elevated in 60% or more of patients with either functioning or nonfunctioning pancreatic endocrine tumors.²¹¹⁻²¹³ In addition, analysis of a large prospective database found that chromogranin A levels elevated twice the normal limit or higher were associated with shorter survival times for patients with metastatic NETs (HR, 2.8; 95% CI, 1.9–4.0; $P < .001$).¹⁰⁴ Chromogranin A was also found to be a prognostic factor in a prospective study of patients treated with everolimus.²¹⁴ Care should be taken in measuring chromogranin A and interpreting the results, because spuriously elevated levels of chromogranin A have been reported in patients using PPIs, those with renal or liver failure, those with hypertension, and those with chronic gastritis.

Evaluation of Gastrinomas

Gastrinoma should be suspected in patients with severe and refractory gastroduodenal ulcers or symptoms such as dyspepsia, usually accompanied by diarrhea. Evaluation of a patient with suspected gastrinoma includes measurement of serum gastrin levels.²¹⁵ Diagnosis of gastrinoma can be confounded by the concurrent use of PPIs, which will elevate serum gastrin levels. Importantly, most patients who are found to have an elevated level of serum gastrin do not have a gastrinoma but have achlorhydria or are receiving PPIs or antacids. To confirm diagnosis, gastrin levels must be measured after the patient is off PPI therapy for at least 1 week.²¹⁶

Imaging with abdominal multiphasic CT/MRI scan (with or without pelvis) with IV contrast is recommended. Other tests, such as SSR-based imaging, chest CT scan with or without contrast, EUS, and other biochemical tests may be performed as appropriate. Approximately 70% of patients with MEN1 and gastrinoma have tumors situated in the duodenum.

Evaluation of Insulinomas

Insulinomas should be suspected in people who have hypoglycemia (generally fasting or nocturnal) and a pancreatic mass. However, some insulinomas can be small and not visible on imaging and so should be suspected in persons presenting with hypoglycemia. Evaluation with a 72-hour fast, which tests serum insulin, pro-insulin, and C-peptide during concurrent hypoglycemia, is the gold standard.²¹⁷ An insulin level greater than 3 mIU/mL (usually >6 mIU/mL), C-peptide concentrations of at least 0.6 ng/mL, and proinsulin levels of greater than or equal to 5 pmol/L when fasting blood glucose is less than 55 mg/dL is suspicious for insulinoma.²¹⁷ Other biochemical tests may be performed as appropriate. Other causes of hypoglycemia, such as adrenal insufficiency and malnutrition, and other causes of non–insulin-mediated hypoglycemia should be ruled out prior to performing a 72-hour fast. The *Endocrine Society Guidelines on Hypoglycemia* have details regarding the general workup for hypoglycemia.²¹⁷

Imaging with abdominal, with or without pelvis, multiphasic CT with contrast or MRI is recommended to localize insulinomas. Some insulinomas are too small to be imaged with CT or MRI, and in those cases EUS can be useful. If imaging is negative, then insulinomas can often be localized by injecting calcium into selective pancreatic arteries and measuring the insulin levels in the right (usually) or left hepatic vein (Imamura-Doppman procedure).²¹⁸ Most experts recommend this test only



NCCN Guidelines Version 4.2021

Neuroendocrine and Adrenal Tumors

for patients with persistent or recurrent insulin-mediated hypoglycemia and when other localization tests are equivocal or negative.

Ninety percent of insulinomas pursue an indolent course and can be cured surgically. To rule out metastatic disease, chest CT scans with or without contrast and SSR-based imaging can also be done. However, insulinomas are less consistently octreotide-avid than other pancreatic NETs, and SSR-based imaging may consequently be less useful as an imaging technique in insulinomas than in other tumor subtypes. SSR-based imaging should be performed if octreotide or lanreotide is being considered as a treatment for metastatic disease. Octreotide or lanreotide should only be administered to patients whose tumors are SSR-positive. Patients with insulinoma should be carefully monitored when receiving octreotide or lanreotide because in some cases these drugs can profoundly worsen hypoglycemia (see *Preoperative Management*, below).²¹⁹

Evaluation of Glucagonomas and VIPomas

For patients with recent-onset diabetes, cachexia, and/or a necrolytic erythematous skin rash and a pancreatic mass, the panel recommends a blood test for glucagon and blood glucose. For suspected VIPomas with characteristic watery diarrhea, testing for VIP and electrolytes is recommended. For both glucagonomas and VIPomas, abdominal, with or without pelvis, multiphase contrast-enhanced CT or MRI scans with IV contrast is recommended to identify the primary tumors. Chest CT scans with or without contrast can be performed. SSR-based imaging and EUS can be performed as appropriate if the tumor is not able to be localized or there is concern for metastatic disease. Genetic counseling and testing for inherited genetic syndromes should be considered.

Primary Treatment of Locoregional Resectable Neuroendocrine Tumors of the Pancreas (Well-Differentiated Grade 1/2)

Resection is the primary treatment approach for localized pancreatic NETs when possible, and can result in excellent outcomes. Exceptions to surgery include patients with other life-limiting comorbidities or high surgical risk, particularly if tumors are small and indolent.

Preoperative Management

Surgical resection is the optimal treatment for locoregional pancreatic endocrine tumors. Before excision, however, any symptoms of hormonal excess must be treated. Octreotide or lanreotide can be used for symptom control in most pancreatic NET subtypes.¹¹⁵ Octreotide or lanreotide should be used with caution in patients with insulinoma, because they can also suppress counterregulatory hormones such as growth hormone, glucagon, and catecholamines. In this situation, octreotide and lanreotide can precipitously worsen hypoglycemia and can result in fatal complications.²¹⁹ Octreotide and lanreotide should not be used in patients with insulinoma who have a negative result by SSR-based imaging.

In addition, specific measures are often recommended based on symptoms. For insulinomas, it is important to stabilize glucose levels with diet and/or diazoxide and/or everolimus. For gastrinomas, gastrin hypersecretion may be treated with high-dose PPIs. For patients with glucagonoma, treatment of hyperglycemia and diabetes is necessary, especially to control blood sugars prior to surgery. All patients who might require splenectomy should receive preoperative trivalent vaccine (ie, pneumococcus, *haemophilus influenzae b*, meningococcal group c).

Surgical Management of Non-functioning Pancreatic Neuroendocrine Tumors (Well-Differentiated Grade 1/2)

Most patients with localized pancreatic NETs should undergo surgical resection, absent any contraindications. Exceptions include patients with other life-limiting comorbidities, high surgical risk, or widely metastatic



NCCN Guidelines Version 4.2021

Neuroendocrine and Adrenal Tumors

disease. Additionally, several studies have suggested that patients with incidentally discovered tumors less than 1 cm in size may be safely followed in some cases, depending on the site of the tumor.^{220,221} Other studies, including an analysis of the SEER database, suggest that some small tumors (measuring <2 cm in size in these studies) can pursue a more aggressive course.²²²⁻²²⁴ Other retrospective studies suggest that nonoperative management can be safe for nonfunctioning pancreatic NETs less than 1.7 cm or less than 3 cm.^{225,226} Based on these limited data, the panel includes observation alone as a recommended option for selected cases of incidentally discovered, small (≤ 2 cm), low-grade non-functional pancreatic NETs. Other recommended options include enucleation or resection, with or without regional lymphadenectomy. As appropriate, central pancreatectomy or spleen-preserving surgery should be considered.

The panel recommends surgical resection for larger tumors absent contraindications. Resection for larger (>2 cm), node-positive, or malignant-appearing nonfunctional tumors should include total removal of the tumor with negative margins (including adjacent organs). Regional lymphadenectomy should also be performed. As appropriate, central pancreatectomy or spleen-preserving surgery should be considered. Serial imaging is recommended and lymph node resection should also be considered for tumors of 1 to 2 cm, because there is a small but real risk of lymph node metastases.^{227,228} MRI over CT should be considered to minimize radiation risks.

Surgical Management of Gastrinomas

The treatment approach for gastrinoma usually depends on the results of preoperative localization studies and on findings during exploratory laparotomy. In patients with occult gastrinoma (ie, no primary tumor or metastasis is seen on imaging), the panel recommends either observation or exploratory surgery, including duodenotomy and intraoperative

ultrasound with enucleation or local resection of tumors if identified at operation, and removal of periduodenal nodes.

Gastrinomas in the duodenum are treated with duodenotomy and intraoperative ultrasound with local resection or enucleation of tumors and periduodenal node dissection.

Gastrinomas in the head of the pancreas that are exophytic or peripheral as determined by imaging and are not immediately adjacent to the pancreatic duct should be enucleated. The periduodenal nodes should also be removed. Gastrinomas in the pancreatic head that are deeper or invasive and those with proximity to the main pancreatic duct should be managed with pancreatoduodenectomy.

Gastrinomas in the distal pancreas are treated with distal pancreatectomy and splenectomy. Gastrinomas in some cases may be associated with lymph node metastases,²²⁹ which are removed with splenectomy.

Surgical Management of Insulinomas

The primary treatment for exophytic or peripheral insulinomas, because they are primarily benign, is enucleation. Sporadic tumors are usually solitary, whereas familial tumors are multiple. If enucleation is not possible because of invasion or tumor location within the pancreas, then pancreatoduodenectomy for tumors in the head of the pancreas or distal pancreatectomy with preservation of the spleen for smaller tumors not involving splenic vessels may be performed. A minimally invasive resection can be considered. A meta-analysis reported that laparoscopic procedures are safe for patients with insulinomas and may be associated with shorter hospital stays.²³⁰

Surgical Management of Glucagonomas

Most glucagonomas are malignant and calcified and located in the tail of the pancreas, with regional node involvement. The recommended



NCCN Guidelines Version 4.2021

Neuroendocrine and Adrenal Tumors

treatment is distal pancreatectomy with splenectomy and resection of the peripancreatic lymph nodes. For tumors in the pancreatic head, pancreatoduodenectomy with resection of the peripancreatic lymph nodes is recommended. Small (<2 cm) peripheral glucagonomas are rare; enucleation or local excision with peripancreatic lymph dissection may be considered for small peripheral tumors of the head or distal pancreas. A hypercoagulable state has been reported in 10% to 33% of patients with glucagonoma.^{231,232} Therefore, perioperative anticoagulation can be considered because of the increased risk of pulmonary emboli.

Surgical Management of VIPomas

Distal VIPomas are treated with distal pancreatectomy with resection of peripancreatic lymph nodes and with or without splenectomy. Pancreatoduodenectomy with dissection of peripancreatic nodes is recommended for tumors in the head of the pancreas. Small (<2 cm) peripheral VIPomas are rare; enucleation or local excision with peripancreatic lymph dissection may be considered for small peripheral tumors of the head or distal pancreas.

Surgical Management of Other Pancreatic Neuroendocrine Tumors (Well-Differentiated Grade 1/2)

The treatment recommendations for tumors secreting hormones such as somatostatinoma, ACTH, parathyroid hormone-related peptide (PTHrP), and PP are similar to those for nonfunctioning tumors. Tumors that are small (<2 cm) and peripheral can be enucleated or resected, with or without regional lymphadenectomy. Deeper, larger (>2 cm), or invasive tumors are treated with pancreatoduodenectomy if they are located in the head of the pancreas, and with distal pancreatectomy and splenectomy if they are distally localized. Resection for larger (>2 cm) or malignant-appearing tumors should include total removal of the tumor with negative margins (including adjacent organs) and regional lymph nodes.

Surveillance of Resected Pancreatic Neuroendocrine Tumors (Well-Differentiated Grade 1/2)

Disease recurrence has been observed in 21% to 42% of patients with pancreatic NETs and can occur after many years.²³³⁻²³⁵ Higher lymph node ratio and Ki-67 status may indicate a higher chance of recurrence.²³³ Patients should undergo follow-up 12 weeks to 12 months after resection, or earlier if the patient presents with symptoms. After 1-year post-resection, follow-up should occur every 6 to 12 months for up to 10 years post-resection with an H&P. Appropriate biochemical markers can be considered as clinically indicated. After 10 years, surveillance should be considered as clinically indicated.²³⁶ Abdominal multiphasic CT or MRI should be performed. Chest CT scans (with or without contrast) can be performed as clinically indicated. These surveillance recommendations may also apply to cases where observation of patients with metastatic disease has been chosen. Less frequent surveillance may be appropriate for low-risk tumors such as well-differentiated stage I pancreatic NETs. SSR-based imaging or FDG-PET/CT scans are not recommended for routine surveillance.

The optimal duration of surveillance is unknown. In one study of 123 patients with resected sporadic pancreatic NETs, most recurrences occurred within 5 years of resection, and all recurrences occurred within 10 years.²³⁷ In select cases, including resectable locoregional or oligometastatic recurrence, surgical resection may be considered.

Management of Locoregional Advanced and/or Metastatic Neuroendocrine Tumors of the Pancreas (Well-Differentiated Grade 1/2)

To evaluate the extent of locoregional advanced disease and/or distant metastases, multiphasic CT or MRI scans with IV contrast of the abdomen, with or without pelvis, should be performed. SSR-based imaging is also recommended. A chest CT scan with or without contrast and appropriate biochemical evaluation may be carried out if clinically indicated. Metastases in patients with NETs of the pancreas, when they



NCCN Guidelines Version 4.2021

Neuroendocrine and Adrenal Tumors

develop, often occur first in the liver. In patients with limited hepatic disease, surgical excision of both the primary tumor and liver metastases should be considered with curative intent when possible and can be performed in a staged or synchronous fashion. A meta-analysis reported that 5-year OS ranges from 41% to 100% in this patient population.¹⁴⁰ Noncurative debulking surgery can also be considered in select cases. When performing staged pancreatoduodenectomy and liver resection, hepatectomy should be considered before pancreatic resection to reduce the risk of perihepatic sepsis from the contaminated biliary tree.²³⁸ Although resection may provide clinical benefit, most patients with metastatic disease will experience recurrence.^{141,142} Additional resection or ablation may be possible. A study of 172 patients who had liver resection of metastatic NETs (55 with the primary tumor in the pancreas) showed that significant long-term survival can be achieved after recurrence in many patients, with a 10-year OS rate of 50.4%.¹³⁹

If resection is performed for advanced NETs and future treatment with octreotide or lanreotide is anticipated, cholecystectomy is recommended given the association between long-term treatment with somatostatin analogs and the development of biliary symptoms and gallstones.¹¹⁵

Unfortunately, most patients who present with advanced pancreatic NETs have unresectable disease. For selected patients with unresectable disease who are asymptomatic and have low tumor burden and stable disease, observation can be considered, with marker assessment and abdominal and pelvic multiphasic CT or MRI scans every 12 weeks to 12 months until clinically significant disease progression occurs. Chest CT scans with or without contrast may also be performed if clinically indicated. In addition, however, treatment with lanreotide or octreotide can be considered (see discussion below). The optimal time to begin therapy in this patient population is not known.

For symptomatic patients with unresectable disease, those who initially present with clinically significant tumor burden, or those with clinically significant disease progression, octreotide or lanreotide should be considered if patients are not already receiving treatment with these options. Several different options can be considered if the disease continues to progress. Systemic options include targeted therapy (everolimus [category 1 for progressive disease], sunitinib [category 1 for progressive disease], and consideration of belzutifan [in the setting of germline *VHL* alteration in patients with progressive pancreatic NETs]); PRRT with 177Lu-dotatate if SSR-positive imaging and progression on octreotide or lanreotide) temozolomide/capecitabine or treatment with other cytotoxic chemotherapy; or palliative RT for symptomatic bone metastases. The options above, as well as liver-directed therapies, are discussed in more detail in the following sections. These regimens were also preference stratified. Everolimus, octreotide, lanreotide, sunitinib, temozolomide/capecitabine, and PRRT with 177Lu-dotatate are preferred treatment options. Cytotoxic chemotherapy options, for patients with bulky, symptomatic, and/or progressive disease are listed as “other recommended” regimens and include 5-FU/doxorubicin/streptozocin, streptozocin/doxorubicin, streptozocin/5-FU, FOLFOX, and CAPEOX. Consideration of belzutifan is a “useful in certain circumstances” option.

Somatostatin Analogs

Patients with pancreatic NETs and symptoms of hormone hypersecretion should, in most cases, receive treatment with either lanreotide or octreotide and/or other medication to manage their symptoms as previously described. Patients without hormone-related symptoms who have uptake with somatostatin scintigraphy can also be considered for treatment with octreotide or lanreotide. Results from the CLARINET study, in which 204 patients with gastroenteropancreatic NETs (including both carcinoid and pancreatic NETs) were randomized to receive treatment with either lanreotide or placebo, showed that treatment with lanreotide



NCCN Guidelines Version 4.2021

Neuroendocrine and Adrenal Tumors

was associated with an improvement in PFS (PFS, not reached vs. 18 months; HR, 0.47; 95% CI, 0.30–0.73; $P < .001$).¹³⁶ Although no randomized studies to date have directly shown an antitumor effect of octreotide in pancreatic NETs, the PROMID trial showed an improvement in its primary endpoint of time to tumor progression (14.3 vs. 6 months; $P = .000072$) in carcinoid (neuroendocrine) tumors of the midgut.¹³³ Lanreotide and octreotide share the same mechanism of action, and the panel believes that either lanreotide or octreotide are appropriate options for tumor control in this setting.

Additional therapies can be given in place of or in addition to octreotide or lanreotide, as discussed below.

Molecularly Targeted Therapies

The molecularly targeted agents everolimus and sunitinib have been confirmed to have antitumor activity and to improve PFS in patients with advanced pancreatic NETs. In addition, data have shown the clinical benefits of belzutifan in patients with pancreatic NETs not requiring immediate surgery, in the setting of germline *VHL*.

Everolimus, administered orally at a dose of 10 mg once daily, was evaluated in a multicenter study (RADIANT-3) enrolling 410 patients with advanced, progressive, pancreatic NETs.²³⁹ In this study, the median PFS duration for patients randomized to everolimus was 11.0 months, compared with 4.6 months for patients receiving placebo ($P < .001$). Subset analyses of RADIANT-3 suggested that the PFS benefit associated with everolimus is independent of prior or concurrent somatostatin analog therapy or prior chemotherapy.^{167,240,241} Everolimus can also be considered to stabilize glucose levels for patients with insulinomas.²⁴² Adverse events associated with everolimus include stomatitis, hyperglycemia, and, in rare cases, pneumonitis.²³⁹ Other side effects have also been described.^{164–166} One report highlighted the outcomes of 169 pretreated patients with advanced NETs of the pancreas

($n = 85$) or other sites ($n = 84$) who received everolimus through a compassionate use program.¹⁶⁸ A higher risk of adverse events was noted in patients with previous radiolabeled peptide therapy and chemotherapy.

Sunitinib, administered orally at a dose of 37.5 mg once daily, was compared with placebo in a multicenter randomized study of patients with advanced, progressive, metastatic pancreatic NETs.²⁴³ The study was designed to enroll 340 patients but was discontinued after enrollment of 171 patients, before the predefined efficacy analysis. At discontinuation, patients who received sunitinib had a median PFS duration of 11.4 months, compared with 5.5 months for patients receiving placebo ($P < .001$). The ORR seen with sunitinib was 9.3%.²⁴³ A large proportion of patients on the placebo arm subsequently received sunitinib at progression, and no significant difference in OS was observed between the arms.²⁴⁴ Long-term treatment (median 87.1 weeks) did not alter the safety profile.²⁴⁵ Adverse events associated with sunitinib include fatigue and, in rare cases, congestive heart failure.²⁴⁶ Other side effects have also been described, including diarrhea, mucositis, and weakness.^{247–249}

A phase II study evaluated belzutifan in 61 patients with germline *VHL* alterations who had localized/nonmetastatic renal cell carcinoma and allowed the presence of *VHL* disease-associated tumors in other organ systems.²⁵⁰ The study excluded patients with prior systemic anticancer therapy, including anti-vascular endothelial growth factor (VEGF) therapy, patients needing immediate surgical intervention for tumor treatment, or patients with evidence of metastatic disease on screening imaging, but included patients with pancreatic NETs and central nervous system hemangioblastomas. Data showed that belzutifan resulted in an ORR of 91% in 22 patients with pancreatic NETs, as assessed by an independent review committee using RECIST, version 1.1. Fourteen percent of patients achieved a complete response. The median time to response and median duration of response for these patients were 5.5 months (range, 2.5



NCCN Guidelines Version 4.2021

Neuroendocrine and Adrenal Tumors

months–16.4 months) and not reached (range, 2.9+ months–22.3+ months), respectively, with responses still ongoing at the time to data cutoff (median follow-up of 21.8 months [range, 20.2 months–30.1 months] for all patients). The most common grade 3 adverse events were anemia (8%), hypertension (8%), and fatigue (5%) across all patients.

Cytotoxic Chemotherapy for Advanced Pancreatic Neuroendocrine Tumors (Well-Differentiated Grade 1/2)

Cytotoxic chemotherapy is another option for patients with locoregional advanced or metastatic pancreatic NETs. While a number of regimens have been associated with antitumor activity in this setting, there is no panel consensus on which cytotoxic chemotherapy regimen is best. The alkylating agents streptozocin and temozolomide appear to have the most antitumor activity in pancreatic NETs.

Streptozocin is FDA approved for use in patients with advanced pancreatic NETs. The combination of doxorubicin and streptozocin was initially reported to be associated with an overall response rate of 69% and a survival benefit in a relatively small randomized study of patients with advanced pancreatic NETs.²⁵¹ A retrospective review from MD Anderson Cancer Center reported an ORR of 39% with the combination of 5-FU, doxorubicin, and streptozocin.²⁵² A phase II trial assessed bevacizumab combined with 5-FU and streptozocin.²⁵³ A PFS of 23.7 months was reported, with 56% of patients achieving a partial response and 44% achieving stable disease.

Oral temozolomide-based therapy is also used in patients with advanced pancreatic NETs. Temozolomide has been administered using different schedules, either alone or in combination with other agents.^{175,254-257} A retrospective series reported that the combination of temozolomide with capecitabine was associated with an objective radiographic response rate of 70% and a median PFS of 18 months.²⁵⁷ Another retrospective review of the temozolomide and capecitabine combination reported a 61%

response rate in 18 patients, with 1 surgically proven complete pathologic response.²⁵⁸ A meta-analysis of 384 patients with advanced neuroendocrine neoplasms reported an OS greater than 12 months and a 73% disease control rate.²⁵⁹ Another study with 32 patients found that the combination treatment led to a median OS of 24 months and improved PFS.²⁶⁰

Temozolomide-based combination regimens have also been formally evaluated in prospective, phase II studies. One such study assessed the safety and efficacy of temozolomide administered with bevacizumab, a monoclonal antibody targeted against VEGF.²⁵⁴ Five of the 15 patients (33%) with pancreatic NETs had a radiographic response (with no responses in the 19 patients with carcinoid tumors), and the toxicity was acceptable. The combination of temozolomide with everolimus has also been studied and found to be safe, with partial responses observed in 40% of patients with pancreatic NETs.²⁶¹

These results suggest that the activity of temozolomide in pancreatic NETs is at least comparable to that of streptozocin, and support its use in pancreatic NETs. The combination of temozolomide with everolimus has also been studied. There is no current consensus, however, on the optimal temozolomide dosing regimen or whether temozolomide should be administered alone or in combination with other agents.

Other cytotoxic agents appear to be less active than streptozocin or temozolomide in pancreatic NETs. 5-FU was assessed in the phase II/III E1281 trial in combination with streptozocin or doxorubicin in patients with NETs of various locations, including the pancreas.¹⁷⁴ Response rates in both arms were around 16%. Dacarbazine was given following progression, with a response rate of 8%. Other studies have also shown the combination of 5-FU and streptozocin to be effective in this setting.^{262,263} One study with 88 patients with pancreatic NETs found a partial response rate of 31%, a median PFS of 9 months, and an OS of 30



NCCN Guidelines Version 4.2021

Neuroendocrine and Adrenal Tumors

months,²⁶⁴ while a smaller study obtained a disease control rate of 78% with the use of FOLFOX.²⁶⁵ The combination of capecitabine and oxaliplatin was assessed in a phase II study, with response rates of 23% in patients with poorly differentiated NETs and 30% in well-differentiated disease.¹⁷³ As oxaliplatin-based chemotherapy has shown some promising results,²⁶⁶ more studies are needed to expand these findings.

Radiolabeled Somatostatin Analogs for Advanced Pancreatic Neuroendocrine Tumors (Well-Differentiated Grade 1/2)

Treatment with radiolabeled somatostatin analogs has been reported to result in tumor responses in patients with advanced pancreatic NETs.¹⁸¹⁻¹⁸⁵ Numerous large, non-randomized cohort analyses have also reported encouraging survival rates with this approach.^{188,189,191} Most recently, the study of 177Lu-dotatate in a group of 610 Dutch patients with metastatic gastroenteropancreatic NETs and bronchial NETs included 133 patients with pancreatic NETs.¹⁹¹ Patients with a primary NET in the pancreas had the longest OS (71 months) and six patients had a complete response.¹⁹¹ In general, these studies have enrolled only patients with evidence of high tumoral SSR expression. A randomized study of high-dose octreotide versus 177Lu-dotatate has been reported in patients with advanced midgut NETs, and results from this study suggest this approach is both safe and associated with improved PFS in this setting.¹⁹⁰ Prospective, randomized studies of radiolabeled somatostatin analogs have not yet been completed in patients with advanced pancreatic NETs.²⁶⁷

The panel recommends PRRT with 177Lu-dotatate as a treatment option for patients with locoregional advanced pancreatic NETs and/or distant metastases who have symptomatic disease, clinically significant tumors burden, or clinically significant progressive disease, and disease progression with positive SSR imaging.

Liver-Directed Therapies

Liver-directed therapies may be considered in patients with progressive liver-predominant metastatic disease, to reduce tumor bulk and relieve symptoms of hormone hypersecretion.¹⁴⁶ The panel lists cytoreductive surgery or ablative therapy (ie, RFA,¹⁵² cryotherapy, microwave^{149,151}) (category 2B) as recommendations for these patients. Although some groups report that the risks of cytoreductive surgery outweigh its benefits,²⁶⁸ others have reported good outcomes.^{269,270}

Additional options include hepatic regional therapies including bland hepatic arterial embolization,¹⁵³ radioembolization,¹⁵⁷⁻¹⁶⁰ and chemoembolization.²⁷¹ Whereas embolization in general is considered an effective approach in patients with liver-predominant disease,^{144,145,147} only limited data compare the various embolization techniques, and the optimal embolization approach remains uncertain. After any prior biliary instrumentation, there are increased risks of infectious complications associated with liver-directed therapies.²⁷²

Liver Transplantation Considered Investigational

Several series have now reported the results of liver transplantation in patients with pancreatic NETs whose metastases are confined to the liver.^{196-201,273} A meta-analysis showed that, while 5-year survival rates are encouraging, the majority of patients undergoing liver transplantation ultimately develop recurrence.²⁰³ The panel acknowledged the considerable associated risks and deemed liver transplantation to be investigational and not part of routine care at this time.

Neuroendocrine Tumors of Unknown Primary

A SEER database analysis reported high incidence rates for NETs with an unknown primary site of 0.84 per 100,000 persons.^{1,2} When a NET of unknown primary is diagnosed, attempts are usually first made to identify the origin of the neoplasm to help guide treatment decisions.^{274,275} If the



NCCN Guidelines Version 4.2021

Neuroendocrine and Adrenal Tumors

primary tumor cannot be identified, treatment decisions are generally guided by tumor histology (see *Histologic Classification and Staging of Neuroendocrine and Adrenal Tumors*, above). Many of these tumors are poorly differentiated and aggressive.²⁷⁶

Evaluation of Neuroendocrine Tumors of Unknown Primary

The initial evaluation of a patient with biopsy-proven NETs of unknown primary includes family history, clinical manifestations, laboratory studies, imaging studies, and/or immunohistochemical studies. Family history is particularly relevant as it may identify affected relatives and patients who are at increased risk for multiple endocrine tumors, such as patients with MEN1 or MEN2.

Given the differences in systemic treatment approaches for carcinoid and pancreatic NETs, establishing whether a patient has a primary pancreatic NET can have important treatment implications. Potential primary sites may be investigated with imaging studies, such as chest CT scans with or without contrast, and multiphasic abdominal and pelvic CT or MRI scans. Many express specific receptors for amines or peptides (eg, SSRs), and SSR-based imaging may be helpful in localizing primary NETs.^{70,277} Ultrasound or EUS of the pancreas is useful for patients with possible insulinomas or other NETs of the pancreas. In addition, radionuclide bone imaging (bone scan) is recommended to evaluate patients suspected of having metastatic bone disease. An FDG-PET/CT or PET/MRI scan and brain imaging with contrast (CT or MRI) can occasionally be useful in finding a primary tumor, but are less sensitive in well-differentiated NETs and should only be considered in cases of poorly differentiated tumors.

Colonoscopy can also be considered, especially in cases of well-differentiated liver metastases, to identify possible primary tumors in the small intestine or colon.²⁷⁸ It is not uncommon for small bowel NETs to be small and difficult to visualize, although in some cases imaging may demonstrate an associated mesenteric mass. Exploratory surgery is

generally not recommended for purely diagnostic purposes. However, if a small bowel primary tumor is suggested by symptoms and radiologic findings and if metastases are completely resectable, surgery can be considered.²⁷⁸

Primary Treatment of Neuroendocrine Tumors of Unknown Primary

NETs of unknown primary should be treated presumptively as gastroenteropancreatic NETs. If the primary tumor is not identified, poorly differentiated NETs should be treated as described for *Poorly Differentiated Neuroendocrine Carcinomas/Large or Small Cell Carcinomas or Unknown Primary*, below. In the absence of a primary tumor identified in the pancreas, well-differentiated tumors should be treated similarly to typical grade 1/2 NETs, as described above.

Well-Differentiated Grade 3 Neuroendocrine Tumors

Well-differentiated G3 NETs were introduced as a new category in the 2017 WHO classification update of pancreatic NENs, and in the 2019 WHO classification for digestive system (gastroenteropancreatic) NENs (including unknown primary tumors). These encompass tumors that have a high proliferation rate, with a mitotic index greater than 20 or a Ki-67 index greater than 20%, and a well-differentiated morphology.²⁷⁹ These occur mostly in the pancreas, stomach, and colon, although they can occur at any primary site. Well-differentiated G3 tumors have a better prognosis than poorly differentiated NECs, but a worse prognosis when compared to G1–G2 well-differentiated NETs.²⁵ The results from two studies showed that patients with well-differentiated G3 NETs had a significantly higher median OS (41–99 months vs. 17 months) compared to patients with poorly differentiated NECs.^{280,281}

Evaluation of Well-Differentiated Grade 3 Neuroendocrine Tumors

Imaging with multiphasic abdominal/pelvic CT or MRI scans with contrast, with or without chest CT scans (if clinically indicated), and SSR-based



NCCN Guidelines Version 4.2021

Neuroendocrine and Adrenal Tumors

PET imaging (SSR-PET) is recommended. SSR-based PET imaging should include PET/CT or PET/MRI of the skull base to mid-thigh with IV contrast (both arterial and portal venous phase), when possible. Data are limited on the optimal timing of SSR scans following administration of somatostatin analogs. FDG-PET/CT scans can be performed as appropriate if SSR PET imaging is negative. There are some instances where FDG PET is useful in patients with positive SSR PET. Biochemical evaluation should be performed if the patient has symptoms suggestive of a secretory tumor. Pathology review is recommended and assessment of p53, Rb, and p16, by histopathologic analysis or molecular profiling, can be considered if there is uncertainty about the tumor's degree of differentiation, as a mutation in these genes would suggest a poorly differentiated NEC.²⁸²⁻²⁸⁴ SSR 2A staining may also be helpful.²⁸⁵ Genetic counseling and testing for inherited genetic syndromes is recommended only for duodenal or pancreatic NETs.

Primary Treatment of Well-Differentiated Grade 3 Neuroendocrine Tumors

Treatment recommendations are based on the biology of the tumor. A tumor with favorable biology typically possesses Ki-67 less than 55%, is slow-growing, and may yield a positive SSR-based PET result. A tumor with unfavorable biology typically has Ki-67% greater than or equal to 55%, is faster-growing, and may yield a negative SSR-based PET result. Importantly, the data informing the appropriate Ki-67 cutoff are limited and variability/heterogeneity of Ki-67 in a given tumor and over time in serial biopsies make decision-making less straightforward in this entity compared to other NENs. The combination of clinical course and histopathologic workup should dictate therapy, not solely Ki-67. For locoregional (resectable) disease, resection is recommended, along with regional lymphadenectomy, if feasible, regardless of tumor biology.²⁸⁶ Patient factors should be considered.

For resectable locoregional disease with unfavorable biology, a clinical trial is preferred. Neoadjuvant chemotherapy can also be given on a case-by-case basis and options include temozolomide with or without capecitabine, oxaliplatin-based therapy (FOLFOX or CAPEOX), cisplatin/etoposide, or carboplatin/etoposide. Temozolomide may have more activity in tumors arising in the pancreas. Following the completion of neoadjuvant chemotherapy, the patient should undergo resection with regional lymphadenectomy if feasible.

For resectable locally advanced or metastatic disease with favorable biology, resection of the primary and metastatic sites may be performed, if feasible. The treatment for unresectable locally advanced or metastatic tumors depends on the degree of tumor burden. If the patient is asymptomatic with low tumor burden, observation with a short interval follow-up scan is an option for select patients; otherwise, octreotide or lanreotide is recommended if the patient is SSR-positive and/or has hormonal symptoms. There are multiple treatment modalities if the patient has a clinically significant tumor burden or evidence of disease progression. Octreotide or lanreotide is recommended if the patient is SSR-positive and/or has hormonal symptoms. Enrollment in a clinical trial is preferred. Other recommended treatment options include PRRT with 177Lu-dotatate, everolimus, sunitinib (pancreas only), chemotherapy, or liver-directed therapy (for liver-predominant disease). Chemotherapy options consist of temozolomide with or without capecitabine,²⁶⁰ oxaliplatin-based therapy (FOLFOX, CAPEOX), cisplatin/etoposide, or carboplatin/etoposide. Pembrolizumab (category 2B) is also an option for patients with advanced tumor mutational burden-high (TMB-H) tumors (≥ 10 mutations/Mb), as determined by an FDA-approved test, that have progressed following prior treatment and have no satisfactory alternative treatment options.^{287,288} There is some concern with the TMB cutoff. In some cancers, compared to a TMB-low status, a TMB-H status did not result in a higher objective response rate (ORR) in patients treated with an



NCCN Guidelines Version 4.2021

Neuroendocrine and Adrenal Tumors

immune checkpoint inhibitor,²⁸⁹ especially after additional cohort stratification.²⁹⁰ Please see *Principles of Peptide Receptor Radionuclide Therapy (PRRT) with 177Lu-dotatate* in the algorithm for practical guidance and information, including patient eligibility, patient preparation for treatment, dose and administration of 177Lu-dotatate, post-treatment instructions, and timing of somatostatin analogues.

In the event of locally advanced or metastatic disease with unfavorable biology, a clinical trial is a preferred option. Other recommended options include chemotherapy (as described above) and the combination of nivolumab and ipilimumab (category 2B).²⁹¹ Pembrolizumab is also an option for patients with advanced TMB-H tumors, as determined by an FDA-approved test, that have progressed following prior treatment and have no satisfactory alternative treatment options.^{287,288} Additional chemotherapy options in this setting include irinotecan-based therapies (eg, FOLFIRI, cisplatin/irinotecan, FOLFIRINOX). The addition of liver-directed therapies, including embolization, selective internal RT, ablation, and SBRT, can be considered in selected cases with residual liver-predominant disease after systemic therapy. Palliative RT is recommended for symptomatic bone metastases.

Evolving data suggest that well-differentiated tumors with intermediate Ki-67 levels (in the 20%–55% range) may not respond as well to platinum/etoposide as patients with higher Ki-67 (>55%).³⁴ A few studies reported that treatment with platinum-based chemotherapy yielded almost no response (0%–2% response rate).^{280,281,292}

Surveillance of Well-Differentiated Grade 3 Neuroendocrine Tumors

Surveillance for resectable locoregional, locally advanced, or metastatic disease consists of a routine patient H&P examination along with appropriate imaging studies (abdominal/pelvic MRI scans with contrast or abdominal/pelvic multiphasic CT, and chest CT scans as clinically indicated) every 12 to 24 weeks for the first 2 years and every 6 to 12

months thereafter, for up to 10 years. Surveillance for resectable locoregional disease depends on the tumor biology and Ki-67%. Patients with unresectable locally advanced or metastatic disease with favorable biology should be monitored every 12 to 24 weeks (depending on tumor biology), with an H&P and a chest CT with or without contrast and an abdominal/pelvic MRI with contrast or a chest/abdominal/pelvic multiphasic CT scan. SSR-PET/CT or SSR-PET/MRI or FDG PET/CT scans and biochemical markers are also recommended as clinically indicated. Patients with unresectable locally advanced or metastatic disease with unfavorable biology should follow the same surveillance recommendations (except for SSR imaging) but should be followed every 8 to 12 weeks (depending on tumor biology).

Poorly Differentiated Neuroendocrine Carcinomas/Large or Small Cell Carcinomas or Unknown Primary

Although rare, extrapulmonary poorly differentiated NECs can occur in a wide variety of organs. They are characterized by a high mitotic index and high Ki-67 index. The most aggressive of these tumors histologically resemble classic small cell carcinoma of the lung. The most frequent organs involved are the cervix, esophagus, pharynx and larynx, colon, rectum, prostate, pancreas, and bladder.²⁹³ Most extrapulmonary poorly differentiated NECs are aggressive and require combined multimodality treatment, usually following a treatment paradigm that parallels the treatment of small cell lung cancer. These tumors are rarely associated with a hormonal syndrome. Gastrointestinal tumors with mixed histology of poorly differentiated adenocarcinoma can be treated according to the NCCN Guidelines for Colon Cancer and Pancreatic Adenocarcinoma (available at www.NCCN.org).

Results from a SEER database analysis of NECs found that 9% were extrapulmonary.²⁹³ The median survival for all NECs was 7.7 months. Compared to other primary NECs (26.0%), the survival was lower for lung



NCCN Guidelines Version 4.2021

Neuroendocrine and Adrenal Tumors

NECs (5.6%) and GI NECs (13.1%) at 5 years. The median survival of patients with GI NECs was 7.5 months, with patients with small intestine tumors doing better (25.1 months) than patients with pancreatic tumors (5.7 months). The median survival for patients with unknown primary NECs was 2.5 months.

Evaluation of Poorly Differentiated/Large or Small Cell Carcinomas or Unknown Primary

CT scans of the chest, abdomen, and pelvis or CT scans of the chest and MRI of the abdomen and pelvis are recommended as baseline staging studies. Brain imaging with MRI or CT scan with contrast and FDG-PET should be performed as clinically indicated, and should be considered routinely in poorly differentiated NECs of the thorax and neck. Biochemical markers are recommended if symptoms are suggestive of a secretory tumor. SSR imaging is not part of the routine evaluation of poorly differentiated NECs. Tumor biomarkers such as microsatellite instability (MSI), MMR, and TMB testing (by an FDA-approved test) should be considered as they can aid in assessing targeted therapy options.

Primary Treatment of Extrapulmonary Poorly Differentiated/Large or Small Cell Neuroendocrine Carcinomas or Unknown Primary

For resectable poorly differentiated/large or small cell NECs, poorly differentiated of unknown primary, treatment options depend on the disease site. Such options include surgical resection and adjuvant chemotherapy with or without radiotherapy, neoadjuvant chemotherapy with or without radiation and resection, chemotherapy alone, RT alone, and definitive chemoradiation (with cisplatin/etoposide or carboplatin/etoposide). For unresectable locoregional disease, concurrent or sequential radiotherapy in combination with chemotherapy, or chemotherapy alone are recommended. If metastatic disease is present, chemotherapy alone is recommended.

Cytotoxic chemotherapy regimens, such as cisplatin/etoposide^{294,295} or carboplatin/etoposide,²⁹⁶ FOLFIRI,²⁹⁷ FOLFIRI,²⁹⁸ and temozolomide with or without capecitabine,²⁹⁹ are generally used as primary treatment for resectable, locoregional unresectable, or metastatic disease. For locoregional unresectable or metastatic disease, additional chemotherapy options include cisplatin/irinotecan,²⁹⁵ carboplatin/irinotecan, and FOLFIRINOX.^{300,301} The efficacy of second-line or later lines of chemotherapy is very limited and survival is short.³⁰² The combination of ipilimumab and nivolumab (category 2B) can be considered if the disease progresses following chemotherapy.^{291,303} The results of one phase II study (S1609 DART) revealed an ORR of 44% in patients with non-pancreatic high-grade NECs (including lung primaries) treated with combined ipilimumab and nivolumab.³⁰³ Subsequent data from an additional cohort of patients (N = 19) with high-grade NENs (median Ki-67 80%) revealed an ORR of 26% and a 6-month PFS of 32%.³⁰⁴ The median PFS was 2.0 months and the median OS was 8.7 months. The subgroup analysis of the CA209-538 trial, centered on patients with advanced NENs that received the combined treatment, demonstrated an ORR of 24%.²⁹¹ The median PFS was 4.8 months and the OS was 14.8 months. Immune-related toxicity occurred in 66% of cases. Importantly, preliminary data from the multi-cohort phase II study (N = 123) of durvalumab plus tremelimumab for patients with NENs of gastroenteropancreatic or lung origin suggested only modest activity (irRECIST ORR 9.1%) in G3 gastroenteropancreatic NENs.³⁰⁵

Finally, pembrolizumab can also be considered for patients with MMR-deficient, MSI-high, or advanced TMB-high (as determined by an FDA-approved test) tumors that have progressed following prior treatment and have no satisfactory alternative treatment options.^{287,288,306}



NCCN Guidelines Version 4.2021

Neuroendocrine and Adrenal Tumors

Surveillance of Poorly Differentiated/Large or Small Cell Carcinomas or Unknown Primary

For patients with resectable disease, surveillance after treatment completion consists of a routine H&P along with appropriate imaging studies (chest CT with or without contrast and abdominal/pelvic MRI with contrast or chest/abdominal/pelvic multiphasic CT) every 12 weeks for the first year and every 6 months thereafter. However, patients with locoregional, unresectable disease and with metastatic disease should be monitored more closely every 6 to 16 weeks with an H&P and appropriate imaging studies as described.

Adrenal Gland Tumors

Adrenocortical carcinomas are rare (incidence, 0.7–2 per million).^{307,308} ACC has a bimodal age distribution, with peak incidences in early childhood and the fourth to fifth decades of life. Women are more frequently affected (55%–60%).^{307,309} Most cases are sporadic; however, ACCs have been observed in association with several hereditary syndromes, including Li-Fraumeni syndrome, Lynch syndrome, Beckwith-Wiedemann syndrome, MEN1, and familial adenomatous polyposis.^{8,310-315} The underlying mechanisms of carcinogenesis in sporadic ACCs have not been fully elucidated; however, inactivating somatic mutations of the *p53* tumor suppressor gene (chromosome 17p13^{316,317}) and alterations at the 11p15 locus (site of the *IGF2* gene^{318,319}) seem to occur frequently.

Approximately 60% of patients present with evidence of adrenal steroid hormone excess, with or without virilization.³⁰⁸ Signs and symptoms associated with hypersecretion of cortisol, called Cushing syndrome, include weight gain, weakness (primarily in proximal muscles), hypertension, psychiatric disturbances, hirsutism, centripetal obesity, purple striae, dorsocervical fat pad and supraclavicular fat pad enlargement, hyperglycemia, and hypokalemia. Aldosterone-secreting tumors may present with hypertension, weakness, and hypokalemia.

Androgen-secreting tumors in women may induce hirsutism, virilization, deepening of the voice, and oligo/amenorrhea.³⁰⁸ In men, estrogen-secreting tumors may induce gynecomastia and testicular atrophy. Hormonally inactive ACCs typically produce symptoms related to tumor burden, including abdominal pain, back pain, early satiety, and weight loss.³⁰⁸

Evaluation and Treatment of Adrenal Gland Tumors

All patients with adrenal gland tumors need biochemical evaluation and appropriate imaging. Biochemical evaluation to evaluate for hyperaldosteronism, Cushing syndrome, pheochromocytoma, and suspected ACC should be done with every adrenal mass. Comprehensive guidelines for the workup of adrenal tumors, adrenal incidentalomas, hyperaldosteronism, Cushing syndrome, and pheochromocytoma and paraganglioma are published through the Endocrine Society³²⁰⁻³²² and the European Society of Endocrinology (ESE).^{323,324}

NCCN recommends doing a morphologic evaluation of adrenal nodules with adrenal protocol CT, or MRI with or without contrast, to determine the size, heterogeneity, lipid content (with MRI), contrast washout (with CT), and margin characteristics. If the Hounsfield unit (HU) attenuation value is less than 10 on unenhanced CT, then the tumor is probably benign. If the HU attenuation value is greater than 10 on unenhanced CT, then enhanced CT and washout at 15 minutes is recommended. If the absolute washout value is greater than 60% at 15 minutes, the tumor is likely benign; if less than 60%, the tumor is possibly malignant.^{325,326} Functional evaluation should be done as noted above. Most ACCs secrete multiple hormones; therefore, if imaging is suspicious for adrenal cortical carcinoma, evaluation for sex steroid in addition to the above evaluation is indicated. If several hormones are over-secreted, ACCs are more likely.

History of a primary cancer outside of the adrenal gland raises the question of metastatic disease to the adrenals. However, it is very



NCCN Guidelines Version 4.2021

Neuroendocrine and Adrenal Tumors

important that pheochromocytoma is ruled out prior to considering diagnostic biopsy of the adrenal mass. In these patients, an image-guided needle biopsy can be considered only if clinical suspicion for pheochromocytoma is low and plasma or urine fractionated metanephrines are normal. False-negative biopsies are possible; therefore, proceeding directly to surgery should be considered in some cases. If the tumor is determined to be a metastasis from another site, treatment should be according to the appropriate NCCN disease-specific treatment guideline (to see the NCCN Guidelines Table of Contents, go to www.NCCN.org). If biopsy reveals adrenal cortical tissue, then morphologic and functional evaluation should proceed as described here.

Evaluation and Treatment of Hyperaldosteronism

When hyperaldosteronism (also called *primary aldosteronism*) is suspected, plasma aldosterone and plasma renin activity should be assessed. Patients with primary aldosteronism have elevated plasma levels of aldosterone and low levels of renin activity. The plasma aldosterone-to-renin ratio in patients with primary hyperaldosteronism is usually greater than 30.³²² Confirmatory testing is often recommended for equivocal results. Twenty-four-hour urine for aldosterone, following salt loading or a saline suppression test, as well as sodium and potassium levels should be considered for definitive diagnosis. Serum electrolytes should also be measured, because excessive aldosterone production causes both retention of sodium and excretion of potassium. The Endocrine Society has developed detailed guidelines for the detection, diagnosis, and treatment of primary aldosteronism,³²² and these guidelines have been modified over time.^{327,328}

Hyperaldosteronism is rarely associated with malignancy, but malignancy should be suspected if the tumor has an irregular or inhomogeneous morphology, is lipid-poor, does not wash out on contrast-enhanced CT, is larger than 4 cm, or is secreting more than one hormone. When malignant

hyperaldosteronism is suspected, an open adrenalectomy is recommended, because these tumors are prone to rupture.³²⁴

Benign hyperaldosteronism is much more common and can be caused by a unilateral adrenal adenoma or bilateral adrenal hyperplasia. Adrenal vein sampling for aldosterone and cortisol can be considered for distinguishing these two causes of benign hyperaldosteronism and should be considered if the patient is a surgical candidate, because CT imaging cannot always differentiate between an adenoma and hyperplasia. It may be reasonable, however, to exclude adrenal vein sampling in patients younger than 40 years when imaging only shows one affected gland, because bilateral hyperplasia is rare in this population. Minimally invasive adrenalectomy is recommended for adenoma, whereas medical management with spironolactone or eplerenone for hypertension and hypokalemia is recommended for patients with bilateral adrenal hyperplasia and for nonsurgical candidates.

Evaluation and Treatment of Cushing Syndrome

Patients who present with symptoms of Cushing syndrome should be evaluated for evidence of hypercortisolemia with one of the following tests: 1) overnight 1-mg dexamethasone suppression test; 2) 2 to 3 midnight salivary cortisol measurements; or 3) free cortisol in a 24-hour urine sample.^{321,329} Elevated levels of cortisol are indicative of Cushing syndrome. Plasma ACTH should be checked to determine if it is ACTH dependent or ACTH independent (ACTH <5 pg/mL). Adrenal masses that secrete cortisol are not mediated by ACTH (ACTH independent), and ACTH dependent tumors can arise in the pituitary or ectopic NET sources. If a clear pituitary adenoma is not visible by MRI, inferior petrosal sinus vein sampling can be considered to differentiate between pituitary and ectopic causes in ACTH-dependent Cushing syndrome. Endocrinology referral should be considered for the biochemical workup, localization of



NCCN Guidelines Version 4.2021

Neuroendocrine and Adrenal Tumors

hypercortisolemia, and medical therapy for hypercortisolism until more definitive therapy can be arranged.

Cushing syndrome can be associated with either benign adrenal tumors (adrenal adenoma) or malignant adrenal tumors. Malignancy should be suspected if the tumor is larger than 4 cm or is inhomogeneous with irregular margins and/or has local invasion and other malignant imaging characteristics. Some centers may use 6 cm as a cutoff instead of 4 cm. FDG PET/CT scans, chest CT scans with or without contrast, and CT or MRI scans with contrast of the abdomen and pelvis are recommended. Benign adrenal tumors (ie, <4 cm, contralateral gland normal, circumscribed tumor, other benign imaging characteristics) should be resected. It is important that patients who have cortisol-secreting adrenal tumor receive perioperative glucocorticoids since the contralateral adrenal secretion will be transiently suppressed. For more details, please see the Endocrine Society's Clinical Practice Guidelines for the Treatment of Cushing Syndrome.³³⁰

Treatment of Nonfunctioning, Benign Adrenal Tumors

Adrenal tumors that do not secrete hormones are often discovered incidentally during scans for unrelated reasons (*incidentalomas*). It is still important to evaluate for biochemical secretion of hormones for hyperaldosteronism, Cushing syndrome, and pheochromocytoma and paraganglioma as listed above to confirm they are non-secreting. Please refer to the American Association of Clinical Endocrinology and American Association of Endocrine Surgeons (AACE/AAES) guidelines³³¹ and the ESE guidelines³²⁴ for the management of adrenal incidentalomas. Most nonfunctioning tumors are benign and can be left untreated. Masses showing radiographic features of myelolipoma are considered benign. In addition, tumors smaller than 4 cm that are homogenous, with smooth margins, and that appear lipid-rich according to CT or MRI criteria are also usually benign. A minimally invasive adrenalectomy is preferred for these

tumors if resection is indicated due to tumor growth. If malignancy is suspected and the disease is localized, locally resectable, or regionally advanced, an open adrenalectomy is recommended.

Evaluation of Adrenocortical Carcinoma

ACC should be strongly suspected in tumors larger than 4 cm with irregular margins or that are internally heterogeneous and if they secrete multiple hormones.³⁰⁸ On CT scans with IV contrast, adjacent lymph nodes or liver metastases may be present. On unenhanced CTs, the HU number is typically higher in carcinomas than in adenomas, and a threshold value of 10 HU has been proposed as a means of distinguishing benign from malignant adrenal tumors.³⁰⁸ If the HU attenuation value is less than 10 on unenhanced CT, then the tumor is probably benign. If the HU attenuation value is greater than 10 on unenhanced CT, then enhanced CT and washout at 15 minutes is recommended. If the absolute washout value is greater than 60% at 15 minutes, the tumor is likely benign; if less than 60%, the tumor is possibly malignant.^{325,326} MRIs more clearly document local invasion and involvement of the inferior vena cava than CT scans.³⁰⁸ Whether CT or MRI scans are performed, they should be performed using an adrenal protocol to determine size, heterogeneity, lipid content (MRI), contrast washout (CT), and margin characteristics.

FDG PET/CT, chest CT scans with or without contrast, CT or MRI scans with contrast of the abdomen and pelvis, and a biochemical workup are also recommended for resectable, unresectable, or suspected metastatic disease.

One study found that 5.8% of adults with ACC tested positive for Li Fraumeni syndrome (*TP53* gene) and genetic testing should be routinely offered to all patients with ACC.³³² Another analysis found that approximately 3% of patients with ACC have Lynch syndrome, leading the authors to recommend that patients with ACC also undergo genetic testing for Lynch syndrome.³¹⁴ Patients with ACC may also consider MSI, MMR,



NCCN Guidelines Version 4.2021

Neuroendocrine and Adrenal Tumors

and TMB (by an FDA-approved test) testing. Genetic counseling and testing for inherited genetic syndromes is also recommended.

Treatment and Surveillance of Non-metastatic Adrenocortical Carcinoma

Surgical resection of the tumor with removal of adjacent lymph nodes is recommended in patients with localized ACC, and may require removal of adjacent structures such as the liver, kidney, pancreas, spleen, and/or diaphragm for complete resection. Open adrenalectomy is recommended in tumors with a high risk of being malignant because of increased risk for local recurrence and peritoneal spread when performed laparoscopically.³³³ It is thus important to achieve negative margins and avoid breaching the tumor capsule.

Because of the rarity of ACCs, no randomized, prospective trials of adjuvant therapy have been published. Most retrospective reports have examined the use of adjuvant mitotane, an oral adrenocorticolytic agent.³³⁴ A recent systematic review and meta-analysis of the benefits of mitotane after resection of ACC in patients without distant metastasis included five retrospective studies reporting on 1249 patients.³³⁵ The meta-analysis found benefit of adjuvant mitotane, with significantly longer recurrence-free survival and OS, suggesting that adjuvant mitotane may be an effective postoperative strategy. The randomized phase III ADIUVO trial is currently underway to assess the efficacy of adjuvant mitotane in patients with ACCs considered to be at low to intermediate risk for progression (ClinicalTrials.gov identifier: NCT00777244). Disease-free survival is the primary endpoint.

Based on the available data, adjuvant therapy can be considered if the patient is at high risk for local recurrence based on positive margins, ruptured capsule, large size, and high grade. Adjuvant external beam RT to the tumor bed can be considered in these cases, particularly if concern exists regarding tumor spillage or close margins after surgery. Adjuvant mitotane therapy can also be considered after resection of ACC, although

its use in this setting is controversial (category 3). Mitotane blood levels should be monitored. Some institutions recommend target levels of 14 to 20 mcg/mL if tolerated. Steady-state levels may be reached several months after initiation of mitotane. Because of the adrenolytic effects of mitotane, replacement doses of corticosteroids (hydrocortisone with or without fludrocortisone) should be prescribed to treat adrenal insufficiency if it is used; corticosteroids may be required for the rest of the patient's life. Because of the potential risks and uncertain benefits of adjuvant mitotane, several NCCN Member Institutions do not advocate its use in the adjuvant treatment of patients with resected ACCs.

A follow-up should be performed every 12 weeks to 12 months for up to 5 years, and then as clinically indicated. Recurrences after 5 years are thought to be very rare. A chest CT scan, with or without contrast, and an abdominal CT or MRI scan with contrast and biomarkers (if the tumor is initially functional) should be considered.

Management of Locoregional Unresectable or Metastatic Adrenocortical Carcinoma

Resection may be considered if greater than 90% of the tumor and metastases can be removed. In the case of bulky disease or if less than 90% of the tumor is removable, surgery can be reconsidered following a response to systemic therapy. Observation with chest CT scans with or without contrast, abdominal/pelvic CT or MRI scans with contrast, and relevant biomarkers (if the tumor is initially functional) every 12 weeks can also be considered for clinically indolent disease, with systemic treatment initiated at tumor progression. For locoregional unresectable or metastatic disease, local therapy may be considered (ie, SBRT, thermal ablative therapies, liver-directed therapies).

Systemic therapy should be considered, preferably in a clinical trial. Choices of systemic therapy for advanced ACC are mitotane monotherapy or various combinations of cisplatin, carboplatin, etoposide, doxorubicin,



NCCN Guidelines Version 4.2021

Neuroendocrine and Adrenal Tumors

streptozocin, and mitotane. Mitotane monotherapy has been studied in the setting of locally advanced or metastatic disease.³³⁶⁻³³⁸ Partial response rates are thought to be 10% to 30% at most.³³⁹ Pembrolizumab can also be considered as a single agent or in combination with mitotane. These regimens were preference stratified. Preferred regimens include cisplatin or carboplatin in combination with etoposide, with or without doxorubicin, and with or without mitotane. Pembrolizumab, with or without mitotane, and mitotane monotherapy are listed as “other recommended” regimens. Streptozocin, with or without mitotane, is listed as “useful in certain circumstances.”

A small phase II study investigating the use of pembrolizumab in patients with advanced ACCs found an ORR of 23% and a disease control rate of 52%.³⁴⁰ The median OS was 24.9 months. Another small study with 16 patients with advanced ACC demonstrated an ORR of 14% (95% CI, 2%–43%).³⁴¹ One phase II study reported a 15% ORR and a 54% clinical benefit rate.³⁴²

Several studies have evaluated the combination of mitotane with other cytotoxic agents, including cisplatin and etoposide. One of the larger studies analyzed the combination of mitotane (4 g/day) with cisplatin, etoposide, and doxorubicin in 72 patients with unresectable adrenal carcinoma, yielding an ORR of 49% (according to WHO criteria) and a complete hormonal response in 16 of 42 patients with functioning tumors.³⁴³ Another study examined the combination of mitotane with streptozocin and reported an ORR of 36%.³⁴⁴ Of 12 patients in this study with advanced disease, 3 (25%) were converted to a resectable status with this therapy and remained disease-free or with stable disease 3 to 18 years after surgery; 1 (8%) had stable disease for 3 months, and the other 8 (67%) showed no response.

Analysis of results from the international randomized controlled phase III FIRM-ACT trial comparing treatment of metastatic ACC with etoposide,

doxorubicin, cisplatin, and mitotane versus treatment with streptozotocin and mitotane with a crossover design found no difference between the regimens in the primary endpoint of OS (14.8 vs. 12.0 months; HR, 0.79; 95% CI, 0.61–1.02; $P = .07$).³⁴⁵ However, response rates and PFS were improved with the 4-drug regimen and an OS benefit was seen in those who did not cross over to the other combination (17.1 vs. 4.7 months). Rates of serious adverse events were similar in the two arms.

However, the toxicity of concurrent chemotherapy plus mitotane should be considered when making treatment decisions, and mitotane monotherapy may still be appropriate in selected cases. The optimal doses and duration of mitotane treatment for metastatic disease have not yet been standardized, but some institutions recommend target levels of 14 to 20 mcg/mL, if tolerated. Higher doses may be difficult for patients to tolerate, whereas lower doses may be less effective.³³⁹ Steady-state levels may be reached several months after initiation of mitotane. As noted above, because of the adrenolytic effects of mitotane, replacement doses of corticosteroids (hydrocortisone with or without fludrocortisone) should be prescribed to treat adrenal insufficiency. This replacement therapy may be required for the remainder of the patient's lifetime. A follow-up with chest CT scans, with or without contrast, and abdominal/pelvic CT or MRI scans, with contrast, or FDG-PET/CT scans should be performed every 12 weeks to 12 months, up to 5 years, and then as clinically indicated.

Pheochromocytomas/Paragangliomas

Pheochromocytomas are neoplasms of the chromaffin cells of the adrenal medulla in 80% to 90% of cases. Ectopic/extra-adrenal pheochromocytomas that arise from sympathetic and para-aortic sympathetic ganglia are called paragangliomas.³²⁰ Pheochromocytomas and paragangliomas occur in 0.05% to 0.1% of hypertensive patients, and their combined annual incidence in the United States is estimated to be between 500 and 1600 cases.³⁴⁶ Approximately 10% to 15% of



NCCN Guidelines Version 4.2021

Neuroendocrine and Adrenal Tumors

pheochromocytomas and paragangliomas are malignant, but it could be up to 40%.^{323,347} Pheochromocytomas release catecholamines (epinephrine and norepinephrine) and their metabolites metanephrine and normetanephrine, resulting in hypertension, arrhythmia, and/or hyperglycemia. About 40% of paragangliomas secrete catecholamines. Head and neck paragangliomas only secrete catecholamines about 5% of the time and often it is dopamine.

The peak incidence of occurrence for pheochromocytomas is between the third and fifth decades of life, but they generally occur at a younger age and are more likely to be bilateral in patients with familial disease.

Paragangliomas are more likely to be malignant than pheochromocytomas in the adrenal medulla (about 40% vs. 10%). Pheochromocytomas and paragangliomas associated with a familial syndrome tend to be more aggressive and more likely to metastasize than sporadic tumors.³⁴⁸ In fact, a study showed that 87.5% of patients presenting with these tumors prior to age 20 harbored a germline mutation in one of several genes tested if they also had metastatic disease.³⁴⁹ For those without metastases, the rate of identification of these mutations was still high, at 64.7%. The OS of patients with pheochromocytomas and paragangliomas can be heterogeneous, but a systematic review and meta-analysis of seven studies of 738 patients reported survival to be 63% at 5 years.³⁵⁰

Predicting who will go on to develop metastasis is difficult, but some studies have reported that almost half of patients have not progressed a year after diagnosis.³⁵¹ Delays at a median of 5.5 years with a range from 0.3 to 53.4 years between initial diagnosis and metastasis have been reported in a retrospective study spanning 55 years of patients with pheochromocytomas or paragangliomas, and many such patients survive long term after treatment of metastatic disease.³⁵² Thus, patients presenting during childhood, adolescence, or young adulthood require careful, lifelong surveillance (see *Surveillance of Pheochromocytomas/Paragangliomas*, below).

Evaluation for Pheochromocytomas/Paragangliomas

A patient with possible pheochromocytoma should be evaluated with fractionated metanephrines and normetanephrines in 24-hour urine or free metanephrines in plasma. Elevated levels of metanephrines or normetanephrines are suggestive of pheochromocytoma or paraganglioma. In general, adrenal pheochromocytomas more commonly secrete metanephrines and paragangliomas secrete normetanephrines, with a few exceptions.³²⁰ Concurrent medications should be reviewed before testing for those that interfere with plasma or blood metanephrine/normetanephrine evaluation, including acetaminophen, certain beta- and alpha-adrenoreceptor blocking drugs, serotonin-reuptake inhibitors, and monoamine oxidase inhibitors.³⁵³ Elevations in metanephrine or normetanephrine levels that are three times above the upper limit of normal are diagnostic. Urine or plasma catecholamines are no longer routinely recommended for the evaluation of pheochromocytoma as 15% to 20% of patients with pheochromocytoma have normal levels of urine catecholamines due to intermittent secretion in some tumors and insignificant secretion by others.³⁵⁴ Measurement of serum and/or 24-hour urine fractionated catecholamines can be considered since rare tumors preferentially secrete catecholamines, and cervical paragangliomas can secrete dopamine.

Adrenal protocol CT scans (abdomen/pelvis) are recommended. Other imaging studies, including abdominal/pelvic multiphasic CT or MRI scans, SSR-based imaging (PET/CT or PET/MRI), FDG-PET/CT scans (skull base to mid-thigh), chest CT scans with or without contrast, and metaiodobenzylguanidine (MIBG) scans should be performed as appropriate if metastatic or multifocal disease is suspected. CT scans are most helpful for adrenal masses and paragangliomas. However, there are some instances where extra-adrenal paragangliomas are seen better with MRI scans.



NCCN Guidelines Version 4.2021

Neuroendocrine and Adrenal Tumors

Genetic Counseling/Testing in Pheochromocytomas/Paragangliomas

While many pheochromocytomas and paragangliomas are thought to be sporadic, increasing evidence shows that a number of pheochromocytomas and paragangliomas are in fact associated with inherited genetic syndromes.^{346,355} Pheochromocytomas occur in patients with MEN2A, MEN2B, and other familial diseases such as neurofibromatosis and VHL syndrome (see *Principles of Genetic Risk Assessment and Counseling* in the algorithm). Paragangliomas are also associated with polycythemia-paraganglioma-somatostatinoma syndrome due to somatic mutations in the *HIF2A* gene.^{356,357} In addition to germline mutations associated with these syndromes (ie, *RET*, *NF1*, *VHL*), germline mutations in *SDHB*, *SDHA*, *SDHAF2*, *SDHD*, *SDHC*, *TMEM127*, *MAX*, *FH*, and *MDH2* have also been associated with an increased incidence of pheochromocytomas and paragangliomas.^{347,355-361} *SDHB* gene mutations are associated with a 40% to 60% risk of developing metastatic disease.³⁴⁷ Patients younger than 45 years of age or those with multifocal, bilateral, or recurrent lesions are more likely to have a heritable mutation, although many individuals with a hereditary syndrome present with solitary disease and no family history.³⁶¹ Because a significant proportion of patients with a pheochromocytoma or paraganglioma have a heritable mutation,³⁵⁵ genetic counseling is recommended in patients with such a diagnosis and in those with a family history of these tumors, with genetic testing when appropriate. The Endocrine Society has published guidelines that include a genetic testing decision algorithm.³²⁰

Individuals with known germline mutations associated with pheochromocytomas and paragangliomas should undergo lifelong biochemical and clinical surveillance, beginning around ages 6 to 8 years.³⁶¹ The type and timing of the surveillance should be based on which gene is affected and take into account known genotype-phenotype relationships. MRI may be the preferable imaging modality for tumor detection in these individuals in order to limit radiation exposure.

Primary Treatment of Pheochromocytomas/Paragangliomas

Surgical resection is the mainstay of treatment for both benign and malignant pheochromocytomas and paragangliomas. Surgery or stress can cause a sudden release of large amounts of catecholamines, causing very significant and sometimes life-threatening hypertension. Therefore, patients with pheochromocytomas or paragangliomas should receive preoperative alpha-adrenergic blockade with aggressive volume repletion and high-salt diet for 7 to 14 days or until stable. Alpha 1-selective receptor blockers include terazosin, doxazosin, and prazosin, and non-selective receptor blockers include phenoxybenzamine. If additional blood pressure control is needed after alpha blockade, the addition of dihydropyridine calcium channel blockers can be considered. Calcium channel blockers are not recommended as monotherapy unless the patient cannot tolerate alpha blockade. Metyrosine can be used in addition to alpha blockade to control blood pressure. Beta blockade (B1-selective blockers or non-selective beta-blockers) can also be added to alpha blockade to control tachycardia. Generally, alpha- and beta-blockers should be administered independently, and use of combination beta-/alpha-blockers is not recommended. Non-selective alpha blockade phentolamine (IV) can be used intraoperatively for additional blood pressure control.

Resection is the recommended treatment for patients with resectable tumors. A minimally invasive approach, when safe and feasible, is the preferred treatment for adrenal medullary tumors, including pheochromocytomas.³⁶²⁻³⁶⁴

For locally unresectable tumors, observation is recommended, if asymptomatic. RT is recommended with cytoreductive resection, when possible. Alternatively, if tumors are positive on MIBG scan,^{365,366} treatment with high-specific-activity (HSA) iobenguane I-131 or other iodine-131-MIBG therapy is recommended. If tumors are SSR-positive



NCCN Guidelines Version 4.2021

Neuroendocrine and Adrenal Tumors

upon imaging, PRRT with ¹⁷⁷Lu-dotatate or treatment with octreotide or lanreotide (if symptomatic) may be considered. The panel advises diligence to ensure that the maximum cumulative radiation dose is not reached for these patients. In addition, medical therapy as described above should be continued for unresectable secreting tumors.

The results of a phase 2, open-label, multicenter study investigating HSA iobenguane I-131 to treat patients with malignant, recurrent, and/or unresectable pheochromocytoma or paraganglioma^{367,368} revealed that the primary endpoint, which was a reduction in antihypertension medication by at least half, was met by 25% of all patients who received at least one therapeutic dose (n = 68) and 32% of patients who received two therapeutic doses (n = 50)³⁶⁹. The objective tumor response was evaluated as a secondary endpoint. Overall 23% of patients had partial response, which went up to 30% in patients who received two therapeutic doses, and 68% of patients had stable disease. The median OS was 37 months. The most commonly reported side effects in patients who received any dose of HSA iobenguane I-131 were nausea, myelosuppression, and fatigue. In 2018, HSA iobenguane I-131 became an FDA-approved option for patients who have an MIBG positive scan; have unresectable, locally advanced, or metastatic pheochromocytoma or paraganglioma; and require systemic anticancer therapy.

A study of 20 patients with high SSR expressing pheochromocytoma or paraganglioma treated with ¹⁷⁷Lu-dotatate measured the effectiveness of PRRT in controlling hypertension.³⁷⁰ Most patients receiving PRRT saw no increase or reduction in medication to treat hypertension. The median PFS was 39 months and median OS was not reached with a median follow-up time of 28 months. A systematic review and meta-analysis of 201 patients with inoperable or metastatic pheochromocytomas or paragangliomas determined that treatment with PRRT led to an ORR of 25% (95% CI,

19%–32%) and a disease control rate of 84% (95% CI, 77%–89%).³⁷¹ Clinical responses were reported in 61% of patients.

An ENETS Centre study with 22 patients with progressive or metastatic pheochromocytomas or paragangliomas treated patients with PRRT with either ⁹⁰Y-dotatate or ¹⁷⁷Lu-dotatate, and ¹³¹I-MIBG.³⁷² Patients treated with PRRT had increased PFS and treatment response compared to ¹³¹I-MIBG treatment, but no significant differences were seen in OS. Other case studies have been presented at conferences³⁷³⁻³⁷⁵ or published^{376,377} that have also shown improvements in patients with high SSR expressing pheochromocytoma or paraganglioma treated with ¹⁷⁷Lu-dotatate.

When distant metastases are present, observation is recommended if asymptomatic. Medical therapy with octreotide or lanreotide should be continued for secreting tumors. For the latter, cytoreductive resection is recommended when possible. Other options for treating unresectable, metastatic disease include: 1) clinical trial; 2) systemic chemotherapy (eg, cyclophosphamide/vincristine/dacarbazine [CVD] or temozolomide)^{255,378-381}; 3) HSA iobenguane ¹³¹I or other iodine-¹³¹I-MIBG therapy after positive MIBG scan^{365,366,369}; 4) if SSR-positive PET imaging, consider PRRT with ¹⁷⁷Lu-dotatate; or 5) palliative RT for symptomatic metastases.

A retrospective review of 52 evaluable patients treated with various systemic chemotherapy regimens for metastatic pheochromocytomas or paragangliomas showed that patients with a response to chemotherapy (reduction in symptoms, antihypertensive medications, or tumor size) had a median survival of 6.4 years and non-responders had a median survival of 3.7 years.³⁷⁹ Approximately 33% of patients exhibited a tumor response.

A review of 48 patients with pheochromocytoma or paraganglioma treated with iodine-¹³¹I-MIBG therapy at four centers showed that, while partial responses were rare, stable disease was achieved after 83.1% of



NCCN Guidelines Version 4.2021

Neuroendocrine and Adrenal Tumors

treatments.³⁸² A meta-analysis of 17 studies that included a total of 243 patients with malignant paraganglioma or pheochromocytoma found a stable disease rate of 52% (95% CI, 0.41–0.62) after iodine-131-MIBG therapy.³⁸³ Partial and complete responses were seen in 27% and 3% of patients, respectively.

Surveillance of Pheochromocytomas/Paragangliomas

Surveillance intervals for patients with pheochromocytomas or paragangliomas are similar to those for other NETs. Following complete resection, H&P should be performed and blood pressure and tumor markers should be measured after 12 weeks to 12 months, then every 6 to 12 months for the first 3 years, and then annually for up to 10 years. After 10 years, surveillance should be considered as clinically indicated. In addition, chest CT scans with or without contrast, and abdominal/pelvic CT or MRI scans with contrast can be considered. Timing for these surveillance events and procedures can be earlier if symptoms dictate or less frequently if the disease is stable and there are no new symptoms. For locally unresectable disease or distant metastases, H&P should be performed and blood pressure and relevant markers should be measured every 12 weeks to 12 months. Chest/abdominal/pelvic CT scans with contrast, chest CT scans (with or without contrast) and abdominal/pelvic MRI scans without contrast (if the patient is at risk for a hypertensive episode), FDG-PET/CT scans, or SSR-based imaging can be considered. In addition, individuals with hereditary paraganglioma/pheochromocytoma may require more frequent and longer follow-up (see *Principles of Genetic Risk Assessment and Counseling* in the algorithm).

Multiple Endocrine Neoplasia

The MEN syndromes are characterized by tumors that arise from endocrine organs and cells throughout the body. The two most common syndromes are MEN1 and MEN2. MEN1 is an autosomal-dominant inherited syndrome characterized by hyperparathyroidism (most

commonly 4-gland hyperplasia), pituitary adenomas, and pancreatic NETs; MEN1 may also be associated with NETs of the lung and thymus, adrenal tumors, multiple lipomas, and cutaneous angiomas. MEN2 is also an autosomal-dominant inherited syndrome and is associated with medullary thyroid carcinoma (MTC) (98%); pheochromocytoma (50%), often bilateral; and hyperparathyroidism (25%). In addition, familial MTC occurs in patients without MEN2 and is inherited as an autosomal dominant disease.

MEN1 is associated with the germline mutation or inactivation of the tumor suppressor gene *MEN1* (chromosomal locus 11q13 encoding the menin protein),³⁸⁴ whereas MEN2 and familial MTC are associated with germline mutations of the proto-oncogene, *RET* (chromosomal locus 10q11.2), that lead to activation of the tyrosine kinase receptor, RET.³⁸⁵ Somatic mutation of the *MEN1* gene is also the most common known genetic alteration in sporadic parathyroid adenomas, gastrinomas, insulinomas, and bronchial NETs.⁸ Somatic *RET* mutations are found in sporadic MTC.³⁸⁶

MEN1

MEN1 (or Werner syndrome) is typically characterized by tumors of the parathyroid and pituitary glands; NETs of the pancreas, thymus, bronchi, or GI tract; adrenal tumors; and/or multiple lipomas and skin angiomas. Over 98% of patients with MEN1 either have or will develop primary hyperparathyroidism, and about 50% will develop symptoms from functioning benign or malignant neoplasms of the pancreas.⁸ About 30% to 40% of patients have functioning tumors of the pituitary, and an additional 20% to 55% of patients also have or will develop nonfunctioning pancreatic NETs.³⁸⁷ Approximately 2% of patients with MEN1 develop thymic or bronchopulmonary NETs.³⁸⁸ Thymic and duodenopancreatic neuroendocrine neoplasias are the leading cause of death in patients with MEN1.³⁸⁹ Approximately 30% of patients with MEN1 die from NETs.³⁸⁸



NCCN Guidelines Version 4.2021

Neuroendocrine and Adrenal Tumors

Examples of functional syndromes include hypercalcemia related to parathyroid hyperplasia; galactorrhea or amenorrhea associated with a prolactinoma; Zollinger-Ellison syndrome associated with gastrinoma and hypersecretion of gastrin; and Cushing's syndrome or acromegaly related to a pituitary tumor or solitary or bilateral adrenal tumors. Ectopic Cushing syndrome may be caused by a neuroendocrine tumor of the pancreas, thymus, or bronchus, or by an MTC. In addition, although rare, patients may develop symptoms as a result of an excess of several hormones from more than one gland, such as hyperparathyroidism and a simultaneous gastrinoma, insulinoma, or a functioning pituitary tumor. However, in most patients, a single hormonal syndrome dominates the clinical picture.

About 80% of patients with MEN1 and hypoglycemia related to insulinoma have multiple islet cell neoplasms. Patients with MEN1 and Zollinger-Ellison syndrome also frequently have more than one tumor. Of these tumors, 70% are gastrin-secreting NETs in the duodenum and/or periduodenal lymph nodes. Nonfunctioning pancreatic NETs are usually larger when clinically detected, and are more likely to be associated with metastases at the time of presentation. The development of metastatic NETs of the pancreas or thymus are the most common causes of death associated with MEN1. The clinical characteristics of pancreatic endocrine tumors are summarized under *Neuroendocrine Tumors of the Pancreas*, above.

Evaluation of MEN1 Syndromes

A clinical diagnosis for MEN1 can be made when an individual patient has two or more MEN1-associated tumors (ie, multi-gland parathyroid hyperplasia, enteropancreatic NETs, pituitary tumors).³⁸⁸ For patients known or suspected to have MEN1, clinical evaluation includes biochemical evaluation of hormone levels and imaging to localize the site of tumors. In particular, patients should be evaluated for pancreatic neuroendocrine, parathyroid, and pituitary tumors (see below). In addition,

genetic counseling and testing for inherited genetic syndromes should be provided (see *Genetic Counseling/Testing in MEN1*, below).

Evaluation for Parathyroid Tumors in MEN1

Primary hyperparathyroidism associated with parathyroid adenomas is the most common manifestation of MEN1. Measurement of serum calcium levels is recommended if hyperparathyroidism is suspected. If calcium levels are elevated, parathyroid hormone (PTH) and 25-OH vitamin D levels should be checked.

Imaging of parathyroid glands is less helpful in MEN1 because of the multiple gland hyperplasia.³⁸⁸ Imaging of the parathyroid glands using neck ultrasound, 4-D CT, and/or sestamibi scanning with single photon emission CT (SPECT) is optional but may aid in identifying ectopically situated parathyroid glands. Preference of scan will depend on institutional practice/protocol.

The technetium 99m (Tc 99m) sestamibi and ultrasound scanning are about 80% and 70% sensitive, respectively, for identifying solitary parathyroid adenomas found in most patients with sporadic hyperparathyroidism. However, these scans are only about 35% accurate in patients with familial hyperparathyroidism and 4-gland hyperplasia. Neither scan can distinguish between adenomatous and hyperplastic parathyroid glands. Because most patients with familial hyperparathyroidism have multiple abnormal parathyroid glands, preoperative localization studies are less accurate and abnormal parathyroid glands are best identified during surgery.^{390,391} Tc 99m sestamibi with SPECT can improve sensitivity and specificity compared to planar scan.³⁹²

4D-CT is a method of multiphase CT imaging that uses a fourth dimension of changes in contrast attenuation over time and is increasingly used for preoperative imaging.³⁹³ It has 60% to 87% sensitivity and allows for more



NCCN Guidelines Version 4.2021

Neuroendocrine and Adrenal Tumors

robust diagnostic accuracy than traditional sonography or nuclear scintigraphy techniques. Three- or four-phase CT scanning protocols consist of precontrast, arterial, early-delayed, and late-delayed phases.

Evaluation for Pancreatic Tumors in MEN1

Approximately 75% of patients with MEN1 and pancreatic NETs have associated symptoms of hormone hypersecretion. The various characteristics of endocrine tumors of the pancreas (eg, gastrinoma, insulinoma, glucagonoma, VIPoma, somatostatinoma) are summarized under *Neuroendocrine Tumors of the Pancreas*, above. The workup for pancreatic NETs in the context of MEN1 is similar to that for sporadic pancreatic NETs. Abdominal, with or without pelvis, multiphasic CT or MRI is recommended. Imaging with EUS and SSR-based imaging can be used as appropriate if there are equivocal CT findings. In particular, EUS is recommended if resection is being considered to preoperatively assess and localize tumors. For details on the evaluation for pancreatic tumors, see *Neuroendocrine Tumors of the Pancreas*, above.

Evaluation for Pituitary Tumors in MEN1

Pituitary or sella MRI with contrast is recommended when evaluating for pituitary tumors. Various laboratory tests are also used to evaluate for suspected pituitary tumors. The panel lists serum prolactin and insulin-like growth factor 1 (IGF-1) levels among recommended tests (category 2B). Elevated prolactin levels are indicative of prolactinoma, and increased IGF-1 occurs in acromegaly.

Additional biochemical evaluation that can be considered includes measurement of thyroid-stimulating hormone (TSH [free T4]), produced by some adenomas, and luteinizing hormone (LH) and follicle-stimulating hormone (FSH). Screening for Cushing syndrome may also be considered.

Evaluation for Bronchial/Thymic Tumors in MEN1

Chest CT with contrast and abdominal/pelvic multiphasic CT or MRI are recommended to evaluate for bronchopulmonary or thymic tumors in patients with MEN1. Other biochemical evaluation should be done as clinically indicated.

Genetic Counseling/Testing in MEN1

Genetic counseling and *MEN1* genetic testing should be offered to individuals with a clinical diagnosis of MEN1 (see *Evaluation of MEN1 Syndromes*, above) and to at-risk relatives of individuals with known germline *MEN1* mutations.^{387,388} Genetic risk evaluation is also recommended in a patient with clinical suspicion for MEN1 with two or more of the following, or one of the following and a family history of one or more of the following: primary hyperparathyroidism, duodenal/pancreatic NET, pituitary adenoma, or foregut carcinoid (bronchial, thymic, or gastric). It should be noted that a germline *MEN1* mutation is uncommon in individuals with a single MEN1-associated tumor and no family history. Only 10% of patients with MEN1 have a *de novo* germline mutation in *MEN1*, and thus no family history of MEN1-associated tumors.

For patients with a clinical diagnosis of MEN1 and a negative MEN1 genetic test result, physicians should consider having the patients and their first-degree family members follow the related surveillance recommendations (See *MEN1 Surveillance*, below).

Primary Treatment of MEN1 Syndromes

Primary therapy of locoregional disease in patients with MEN1 focuses on treatment of the specific hormonal syndrome and/or treatment of the underlying hyperplasia or tumor. When a patient presents with hyperparathyroidism and pancreatic NETs, the hyperparathyroidism is usually treated first. A consultation with an endocrinologist for all patients with MEN1 should be considered.



NCCN Guidelines Version 4.2021

Neuroendocrine and Adrenal Tumors

Primary Treatment of Parathyroid Tumors in MEN1

Treatment options for parathyroid hyperplasia in patients with MEN1 include subtotal parathyroidectomy with or without thymectomy (the bilateral upper thymus is a common site of ectopic parathyroid glands and thymic NETs) with or without cryopreservation of parathyroid tissue. Total parathyroidectomy with autotransplantation of parathyroid tissue with or without thymectomy, and with or without cryopreservation of parathyroid glands, is another recommended option.³⁹⁴⁻³⁹⁶ A randomized, prospective trial compared these surgical approaches in 32 patients with MEN1 and hyperparathyroidism.³⁹⁷ No significant differences were observed in outcomes including recurrent hyperparathyroidism. Adverse outcomes include persistent hyperparathyroidism (2%–5%) and hypocalcemia (1%) because of inadequate or excessive resection, respectively, even by expert surgeons. Additionally, postoperative bleeding or hoarseness due to injury to the recurrent laryngeal nerve may occur in about 1% of patients.

Primary Treatment of Pancreatic Tumors in MEN1

Treatment of pancreatic NETs associated with MEN1 is similar to sporadic pancreatic NETs and focuses on surgical excision preceded by medical management if necessary (see relevant site-specific recommendations in *Neuroendocrine Tumors of the Pancreas*, above). However, in contrast to patients with sporadic disease where a tumor is usually solitary, pancreatic NETs associated with MEN1 are frequently multiple.³⁹⁸ Removal of a single functioning tumor, although a reasonable approach for sporadic tumors, may miss additional tumors in the setting of MEN1. MEN1-associated metastatic pancreatic NETs are often slower growing than metastatic sporadic tumors. Observation can be considered for non-functioning, indolent tumors. Surgical resection should be considered in cases of: 1) symptomatic functional tumors refractory to medical management; 2) a tumor larger than 1 to 2 cm in size; or 3) a tumor with a relatively rapid rate of growth over 6 to 12 months. The panel recommends

endoscopy with EUS prior to pancreatic surgery to preoperatively assess and localize tumors.

For clinically significant progressive disease or symptomatic patients, treatment options are as for metastatic disease in the sporadic setting (see *Management of Locoregional Advanced and/or Metastatic Neuroendocrine Tumors of the Pancreas*, above).

All patients who might require splenectomy should receive trivalent vaccine (ie, pneumococcus, *haemophilus influenzae b*, meningococcal group C) preoperatively. Furthermore, in patients undergoing abdominal surgery in whom octreotide or lanreotide treatment is planned, prophylactic cholecystectomy can be considered due to a higher risk of cholelithiasis in patients receiving somatostatin analogs.¹¹⁵ Metastatic disease in patients with MEN1 is treated as in patients with NETs arising sporadically, according to the appropriate tumor type.

Primary Treatment of Pituitary Tumors in MEN1

The panel recommends consultation with endocrinology for the treatment of patients with pituitary tumors associated with MEN1, including those with prolactinoma, Cushing syndrome, acromegaly, and nonfunctioning tumors.

Primary Treatment of Bronchial/Thymic Tumors in MEN1

The recommendations for the workup and treatment of bronchopulmonary and thymic tumors are the same as for patients with sporadic disease (see *Neuroendocrine Tumors of the Gastrointestinal Tract (Well-Differentiated Grade 1/2), Lung, and Thymus* in the algorithm).

MEN1 Surveillance

All patients with MEN1 should be followed for the development or progression of MEN1-associated tumors, regardless of previous tumors or treatments. In contrast to sporadic hyperparathyroidism, patients with



NCCN Guidelines Version 4.2021

Neuroendocrine and Adrenal Tumors

familial hyperparathyroidism (including MEN1), isolated familial hyperparathyroidism, or hyperparathyroidism associated with jaw tumor syndrome are more likely to develop recurrent disease.³⁹⁹ Consider referral to an endocrinologist. The patients are also more likely to have or develop new parathyroid carcinomas, pancreatic NETs, pituitary tumors, and/or bronchial/thymic tumors. Carcinoid (neuroendocrine) tumors occur in approximately 3% of patients with MEN1.³⁸⁸ Bronchial NETs occur more frequently in women, while thymic NETs occur more frequently in men. In addition, smokers appear to be at increased risk for the development of thymic NETs.³⁸⁸ In one prospective study, the authors compared the use of lanreotide to active surveillance in patients with MEN1-associated pancreatic NETs less than 2 cm.⁴⁰⁰ The results revealed that lanreotide treatment significantly improves the median PFS (median not reached vs. 40 months).

The panel recommends annual calcium and serum PTH levels to screen for parathyroid tumors. If calcium levels rise, 25-OH vitamin D should be measured and imaging with neck ultrasound and/or parathyroid sestamibi with SPECT scan (SPECT-CT preferred) or 4D-CT should be performed. Cross-sectional CT or MRI with contrast of the neck can also be considered. MRI over CT should be considered to minimize radiation risks.

Surveillance for MEN-1-associated pancreatic NETs is accomplished by following serum hormones as symptoms indicate or if they were previously elevated. Cross-sectional imaging with abdominal/pelvic CT or MRI with contrast every 1 to 3 years or serial EUS can also be considered in patients with MEN1.

Surveillance for pituitary tumors includes a pituitary or sella MRI with contrast of the pituitary every 3 to 5 years. Prolactin, IGF-1, and other previously abnormal pituitary hormones should be followed every 3 to 5 years or as symptoms indicate.

For surveillance of bronchial or thymic NETs, the panel suggests that cross-sectional chest CT or MRI with contrast be considered every 1 to 3 years. MRI over CT should be considered to minimize radiation risks.

All close family members of patients with MEN1 should receive genetic counseling, and genetic testing should be considered as described above.

MEN2 and Familial MTC

MEN2 can be further subdivided into MEN2A (Sipple syndrome) and MEN2B based on the spectrum of accompanying endocrine tumors and disorders. MTC is seen in nearly all patients with MEN2A and MEN2B and is often the first manifestation of the syndrome.²⁰⁶ Patients with MEN2A may also have or develop pheochromocytoma (usually bilateral, 50%) and hyperparathyroidism (about 25%).²⁰⁶ Some patients with MEN2A have lichen planus amyloidosis or Hirschsprung disease. Most patients with MEN2B have mucosal neuromas or intestinal ganglioneuromas in addition to MTC; 50% of these patients have pheochromocytoma, but almost none have hyperparathyroidism (<1%).²⁰⁶ Nearly all patients with MEN2B have Marfanoid habitus and/or poor dentition. Some patients also have ectopic lenses in the eye or very flexible joints.

MTC is a calcitonin-secreting tumor of the parafollicular or C cells of the thyroid, accounting for about 4% to 7% of thyroid cancers but about 15% of all thyroid cancer deaths. About 75% of MTC cases are sporadic, whereas approximately 25% are considered familial or hereditary. Familial MTC associated with MEN2 normally arises in the first to third decades of life, but sporadic MTC is typically diagnosed in the fourth to fifth decades of life. All types of familial MTC are typically multifocal and preceded by C-cell hyperplasia; however, sporadic MTC is usually unifocal. Familial MTC arising in the absence of other endocrine malignancies or disorders is the least aggressive, whereas MTC associated with MEN2B is the most aggressive. MEN2A, MEN2B, and familial MTC are all autosomal-



NCCN Guidelines Version 4.2021

Neuroendocrine and Adrenal Tumors

dominant inherited diseases and are associated with germline mutations of the proto-oncogene, *RET*.^{9,401}

The initial symptoms associated with MEN2A and MEN2B include a mass in the thyroid gland (with or without adjacent central or lateral cervical lymph node adenopathy) and, less frequently, symptoms of excess hormone production related to MTC (such as diarrhea and facial flushing), pheochromocytoma (headaches, increased perspiration, and rapid heart rate), or hyperparathyroidism.

For a full discussion of the management of MTC, consult the NCCN Guidelines for Medullary Thyroid Cancer (available at www.NCCN.org). The following discussion focuses on the presentation of MEN2 and on the issues unique to MTC in this setting.

Evaluation of MEN2A, MEN2B, and Familial MTC

A clinical diagnosis of MEN2A includes findings of two or more MEN2A-associated tumors (MTC, pheochromocytoma, or hyperparathyroidism) in a single individual or in first-degree relatives.^{402,403} A clinical diagnosis of MEN2B includes the presence of MTC, pheochromocytoma, mucosal neuromas of the lips and tongue, medullated corneal nerve fibers, distinctive facies with enlarged lips, Marfanoid body habitus, or the inability to cry tears.^{402,403} For patients known or suspected to have MEN2A or MEN2B, a clinical evaluation includes: 1) biochemical tests evaluating hormone levels; 2) imaging tests to localize MEN2-associated tumors; and 3) genetic counseling and testing for inherited genetic syndromes.

Before surgical resection of MTC in these patients, basal calcitonin and carcinoembryonic antigen (CEA) levels should be measured, because these test results help guide the extent of nodal dissection required, particularly in patients with occult disease detected by screening. Patients with low calcitonin and high CEA levels usually have more aggressive tumors. Neck ultrasound of thyroid and cervical lymph nodes should also

be performed to document intrathyroidal tumors and to possibly identify cervical lymph node metastases.

Patients with MEN2 should be evaluated for a coexisting pheochromocytoma (see *Evaluation for Pheochromocytomas/Paragangliomas*, above) before administration of anesthetic or before any invasive procedure. Because patients with pheochromocytoma have persistent vasoconstriction, medical therapy (ie, alpha blockade with volume repletion, high salt diet, additional therapy as needed) is required preoperatively (see *Primary Treatment of Pheochromocytomas/Paragangliomas*, above).

For patients with MEN2 who have a parathyroid tumor, serum calcium level should be measured. If it is found to be elevated, PTH and 25-OH vitamin D levels should be measured. A neck ultrasound, sestamibi scan with SPECT, or 4D-CT can also be performed as appropriate. Preference of scan will depend on institutional practice/protocol.

Genetic Counseling/Testing in MEN2

Genetic counseling and *RET* genetic testing should be offered to individuals with MTC or primary C-cell hyperplasia or a clinical diagnosis of MEN2 (see *Evaluation of MEN2A, MEN2B, and Familial MTC*, above).^{402,403} Genetic counseling and testing should also be offered to at-risk relatives of an individual with a known germline *RET* mutation at a very young age.^{402,403} Surveillance should start by age 11 for children in the American Thyroid Association high and highest risk categories and by age 16 in children in the moderate risk category.⁴⁰⁴ Surveillance comprises an annual measurement of plasma-free metanephrines or 24-hour urine for fractionated metanephrines and adrenal imaging in patients with positive biochemical results.⁴⁰⁴ All patients with MTC should be tested for germline mutation of the *RET* oncogene even if the family history is not suggestive of a hereditary syndrome, because about 50% of patients with presumed sporadic MTC have a *de novo* germline mutation.⁴⁰³



NCCN Guidelines Version 4.2021

Neuroendocrine and Adrenal Tumors

For patients with a clinical diagnosis of MEN2 and a negative *RET* genetic test result, physicians should consider having the patients follow the related surveillance recommendations. This also applies to at-risk relatives even if the affected relative had a negative test result or no genetic testing.⁴⁰² See *MEN2 Surveillance*, below.

Primary Treatment of MEN2A, MEN2B, and Familial MTC

In patients with a positive *RET* oncogene test who are otherwise asymptomatic, prophylactic thyroidectomy is performed during the first 5 years of life depending on the aggressiveness of the inherited *RET* mutation or at diagnosis,^{402,405-407} as detailed in the NCCN Guidelines for Medullary Thyroid Carcinoma (available at www.NCCN.org).

The treatment of MTC associated with MEN2 is similar to the management of its sporadic counterpart (see the NCCN Guidelines for Medullary Thyroid Carcinoma, available at www.NCCN.org). However, patients with familial disease are much more likely to have bilateral thyroid carcinomas. In addition, patients may have synchronous pheochromocytoma and MTC. In these cases, resection of pheochromocytoma should take priority over thyroidectomy.

Patients with MEN2 and familial MTC may be prone to hypoparathyroidism because the thyroid gland is often already removed prophylactically or for treatment of C-cell hyperplasia or MTC. The consensus of the panel is for parathyroidectomy of abnormal glands. Subtotal parathyroidectomy is recommended when all glands appear abnormal. Some surgeons recommend prophylactic parathyroidectomy of all normal parathyroid glands with immediate autotransplantation in patients with MTC, while others believe the risk of hypoparathyroidism with this approach (about 6%) is too high to warrant the procedure. If a normal parathyroid gland is not preserved in situ in patients with MEN2A, it can be autotransplanted to the forearm, since recurrent primary hyperparathyroidism occurs in almost 20% of these patients. If hyperparathyroidism recurs with a documented

elevated PTH level in the ipsilateral basilic vein, the tumor can be removed or subtotally resected.

Management of patients with pheochromocytoma and MEN2 is similar to that of pheochromocytoma in other settings. As patients with MEN2 have an appreciable risk for bilateral tumors, a cortical-sparing adrenalectomy may be considered. An interesting retrospective, population-based, observational study of 563 patients with MEN2 and pheochromocytoma from 30 centers across three continents found that adrenal-sparing resections led to similar rates of recurrence with lower rates of adrenal insufficiency or steroid dependency (43% vs. 86%).⁴⁰⁸ More studies are needed, however, before this approach can be routinely recommended.

MEN2 Surveillance

Follow-up surveillance is described in the NCCN Guidelines for Medullary Thyroid Carcinoma (available at www.NCCN.org) for patients with *RET* mutations treated for MTC or for patients who have undergone parathyroidectomy. Follow-up for treatment of pheochromocytomas in these patients is similar to patients who have sporadic disease (see *Surveillance of Pheochromocytomas/Paragangliomas* above).

Future Trial Design

Recent successes have shown that large randomized controlled trials studying treatments for NETs can provide practice-changing results. Current recommendations for clinical trials in NETs include the following⁴⁰⁹:

- Pancreatic NETs should be studied separately from tumors in other locations.
- Well-differentiated and poorly differentiated NECs should be studied in separate trials.



- PFS is an appropriate primary endpoint for phase III trials and many phase II trials.
- Trials studying treatment for hormonal symptoms are as critical as those assessing effects on tumor progression and should include quality-of-life endpoints.

Rigorous studies will allow continued progress in the development of improved treatments for patients with NETs.



NCCN Guidelines Version 4.2021

Neuroendocrine and Adrenal Tumors

References

1. Yao JC, Hassan M, Phan A, et al. One hundred years after "carcinoid": epidemiology of and prognostic factors for neuroendocrine tumors in 35,825 cases in the United States. *J Clin Oncol* 2008;26:3063-3072. Available at: <https://www.ncbi.nlm.nih.gov/pubmed/18565894>.
2. Dasari A, Shen C, Halperin D, et al. Trends in the incidence, prevalence, and survival outcomes in patients with neuroendocrine tumors in the United States. *JAMA Oncol* 2017;3:1335-1342. Available at: <https://www.ncbi.nlm.nih.gov/pubmed/28448665>.
3. Fraenkel M, Kim M, Faggiano A, et al. Incidence of gastroenteropancreatic neuroendocrine tumours: a systematic review of the literature. *Endocr Relat Cancer* 2014;21:R153-163. Available at: <https://www.ncbi.nlm.nih.gov/pubmed/24322304>.
4. Tsikitis VL, Wertheim BC, Guerrero MA. Trends of incidence and survival of gastrointestinal neuroendocrine tumors in the United States: a seer analysis. *J Cancer* 2012;3:292-302. Available at: <https://www.ncbi.nlm.nih.gov/pubmed/22773933>.
5. Hallet J, Law CH, Cukier M, et al. Exploring the rising incidence of neuroendocrine tumors: a population-based analysis of epidemiology, metastatic presentation, and outcomes. *Cancer* 2015;121:589-597. Available at: <https://www.ncbi.nlm.nih.gov/pubmed/25312765>.
6. Anlauf M, Garbrecht N, Bauersfeld J, et al. Hereditary neuroendocrine tumors of the gastroenteropancreatic system. *Virchows Arch* 2007;451 Suppl 1:S29-38. Available at: <https://www.ncbi.nlm.nih.gov/pubmed/17684762>.
7. Larson AM, Hedgire SS, Deshpande V, et al. Pancreatic neuroendocrine tumors in patients with tuberous sclerosis complex. *Clin Genet* 2012;82:558-563. Available at: <https://www.ncbi.nlm.nih.gov/pubmed/22035404>.
8. Marx S, Spiegel AM, Skarulis MC, et al. Multiple endocrine neoplasia type 1: clinical and genetic topics. *Ann Intern Med* 1998;129:484-494. Available at: <https://www.ncbi.nlm.nih.gov/pubmed/9735087>.
9. Donis-Keller H, Dou S, Chi D, et al. Mutations in the RET proto-oncogene are associated with MEN 2A and FMTC. *Hum Mol Genet* 1993;2:851-856. Available at: <https://www.ncbi.nlm.nih.gov/pubmed/8103403>.
10. Jenson RT, Norton JA. Carcinoid Tumors and Carcinoid Syndrome. In: DeVita VT, Hellman S, Rosenberg SA, eds. *Cancer: Principles and Practice of Oncology* Vol. Vol 2 (ed 6). Philadelphia, Pa: Lippincott Williams and Wilkins; 2001:1813-1826.
11. Joynt KE, Moslehi JJ, Baughman KL. Paragangliomas: etiology, presentation, and management. *Cardiol Rev* 2009;17:159-164. Available at: <https://www.ncbi.nlm.nih.gov/pubmed/19525677>.
12. Klimstra DS, Arnold R, Capella C, et al. Neuroendocrine Neoplasms of the Pancreas. In: Bosman FT, Carneiro, F., Hruban, R. H., Theise, N.D., ed. *WHO Classification of Tumours of the Digestive System* (ed 4th). Lyon: IARC; 2010:322-326.
13. U.S. National Library of Medicine-Key MEDLINE® Indicators. Available at: http://www.nlm.nih.gov/bsd/bsd_key.html. Accessed April 26, 2016.
14. Klimstra DS, Kloppel G, La Rosa S, et al. *WHO Classification of Tumors. Digestive System Tumours*. (ed 5th): International Agency for Research on Cancer; 2019.
15. *WHO Classification of Tumours of Endocrine Organs*. Vol. 10 (ed 4). Lyon, France: International Agency for Research on Cancer (IARC); 2017.
16. Rindi G, Kloppel G, Alhman H, et al. TNM staging of foregut (neuro)endocrine tumors: a consensus proposal including a grading system. *Virchows Arch* 2006;449:395-401. Available at: <https://www.ncbi.nlm.nih.gov/pubmed/16967267>.



NCCN Guidelines Version 4.2021

Neuroendocrine and Adrenal Tumors

17. Rindi G, Kloppel G, Couvelard A, et al. TNM staging of midgut and hindgut (neuro) endocrine tumors: a consensus proposal including a grading system. *Virchows Arch* 2007;451:757-762. Available at: <https://www.ncbi.nlm.nih.gov/pubmed/17674042>.

18. Marchevsky AM, Hendifar A, Walts AE. The use of Ki-67 labeling index to grade pulmonary well-differentiated neuroendocrine neoplasms: current best evidence. *Mod Pathol* 2018;31:1523-1531. Available at: <https://www.ncbi.nlm.nih.gov/pubmed/29802361>.

19. Rindi G, Klimstra DS, Abedi-Ardekani B, et al. A common classification framework for neuroendocrine neoplasms: an International Agency for Research on Cancer (IARC) and World Health Organization (WHO) expert consensus proposal. *Mod Pathol* 2018;31:1770-1786. Available at: <https://www.ncbi.nlm.nih.gov/pubmed/30140036>.

20. Hochwald SN, Zee S, Conlon KC, et al. Prognostic factors in pancreatic endocrine neoplasms: an analysis of 136 cases with a proposal for low-grade and intermediate-grade groups. *J Clin Oncol* 2002;20:2633-2642. Available at: <https://www.ncbi.nlm.nih.gov/pubmed/12039924>.

21. Panzuto F, Boninsegna L, Fazio N, et al. Metastatic and locally advanced pancreatic endocrine carcinomas: analysis of factors associated with disease progression. *J Clin Oncol* 2011;29:2372-2377. Available at: <https://www.ncbi.nlm.nih.gov/pubmed/21555696>.

22. Panzuto F, Nasoni S, Falconi M, et al. Prognostic factors and survival in endocrine tumor patients: comparison between gastrointestinal and pancreatic localization. *Endocr Relat Cancer* 2005;12:1083-1092. Available at: <http://www.ncbi.nlm.nih.gov/pubmed/16322345>.

23. Pape UF, Jann H, Muller-Nordhorn J, et al. Prognostic relevance of a novel TNM classification system for upper gastroenteropancreatic neuroendocrine tumors. *Cancer* 2008;113:256-265. Available at: <https://www.ncbi.nlm.nih.gov/pubmed/18506737>.

24. Rindi G, Bordi C, La Rosa S, et al. Gastroenteropancreatic (neuro)endocrine neoplasms: the histology report. *Dig Liver Dis* 2011;43

Suppl 4:S356-360. Available at: <https://www.ncbi.nlm.nih.gov/pubmed/21459341>.

25. Basturk O, Yang Z, Tang LH, et al. The high-grade (WHO G3) pancreatic neuroendocrine tumor category is morphologically and biologically heterogenous and includes both well differentiated and poorly differentiated neoplasms. *Am J Surg Pathol* 2015;39:683-690. Available at: <https://www.ncbi.nlm.nih.gov/pubmed/25723112>.

26. van Velthuysen ML, Groen EJ, van der Noort V, et al. Grading of neuroendocrine neoplasms: mitoses and Ki-67 are both essential. *Neuroendocrinology* 2014;100:221-227. Available at: <https://www.ncbi.nlm.nih.gov/pubmed/25358267>.

27. Travis WD, Colby TV, Corrin B, et al. Histological typing of lung and pleural tumours (ed 3): Springer-Verlag Berlin Heidelberg; 1999.

28. WHO Classification of Tumours of the Lung, Pleura, Thymus and Heart. Vol. 7 (ed 4th). Lyon, France: International Agency for Research on Cancer (IARC); 2015.

29. Marx A, Shimosato Y, Kuo TT, et al. Thymic neuroendocrine tumours. In: Travis WD BE, Muller-Hermelink HK, Harris CC, ed. WHO Classification of Tumours of the Lung, Pleura, Thymus and Heart. Lyon: IARC; 2004.

30. Beasley MB, Thunnissen FB, Hasleton PS, et al. Carcinoid tumour. In: Travis WD BE, Muller-Hermelink HK, Harris CC, ed. WHO Classification of Tumours of the Lung, Pleura, Thymus and Heart. Lyon: IARC; 2004.

31. Righi L, Gatti G, Volante M, Papotti M. Lung neuroendocrine tumors: pathological characteristics. *J Thorac Dis* 2017;9:S1442-S1447. Available at: <https://www.ncbi.nlm.nih.gov/pubmed/29201447>.

32. Klimstra DS. Pathology reporting of neuroendocrine tumors: essential elements for accurate diagnosis, classification, and staging. *Semin Oncol* 2013;40:23-36. Available at: <https://www.ncbi.nlm.nih.gov/pubmed/23391110>.



NCCN Guidelines Version 4.2021

Neuroendocrine and Adrenal Tumors

33. Kulke MH. Are neuroendocrine tumors going mainstream? J Clin Oncol 2013;31:404-405. Available at: <https://www.ncbi.nlm.nih.gov/pubmed/23248246>.

34. Sorbye H, Welin S, Langer SW, et al. Predictive and prognostic factors for treatment and survival in 305 patients with advanced gastrointestinal neuroendocrine carcinoma (WHO G3): the NORDIC NEC study. Ann Oncol 2013;24:152-160. Available at: <https://www.ncbi.nlm.nih.gov/pubmed/22967994>.

35. Scarpa A, Mantovani W, Capelli P, et al. Pancreatic endocrine tumors: improved TNM staging and histopathological grading permit a clinically efficient prognostic stratification of patients. Mod Pathol 2010;23:824-833. Available at: <https://www.ncbi.nlm.nih.gov/pubmed/20305616>.

36. Strosberg JR, Weber JM, Feldman M, et al. Prognostic validity of the American Joint Committee on Cancer staging classification for midgut neuroendocrine tumors. J Clin Oncol 2013;31:420-425. Available at: <https://www.ncbi.nlm.nih.gov/pubmed/23248248>.

37. Edge SB, Byrd DR, Compton CC, et al., eds. AJCC Cancer Staging Manual (ed 7th). New York: Springer; 2010.

38. Amin MB, Edge SB, Greene FL, et al. AJCC Cancer Staging Manual, 8th edition. New York: Springer; 2017.

39. Chagpar R, Chiang YJ, Xing Y, et al. Neuroendocrine tumors of the colon and rectum: prognostic relevance and comparative performance of current staging systems. Ann Surg Oncol 2013;20:1170-1178. Available at: <https://www.ncbi.nlm.nih.gov/pubmed/23212760>.

40. Landry CS, Woodall C, Scoggins CR, et al. Analysis of 900 appendiceal carcinoid tumors for a proposed predictive staging system. Arch Surg 2008;143:664-670; discussion 670. Available at: <https://www.ncbi.nlm.nih.gov/pubmed/18645109>.

41. Landry CS, Brock G, Scoggins CR, et al. A proposed staging system for rectal carcinoid tumors based on an analysis of 4701 patients. Surgery

2008;144:460-466. Available at: <https://www.ncbi.nlm.nih.gov/pubmed/18707046>.

42. Landry CS, Brock G, Scoggins CR, et al. A proposed staging system for small bowel carcinoid tumors based on an analysis of 6,380 patients. Am J Surg 2008;196:896-903; discussion 903. Available at: <https://www.ncbi.nlm.nih.gov/pubmed/19095106>.

43. Landry CS, Brock G, Scoggins CR, et al. Proposed staging system for colon carcinoid tumors based on an analysis of 2,459 patients. J Am Coll Surg 2008;207:874-881. Available at: <https://www.ncbi.nlm.nih.gov/pubmed/19183534>.

44. Landry CS, Brock G, Scoggins CR, et al. A proposed staging system for gastric carcinoid tumors based on an analysis of 1,543 patients. Ann Surg Oncol 2009;16:51-60. Available at: <https://www.ncbi.nlm.nih.gov/pubmed/18953609>.

45. Li X, Gou S, Liu Z, et al. Assessment of the American Joint Commission on Cancer 8th edition staging system for patients with pancreatic neuroendocrine tumors: A Surveillance, Epidemiology, and End Results analysis. Cancer Med 2018;7:626-634. Available at: <https://www.ncbi.nlm.nih.gov/pubmed/29380547>.

46. Kim MK, Warner RR, Roayaie S, et al. Revised staging classification improves outcome prediction for small intestinal neuroendocrine tumors. J Clin Oncol 2013;31:3776-3781. Available at: <https://www.ncbi.nlm.nih.gov/pubmed/24043726>.

47. Curran T, Pockaj BA, Gray RJ, et al. Importance of lymph node involvement in pancreatic neuroendocrine tumors: impact on survival and implications for surgical resection. J Gastrointest Surg 2015;19:152-160; discussion 160. Available at: <https://www.ncbi.nlm.nih.gov/pubmed/25118642>.

48. Qadan M, Ma Y, Visser BC, et al. Reassessment of the current American Joint Committee on Cancer staging system for pancreatic neuroendocrine tumors. J Am Coll Surg 2014;218:188-195. Available at: <https://www.ncbi.nlm.nih.gov/pubmed/24321190>.



NCCN Guidelines Version 4.2021

Neuroendocrine and Adrenal Tumors

49. Strosberg JR, Cheema A, Weber J, et al. Prognostic validity of a novel American Joint Committee on Cancer Staging Classification for pancreatic neuroendocrine tumors. *J Clin Oncol* 2011;29:3044-3049. Available at: <https://www.ncbi.nlm.nih.gov/pubmed/21709192>.
50. Bilimoria KY, Bentrem DJ, Merkow RP, et al. Application of the pancreatic adenocarcinoma staging system to pancreatic neuroendocrine tumors. *J Am Coll Surg* 2007;205:558-563. Available at: <https://www.ncbi.nlm.nih.gov/pubmed/17903729>.
51. Halfdanarson TR, Rabe KG, Rubin J, Petersen GM. Pancreatic neuroendocrine tumors (PNETs): incidence, prognosis and recent trend toward improved survival. *Ann Oncol* 2008;19:1727-1733. Available at: <https://www.ncbi.nlm.nih.gov/pubmed/18515795>.
52. Ballian N, Loeffler AG, Rajamanickam V, et al. A simplified prognostic system for resected pancreatic neuroendocrine neoplasms. *HPB (Oxford)* 2009;11:422-428. Available at: <https://www.ncbi.nlm.nih.gov/pubmed/19768147>.
53. Klimstra DS, Modlin IR, Adsay NV, et al. Pathology reporting of neuroendocrine tumors: application of the Delphic consensus process to the development of a minimum pathology data set. *Am J Surg Pathol* 2010;34:300-313. Available at: <https://www.ncbi.nlm.nih.gov/pubmed/20118772>.
54. Modlin IM, Kidd M, Malczewska A, et al. The NETest: The clinical utility of multigene blood analysis in the diagnosis and management of neuroendocrine tumors. *Endocrinol Metab Clin North Am* 2018;47:485-504. Available at: <https://www.ncbi.nlm.nih.gov/pubmed/30098712>.
55. Al-Toubah T, Cives M, Valone T, et al. Sensitivity and specificity of the NETest: A validation study. *Neuroendocrinology* 2020. Available at: <https://www.ncbi.nlm.nih.gov/pubmed/32615553>.
56. Qian ZR, Ter-Minassian M, Chan JA, et al. Prognostic significance of MTOR pathway component expression in neuroendocrine tumors. *J Clin Oncol* 2013;31:3418-3425. Available at: <https://www.ncbi.nlm.nih.gov/pubmed/23980085>.
57. Francis JM, Kiezun A, Ramos AH, et al. Somatic mutation of CDKN1B in small intestine neuroendocrine tumors. *Nat Genet* 2013;45:1483-1486. Available at: <https://www.ncbi.nlm.nih.gov/pubmed/24185511>.
58. Kim HS, Lee HS, Nam KH, et al. p27 loss is associated with poor prognosis in gastroenteropancreatic neuroendocrine tumors. *Cancer Res Treat* 2014;46:383-392. Available at: <https://www.ncbi.nlm.nih.gov/pubmed/25036575>.
59. Khan MS, Kirkwood A, Tsigani T, et al. Circulating tumor cells as prognostic markers in neuroendocrine tumors. *J Clin Oncol* 2013;31:365-372. Available at: <https://www.ncbi.nlm.nih.gov/pubmed/23248251>.
60. Oberg K, Modlin IM, De Herder W, et al. Consensus on biomarkers for neuroendocrine tumour disease. *Lancet Oncol* 2015;16:e435-e446. Available at: <https://www.ncbi.nlm.nih.gov/pubmed/26370353>.
61. Alexandraki KI, Grossman AB. The ectopic ACTH syndrome. *Rev Endocr Metab Disord* 2010;11:117-126. Available at: <https://www.ncbi.nlm.nih.gov/pubmed/20544290>.
62. Neary NM, Lopez-Chavez A, Abel BS, et al. Neuroendocrine ACTH-producing tumor of the thymus--experience with 12 patients over 25 years. *J Clin Endocrinol Metab* 2012;97:2223-2230. Available at: <https://www.ncbi.nlm.nih.gov/pubmed/22508705>.
63. Pasieka JL, McKinnon JG, Kinnear S, et al. Carcinoid syndrome symposium on treatment modalities for gastrointestinal carcinoid tumours: symposium summary. *Can J Surg* 2001;44:25-32. Available at: <https://www.ncbi.nlm.nih.gov/pubmed/11220795>.
64. Palaniswamy C, Frishman WH, Aronow WS. Carcinoid heart disease. *Cardiol Rev* 2012;20:167-176. Available at: <https://www.ncbi.nlm.nih.gov/pubmed/22314145>.
65. Choti MA, Bobiak S, Strosberg JR, et al. Prevalence of functional tumors in neuroendocrine carcinoma: An analysis from the NCCN NET database [abstract]. *ASCO Meeting Abstracts* 2012;30:4126. Available at: <http://meetinglibrary.asco.org/content/98670-114>.



NCCN Guidelines Version 4.2021

Neuroendocrine and Adrenal Tumors

66. Soga J, Yakuwa Y, Osaka M. Carcinoid syndrome: a statistical evaluation of 748 reported cases. *J Exp Clin Cancer Res* 1999;18:133-141. Available at: <https://www.ncbi.nlm.nih.gov/pubmed/10464698>.
67. Thorson AH. Studies on carcinoid disease. *Acta Med Scand Suppl* 1958;334:1-132. Available at: <https://www.ncbi.nlm.nih.gov/pubmed/13544882>.
68. Oberg KE, Reubi JC, Kwekkeboom DJ, Krenning EP. Role of somatostatins in gastroenteropancreatic neuroendocrine tumor development and therapy. *Gastroenterology* 2010;139:742-753, 753 e741. Available at: <https://www.ncbi.nlm.nih.gov/pubmed/20637207>.
69. Gabriel M, Decristoforo C, Kendler D, et al. 68Ga-DOTA-Tyr3-octreotide PET in neuroendocrine tumors: comparison with somatostatin receptor scintigraphy and CT. *J Nucl Med* 2007;48:508-518. Available at: <https://www.ncbi.nlm.nih.gov/pubmed/17401086>.
70. Sadowski SM, Neychev V, Millo C, et al. Prospective study of 68Ga-DOTATATE positron emission tomography/computed tomography for detecting gastro-entero-pancreatic neuroendocrine tumors and unknown primary sites. *J Clin Oncol* 2016;34:588-596. Available at: <https://www.ncbi.nlm.nih.gov/pubmed/26712231>.
71. Srirajaskanthan R, Kayani I, Quigley AM, et al. The role of 68Ga-DOTATATE PET in patients with neuroendocrine tumors and negative or equivocal findings on 111In-DTPA-octreotide scintigraphy. *J Nucl Med* 2010;51:875-882. Available at: <https://www.ncbi.nlm.nih.gov/pubmed/20484441>.
72. Haug AR, Cindea-Drimus R, Auernhammer CJ, et al. Neuroendocrine tumor recurrence: diagnosis with 68Ga-DOTATATE PET/CT. *Radiology* 2014;270:517-525. Available at: <https://www.ncbi.nlm.nih.gov/pubmed/24056402>.
73. Haug AR, Cindea-Drimus R, Auernhammer CJ, et al. The role of 68Ga-DOTATATE PET/CT in suspected neuroendocrine tumors. *J Nucl Med* 2012;53:1686-1692. Available at: <https://www.ncbi.nlm.nih.gov/pubmed/22984220>.
74. Singh S, Poon R, Wong R, Metser U. 68Ga PET imaging in patients with neuroendocrine tumors: A systematic review and meta-analysis. *Clin Nucl Med* 2018;43:802-810. Available at: <https://www.ncbi.nlm.nih.gov/pubmed/30247209>.
75. Deppen SA, Liu E, Blume JD, et al. Safety and efficacy of 68Ga-DOTATATE PET/CT for diagnosis, staging, and treatment management of neuroendocrine tumors. *J Nucl Med* 2016;57:708-714. Available at: <https://www.ncbi.nlm.nih.gov/pubmed/26769865>.
76. Hope TA, Bergsland EK, Bozkurt MF, et al. Appropriate use criteria for somatostatin receptor PET imaging in neuroendocrine tumors. *J Nucl Med* 2018;59:66-74. Available at: <https://www.ncbi.nlm.nih.gov/pubmed/29025982>.
77. Ayati N, Lee ST, Zakavi R, et al. Long-acting somatostatin analog therapy differentially alters (68)Ga-DOTATATE uptake in normal tissues compared with primary tumors and metastatic lesions. *J Nucl Med* 2018;59:223-227. Available at: <https://www.ncbi.nlm.nih.gov/pubmed/28729431>.
78. Yang X, Yang Y, Li Z, et al. Diagnostic value of circulating chromogranin a for neuroendocrine tumors: a systematic review and meta-analysis. *PLoS One* 2015;10:e0124884. Available at: <https://www.ncbi.nlm.nih.gov/pubmed/25894842>.
79. Florez JC, Shepard JA, Kradin RL. Case records of the Massachusetts General Hospital. Case 17-2013. A 56-year-old woman with poorly controlled diabetes mellitus and fatigue. *N Engl J Med* 2013;368:2126-2136. Available at: <https://www.ncbi.nlm.nih.gov/pubmed/23697472>.
80. Gilligan CJ, Lawton GP, Tang LH, et al. Gastric carcinoid tumors: the biology and therapy of an enigmatic and controversial lesion. *Am J Gastroenterol* 1995;90:338-352. Available at: <https://www.ncbi.nlm.nih.gov/pubmed/7872269>.
81. Cao LL, Lu J, Lin JX, et al. Incidence and survival trends for gastric neuroendocrine neoplasms: An analysis of 3523 patients in the SEER



NCCN Guidelines Version 4.2021

Neuroendocrine and Adrenal Tumors

database. Eur J Surg Oncol 2018;44:1628-1633. Available at: <https://www.ncbi.nlm.nih.gov/pubmed/29983275>.

82. Saund MS, Al Natour RH, Sharma AM, et al. Tumor size and depth predict rate of lymph node metastasis and utilization of lymph node sampling in surgically managed gastric carcinoids. Ann Surg Oncol 2011;18:2826-2832. Available at: <https://www.ncbi.nlm.nih.gov/pubmed/21455598>.

83. Bakhos CT, Salami AC, Kaiser LR, et al. Thymic neuroendocrine tumors and thymic carcinoma: Demographics, treatment, and survival. Innovations (Phila) 2020;15:468-474. Available at: <https://www.ncbi.nlm.nih.gov/pubmed/32938293>.

84. Filosso PL, Yao X, Ahmad U, et al. Outcome of primary neuroendocrine tumors of the thymus: a joint analysis of the International Thymic Malignancy Interest Group and the European Society of Thoracic Surgeons databases. J Thorac Cardiovasc Surg 2015;149:103-109 e102. Available at: <https://www.ncbi.nlm.nih.gov/pubmed/25308116>.

85. Rimner A, Yao X, Huang J, et al. Postoperative radiation therapy is associated with longer overall survival in completely resected stage II and III thymoma-An analysis of the International Thymic Malignancies Interest Group retrospective database. J Thorac Oncol 2016;11:1785-1792. Available at: <https://www.ncbi.nlm.nih.gov/pubmed/27346413>.

86. Man D, Wu J, Shen Z, Zhu X. Prognosis of patients with neuroendocrine tumor: a SEER database analysis. Cancer Manag Res 2018;10:5629-5638. Available at: <https://www.ncbi.nlm.nih.gov/pubmed/30519109>.

87. Chong CR, Wirth LJ, Nishino M, et al. Chemotherapy for locally advanced and metastatic pulmonary carcinoid tumors. Lung Cancer 2014;86:241-246. Available at: <https://www.ncbi.nlm.nih.gov/pubmed/25218177>.

88. Wirth LJ, Carter MR, Janne PA, Johnson BE. Outcome of patients with pulmonary carcinoid tumors receiving chemotherapy or

chemoradiotherapy. Lung Cancer 2004;44:213-220. Available at: <https://www.ncbi.nlm.nih.gov/pubmed/15084386>.

89. Fazio N, Granberg D, Grossman A, et al. Everolimus plus octreotide long-acting repeatable in patients with advanced lung neuroendocrine tumors: analysis of the phase 3, randomized, placebo-controlled RADIANT-2 study. Chest 2013;143:955-962. Available at: <https://www.ncbi.nlm.nih.gov/pubmed/23187897>.

90. Lassen U, Kristjansen PE, Osterlind K, et al. Superiority of cisplatin or carboplatin in combination with teniposide and vincristine in the induction chemotherapy of small-cell lung cancer. A randomized trial with 5 years follow up. Ann Oncol 1996;7:365-371. Available at: <https://www.ncbi.nlm.nih.gov/pubmed/8805928>.

91. Pietanza MC, Kadota K, Huberman K, et al. Phase II trial of temozolomide in patients with relapsed sensitive or refractory small cell lung cancer, with assessment of methylguanine-DNA methyltransferase as a potential biomarker. Clin Cancer Res 2012;18:1138-1145. Available at: <https://www.ncbi.nlm.nih.gov/pubmed/22228633>.

92. Zauderer MG, Drilon A, Kadota K, et al. Trial of a 5-day dosing regimen of temozolomide in patients with relapsed small cell lung cancers with assessment of methylguanine-DNA methyltransferase. Lung Cancer 2014;86:237-240. Available at: <https://www.ncbi.nlm.nih.gov/pubmed/25194640>.

93. Bian D, Qi M, Hu J, et al. The comparison of predictive factors regarding prognoses and invasion of thymic neuroendocrine tumors preoperatively and postoperatively. J Thorac Dis 2018;10:1657-1669. Available at: <https://www.ncbi.nlm.nih.gov/pubmed/29707318>.

94. Moertel CG, Weiland LH, Nagorney DM, Dockerty MB. Carcinoid tumor of the appendix: treatment and prognosis. N Engl J Med 1987;317:1699-1701. Available at: <https://www.ncbi.nlm.nih.gov/pubmed/3696178>.



NCCN Guidelines Version 4.2021

Neuroendocrine and Adrenal Tumors

95. Sandor A, Modlin IM. A retrospective analysis of 1570 appendiceal carcinoids. *Am J Gastroenterol* 1998;93:422-428. Available at: <https://www.ncbi.nlm.nih.gov/pubmed/9517651>.

96. Mullen JT, Savarese DM. Carcinoid tumors of the appendix: a population-based study. *J Surg Oncol* 2011;104:41-44. Available at: <https://www.ncbi.nlm.nih.gov/pubmed/21294132>.

97. Kleiman DA, Finnerty B, Beninato T, et al. Features associated with metastases among well-differentiated neuroendocrine (carcinoid) tumors of the appendix: The significance of small vessel invasion in addition to size. *Dis Colon Rectum* 2015;58:1137-1143. Available at: <https://www.ncbi.nlm.nih.gov/pubmed/26544810>.

98. Ricci C, Ingaldi C, Alberici L, et al. Histopathological diagnosis of appendiceal neuroendocrine neoplasms: when to perform a right hemicolectomy? A systematic review and meta-analysis. *Endocrine* 2019;66:460-466. Available at: <https://www.ncbi.nlm.nih.gov/pubmed/31227991>.

99. Gleeson FC, Levy MJ, Dozois EJ, et al. Endoscopically identified well-differentiated rectal carcinoid tumors: impact of tumor size on the natural history and outcomes. *Gastrointest Endosc* 2014;80:144-151. Available at: <https://www.ncbi.nlm.nih.gov/pubmed/24462168>.

100. Soga J. Carcinoids of the rectum: an evaluation of 1271 reported cases. *Surg Today* 1997;27:112-119. Available at: <https://www.ncbi.nlm.nih.gov/pubmed/9017986>.

101. Yao JC, Lombard-Bohas C, Baudin E, et al. Daily oral everolimus activity in patients with metastatic pancreatic neuroendocrine tumors after failure of cytotoxic chemotherapy: a phase II trial. *J Clin Oncol* 2010;28:69-76. Available at: <https://www.ncbi.nlm.nih.gov/pubmed/19933912>.

102. Massironi S, Rossi RE, Casazza G, et al. Chromogranin A in diagnosing and monitoring patients with gastroenteropancreatic neuroendocrine neoplasms: a large series from a single institution. *Neuroendocrinology* 2014;100:240-249. Available at: <https://www.ncbi.nlm.nih.gov/pubmed/25428270>.

103. Rossi RE, Ciafardini C, Sciola V, et al. Chromogranin A in the follow-up of gastroenteropancreatic neuroendocrine neoplasms: Is it really game over? A systematic review and meta-analysis. *Pancreas* 2018;47:1249-1255. Available at: <https://www.ncbi.nlm.nih.gov/pubmed/30325865>.

104. Ter-Minassian M, Chan JA, Hooshmand SM, et al. Clinical presentation, recurrence, and survival in patients with neuroendocrine tumors: results from a prospective institutional database. *Endocr Relat Cancer* 2013;20:187-196. Available at: <https://www.ncbi.nlm.nih.gov/pubmed/23319495>.

105. Joish VN, Shah S, Tierce JC, et al. Serotonin levels and 1-year mortality in patients with neuroendocrine tumors: a systematic review and meta-analysis. *Future Oncol* 2019;15:1397-1406. Available at: <https://www.ncbi.nlm.nih.gov/pubmed/30734573>.

106. Coskun H, Bostanci O, Dilege ME, et al. Carcinoid tumors of appendix: treatment and outcome. *Ulus Travma Acil Cerrahi Derg* 2006;12:150-154. Available at: <https://www.ncbi.nlm.nih.gov/pubmed/16676255>.

107. Murray SE, Lloyd RV, Sippel RS, et al. Postoperative surveillance of small appendiceal carcinoid tumors. *Am J Surg* 2014;207:342-345; discussion 345. Available at: <https://www.ncbi.nlm.nih.gov/pubmed/24393285>.

108. Shapiro R, Eldar S, Sadot E, et al. Appendiceal carcinoid at a large tertiary center: pathologic findings and long-term follow-up evaluation. *Am J Surg* 2011;201:805-808. Available at: <https://www.ncbi.nlm.nih.gov/pubmed/21741512>.

109. Cwikla JB, Buscombe JR, Caplin ME, et al. Diagnostic imaging of carcinoid metastases to the abdomen and pelvis. *Med Sci Monit* 2004;10 Suppl 3:9-16. Available at: <https://www.ncbi.nlm.nih.gov/pubmed/16538192>.

110. Kaltsas G, Rockall A, Papadogias D, et al. Recent advances in radiological and radionuclide imaging and therapy of neuroendocrine



NCCN Guidelines Version 4.2021

Neuroendocrine and Adrenal Tumors

tumours. Eur J Endocrinol 2004;151:15-27. Available at: <https://www.ncbi.nlm.nih.gov/pubmed/15248818>.

111. Kayani I, Conry BG, Groves AM, et al. A comparison of 68Ga-DOTATATE and 18F-FDG PET/CT in pulmonary neuroendocrine tumors. J Nucl Med 2009;50:1927-1932. Available at: <https://www.ncbi.nlm.nih.gov/pubmed/19910422>.

112. Fox DJ, Khattar RS. Carcinoid heart disease: presentation, diagnosis, and management. Heart 2004;90:1224-1228. Available at: <https://www.ncbi.nlm.nih.gov/pubmed/15367531>.

113. Davar J, Connolly HM, Caplin ME, et al. Diagnosing and managing carcinoid heart disease in patients with neuroendocrine tumors: An expert statement. J Am Coll Cardiol 2017;69:1288-1304. Available at: <https://www.ncbi.nlm.nih.gov/pubmed/28279296>.

114. Phan AT, Oberg K, Choi J, et al. NANETS consensus guideline for the diagnosis and management of neuroendocrine tumors: well-differentiated neuroendocrine tumors of the thorax (includes lung and thymus). Pancreas 2010;39:784-798. Available at: <https://www.ncbi.nlm.nih.gov/pubmed/20664476>.

115. Oberg K, Kvols L, Caplin M, et al. Consensus report on the use of somatostatin analogs for the management of neuroendocrine tumors of the gastroenteropancreatic system. Ann Oncol 2004;15:966-973. Available at: <https://www.ncbi.nlm.nih.gov/pubmed/15151956>.

116. Brentjens R, Saltz L. Islet cell tumors of the pancreas: the medical oncologist's perspective. Surg Clin North Am 2001;81:527-542. Available at: <https://www.ncbi.nlm.nih.gov/pubmed/11459269>.

117. Janson ET, Oberg K. Long-term management of the carcinoid syndrome. Treatment with octreotide alone and in combination with alpha-interferon. Acta Oncol 1993;32:225-229. Available at: <https://www.ncbi.nlm.nih.gov/pubmed/7686765>.

118. Kvols LK, Moertel CG, O'Connell MJ, et al. Treatment of the malignant carcinoid syndrome. Evaluation of a long-acting somatostatin

analogue. N Engl J Med 1986;315:663-666. Available at: <https://www.ncbi.nlm.nih.gov/pubmed/2427948>.

119. Khan MS, El-Khouly F, Davies P, et al. Long-term results of treatment of malignant carcinoid syndrome with prolonged release Lanreotide (Somatuline Autogel). Aliment Pharmacol Ther 2011;34:235-242. Available at: <https://www.ncbi.nlm.nih.gov/pubmed/21585408>.

120. O'Toole D, Ducreux M, Bommelaer G, et al. Treatment of carcinoid syndrome: a prospective crossover evaluation of lanreotide versus octreotide in terms of efficacy, patient acceptability, and tolerance. Cancer 2000;88:770-776. Available at: <https://www.ncbi.nlm.nih.gov/pubmed/10679645>.

121. Ruszniewski P, Ish-Shalom S, Wymenga M, et al. Rapid and sustained relief from the symptoms of carcinoid syndrome: results from an open 6-month study of the 28-day prolonged-release formulation of lanreotide. Neuroendocrinology 2004;80:244-251. Available at: <https://www.ncbi.nlm.nih.gov/pubmed/15627802>.

122. Ruszniewski P, Valle JW, Lombard-Bohas C, et al. Patient-reported outcomes with lanreotide Autogel/Depot for carcinoid syndrome: An international observational study. Dig Liver Dis 2016;48:552-558. Available at: <https://www.ncbi.nlm.nih.gov/pubmed/26917486>.

123. Wymenga AN, Eriksson B, Salmela PI, et al. Efficacy and safety of prolonged-release lanreotide in patients with gastrointestinal neuroendocrine tumors and hormone-related symptoms. J Clin Oncol 1999;17:1111. Available at: <https://www.ncbi.nlm.nih.gov/pubmed/10561168>.

124. Vinik AI, Wolin EM, Liyanage N, et al. Evaluation of lanreotide depot/autogel efficacy and safety as a carcinoid syndrome treatment (Elect): A randomized, double-blind, placebo-controlled trial. Endocr Pract 2016;22:1068-1080. Available at: <https://www.ncbi.nlm.nih.gov/pubmed/27214300>.

125. Fisher GA, Jr., Wolin EM, Liyanage N, et al. Lanreotide therapy in carcinoid syndrome: Prospective analysis of patient-reported symptoms in



NCCN Guidelines Version 4.2021

Neuroendocrine and Adrenal Tumors

patients responsive to prior octreotide therapy and patients naive to somatostatin analogue therapy in the Elect phase 3 study. *Endocr Pract* 2018;24:243-255. Available at:

<https://www.ncbi.nlm.nih.gov/pubmed/29547049>.

126. Kulke MH, O'Dorisio T, Phan A, et al. Telotristat etiprate, a novel serotonin synthesis inhibitor, in patients with carcinoid syndrome and diarrhea not adequately controlled by octreotide. *Endocr Relat Cancer* 2014;21:705-714. Available at:

<https://www.ncbi.nlm.nih.gov/pubmed/25012985>.

127. Pavel M, Horsch D, Caplin M, et al. Telotristat etiprate for carcinoid syndrome: a single-arm, multicenter trial. *J Clin Endocrinol Metab* 2015;100:1511-1519. Available at:

<https://www.ncbi.nlm.nih.gov/pubmed/25636046>.

128. Kulke MH, Horsch D, Caplin ME, et al. Telotristat ethyl, a tryptophan hydroxylase inhibitor for the treatment of carcinoid syndrome. *J Clin Oncol* 2017;35:14-23. Available at:

<https://www.ncbi.nlm.nih.gov/pubmed/27918724>.

129. Strosberg J, Joish VN, Giacalone S, et al. TELEPRO: Patient-reported carcinoid syndrome symptom improvement following initiation of telotristat ethyl in the real world. *Oncologist* 2019;24:1446-1452. Available at: <https://www.ncbi.nlm.nih.gov/pubmed/31189618>.

130. Anderson AS, Krauss D, Lang R. Cardiovascular complications of malignant carcinoid disease. *Am Heart J* 1997;134:693-702. Available at: <https://www.ncbi.nlm.nih.gov/pubmed/9351737>.

131. Jacobsen MB, Nitter-Hauge S, Bryde PE, Hanssen LE. Cardiac manifestations in mid-gut carcinoid disease. *Eur Heart J* 1995;16:263-268. Available at: <https://www.ncbi.nlm.nih.gov/pubmed/7538079>.

132. Bhattacharyya S, Toumpanakis C, Chilkunda D, et al. Risk factors for the development and progression of carcinoid heart disease. *Am J Cardiol* 2011;107:1221-1226. Available at: <https://www.ncbi.nlm.nih.gov/pubmed/21296329>.

133. Rinke A, Muller HH, Schade-Brittinger C, et al. Placebo-controlled, double-blind, prospective, randomized study on the effect of octreotide LAR in the control of tumor growth in patients with metastatic neuroendocrine midgut tumors: a report from the PROMID Study Group. *J Clin Oncol* 2009;27:4656-4663. Available at:

<https://www.ncbi.nlm.nih.gov/pubmed/19704057>.

134. Arnold R, Wittenberg M, Rinke A, et al. Placebo controlled, double blind, prospective, randomized study on the effect of octreotide LAR in the control of tumor growth in patients with metastatic neuroendocrine midgut tumors (PROMID): Results on long-term survival [abstract]. *ASCO Meeting Abstracts* 2013;31:4030. Available at:

<http://meetinglibrary.asco.org/content/115200-132>.

135. Rinke A, Wittenberg M, Schade-Brittinger C, et al. Placebo-controlled, double-blind, prospective, randomized study on the effect of octreotide LAR in the control of tumor growth in patients with metastatic neuroendocrine midgut tumors (PROMID): Results of long-term survival. *Neuroendocrinology* 2017;104:26-32. Available at:

<https://www.ncbi.nlm.nih.gov/pubmed/26731483>.

136. Caplin ME, Pavel M, Cwikla JB, et al. Lanreotide in metastatic enteropancreatic neuroendocrine tumors. *N Engl J Med* 2014;371:224-233. Available at: <https://www.ncbi.nlm.nih.gov/pubmed/25014687>.

137. Caplin ME, Pavel M, Cwikla JB, et al. Anti-tumour effects of lanreotide for pancreatic and intestinal neuroendocrine tumours: the CLARINET open-label extension study. *Endocr Relat Cancer* 2016;23:191-199. Available at:

<https://www.ncbi.nlm.nih.gov/pubmed/26743120>.

138. Ito T, Fujimori N, Honma Y, et al. Long-term safety and efficacy of lanreotide autogel in Japanese patients with neuroendocrine tumors: Final results of a phase II open-label extension study. *Asia Pac J Clin Oncol* 2020. Available at: <https://www.ncbi.nlm.nih.gov/pubmed/32757459>.

139. Glazer ES, Tseng JF, Al-Refaie W, et al. Long-term survival after surgical management of neuroendocrine hepatic metastases. *HPB*



NCCN Guidelines Version 4.2021

Neuroendocrine and Adrenal Tumors

(Oxford) 2011;12:427-433. Available at:

<http://www.ncbi.nlm.nih.gov/pubmed/20662794>.

140. Lesurtel M, Nagorney DM, Mazzaferro V, et al. When should a liver resection be performed in patients with liver metastases from neuroendocrine tumours? A systematic review with practice recommendations. HPB (Oxford) 2015;17:17-22. Available at: <https://www.ncbi.nlm.nih.gov/pubmed/24636662>.

141. Mayo SC, de Jong MC, Pulitano C, et al. Surgical management of hepatic neuroendocrine tumor metastasis: results from an international multi-institutional analysis. Ann Surg Oncol 2010;17:3129-3136. Available at: <https://www.ncbi.nlm.nih.gov/pubmed/20585879>.

142. Saxena A, Chua TC, Perera M, et al. Surgical resection of hepatic metastases from neuroendocrine neoplasms: a systematic review. Surg Oncol 2012;21:e131-141. Available at: <https://www.ncbi.nlm.nih.gov/pubmed/22658833>.

143. Daskalakis K, Karakatsanis A, Hessman O, et al. Association of a prophylactic surgical approach to stage IV small intestinal neuroendocrine tumors with survival. JAMA Oncol 2018;4:183-189. Available at: <https://www.ncbi.nlm.nih.gov/pubmed/29049611>.

144. Johnston FM, Mavros MN, Herman JM, Pawlik TM. Local therapies for hepatic metastases. J Natl Compr Canc Netw 2013;11:153-160. Available at: <https://www.ncbi.nlm.nih.gov/pubmed/23411382>.

145. Jones NB, Shah MH, Bloomston M. Liver-directed therapies in patients with advanced neuroendocrine tumors. J Natl Compr Canc Netw 2012;10:765-774. Available at: <https://www.ncbi.nlm.nih.gov/pubmed/22679118>.

146. Kennedy A, Bester L, Salem R, et al. Role of hepatic intra-arterial therapies in metastatic neuroendocrine tumours (NET): guidelines from the NET-Liver-Metastases Consensus Conference. HPB (Oxford) 2015;17:29-37. Available at: <https://www.ncbi.nlm.nih.gov/pubmed/25186181>.

147. Lewis MA, Hubbard J. Multimodal liver-directed management of neuroendocrine hepatic metastases. Int J Hepatol 2011;2011:452343. Available at: <https://www.ncbi.nlm.nih.gov/pubmed/22121491>.

148. Du S, Ni J, Weng L, et al. Aggressive Locoregional Treatment Improves the Outcome of Liver Metastases from Grade 3 Gastroenteropancreatic Neuroendocrine Tumors. Medicine (Baltimore) 2015;94:e1429. Available at: <https://www.ncbi.nlm.nih.gov/pubmed/26313798>.

149. Liu DM, Kennedy A, Turner D, et al. Minimally invasive techniques in management of hepatic neuroendocrine metastatic disease. Am J Clin Oncol 2009;32:200-215. Available at: <https://www.ncbi.nlm.nih.gov/pubmed/19346815>.

150. Mohan H, Nicholson P, Winter DC, et al. Radiofrequency ablation for neuroendocrine liver metastases: a systematic review. J Vasc Interv Radiol 2015;26:935-942 e931. Available at: <https://www.ncbi.nlm.nih.gov/pubmed/25840836>.

151. Siperstein AE, Rogers SJ, Hansen PD, Gitomirsky A. Laparoscopic thermal ablation of hepatic neuroendocrine tumor metastases. Surgery 1997;122:1147-1154; discussion 1154-1145. Available at: <https://www.ncbi.nlm.nih.gov/pubmed/9426432>.

152. Taner T, Atwell TD, Zhang L, et al. Adjunctive radiofrequency ablation of metastatic neuroendocrine cancer to the liver complements surgical resection. HPB (Oxford) 2013;15:190-195. Available at: <https://www.ncbi.nlm.nih.gov/pubmed/23374359>.

153. Strosberg JR, Weber JM, Choi J, et al. A phase II clinical trial of sunitinib following hepatic transarterial embolization for metastatic neuroendocrine tumors. Ann Oncol 2012;23:2335-2341. Available at: <https://www.ncbi.nlm.nih.gov/pubmed/22317769>.

154. Gates J, Hartnell GG, Stuart KE, Clouse ME. Chemoembolization of hepatic neoplasms: safety, complications, and when to worry. Radiographics 1999;19:399-414. Available at: <https://www.ncbi.nlm.nih.gov/pubmed/10194787>.



NCCN Guidelines Version 4.2021

Neuroendocrine and Adrenal Tumors

155. Hur S, Chung JW, Kim HC, et al. Survival outcomes and prognostic factors of transcatheter arterial chemoembolization for hepatic neuroendocrine metastases. *J Vasc Interv Radiol* 2013;24:947-956; quiz 957. Available at: <https://www.ncbi.nlm.nih.gov/pubmed/23602421>.

156. Ruszniewski P, Malka D. Hepatic arterial chemoembolization in the management of advanced digestive endocrine tumors. *Digestion* 2000;62 Suppl 1:79-83. Available at: <https://www.ncbi.nlm.nih.gov/pubmed/10940692>.

157. Devic Z, Rosenberg J, Braat AJ, et al. The efficacy of hepatic 90Y resin radioembolization for metastatic neuroendocrine tumors: a meta-analysis. *J Nucl Med* 2014;55:1404-1410. Available at: <https://www.ncbi.nlm.nih.gov/pubmed/25012459>.

158. Kennedy AS, Dezarn WA, McNeillie P, et al. Radioembolization for unresectable neuroendocrine hepatic metastases using resin 90Y-microspheres: early results in 148 patients. *Am J Clin Oncol* 2008;31:271-279. Available at: <http://www.ncbi.nlm.nih.gov/pubmed/18525307>.

159. Memon K, Lewandowski RJ, Mulcahy MF, et al. Radioembolization for neuroendocrine liver metastases: safety, imaging, and long-term outcomes. *Int J Radiat Oncol Biol Phys* 2012;83:887-894. Available at: <https://www.ncbi.nlm.nih.gov/pubmed/22137020>.

160. Braat A, Kappadath SC, Ahmadzadehfar H, et al. Radioembolization with (90)Y resin microspheres of neuroendocrine liver metastases: International multicenter study on efficacy and toxicity. *Cardiovasc Intervent Radiol* 2019;42:413-425. Available at: <https://www.ncbi.nlm.nih.gov/pubmed/30603975>.

161. Yao JC, Phan AT, Chang DZ, et al. Efficacy of RAD001 (everolimus) and octreotide LAR in advanced low- to intermediate-grade neuroendocrine tumors: results of a phase II study. *J Clin Oncol* 2008;26:4311-4318. Available at: <https://www.ncbi.nlm.nih.gov/pubmed/18779618>.

162. Pavel ME, Hainsworth JD, Baudin E, et al. Everolimus plus octreotide long-acting repeatable for the treatment of advanced neuroendocrine

tumours associated with carcinoid syndrome (RADIANT-2): a randomised, placebo-controlled, phase 3 study. *Lancet* 2011;378:2005-2012. Available at: <https://www.ncbi.nlm.nih.gov/pubmed/22119496>.

163. Pavel ME, Baudin E, Oberg KE, et al. Efficacy of everolimus plus octreotide LAR in patients with advanced neuroendocrine tumor and carcinoid syndrome: final overall survival from the randomized, placebo-controlled phase 3 RADIANT-2 study. *Ann Oncol* 2017;28:1569-1575. Available at: <https://www.ncbi.nlm.nih.gov/pubmed/28444114>.

164. Choueiri TK, Je Y, Sonpavde G, et al. Incidence and risk of treatment-related mortality in cancer patients treated with the mammalian target of rapamycin inhibitors. *Ann Oncol* 2013;24:2092-2097. Available at: <https://www.ncbi.nlm.nih.gov/pubmed/23658373>.

165. Parthivel K, Ramaiya N, Jagannathan JP, et al. Everolimus- and temsirolimus-associated enteritis: report of three cases. *J Clin Oncol* 2010;29:e404-406. Available at: <http://www.ncbi.nlm.nih.gov/pubmed/21357780>.

166. Subramaniam S, Zell JA, Kunz PL. Everolimus causing severe hypertriglyceridemia and acute pancreatitis. *J Natl Compr Canc Netw* 2013;11:5-9. Available at: <https://www.ncbi.nlm.nih.gov/pubmed/23307976>.

167. Yao JC, Fazio N, Singh S, et al. Everolimus for the treatment of advanced, non-functional neuroendocrine tumours of the lung or gastrointestinal tract (RADIANT-4): a randomised, placebo-controlled, phase 3 study. *Lancet* 2016;387:968-977. Available at: <https://www.ncbi.nlm.nih.gov/pubmed/26703889>.

168. Panzuto F, Rinzivillo M, Fazio N, et al. Real-world study of everolimus in advanced progressive neuroendocrine tumors. *Oncologist* 2014;19:966-974. Available at: <https://www.ncbi.nlm.nih.gov/pubmed/25117065>.

169. Fazio N, Buzzoni R, Delle Fave G, et al. Everolimus in advanced, progressive, well-differentiated, non-functional neuroendocrine tumors:



NCCN Guidelines Version 4.2021

Neuroendocrine and Adrenal Tumors

RADIANT-4 lung subgroup analysis. Cancer Sci 2018;109:174-181. Available at: <https://www.ncbi.nlm.nih.gov/pubmed/29055056>.

170. Pavel ME, Singh S, Strosberg JR, et al. Health-related quality of life for everolimus versus placebo in patients with advanced, non-functional, well-differentiated gastrointestinal or lung neuroendocrine tumours (RADIANT-4): a multicentre, randomised, double-blind, placebo-controlled, phase 3 trial. Lancet Oncol 2017;18:1411-1422. Available at: <https://www.ncbi.nlm.nih.gov/pubmed/28838862>.

171. Paulson AS, Bergsland EK. Systemic therapy for advanced carcinoid tumors: where do we go from here? J Natl Compr Canc Netw 2012;10:785-793. Available at: <https://www.ncbi.nlm.nih.gov/pubmed/22679120>.

172. Medley L, Morel AN, Farrugia D, et al. Phase II study of single agent capecitabine in the treatment of metastatic non-pancreatic neuroendocrine tumours. Br J Cancer 2011;104:1067-1070. Available at: <https://www.ncbi.nlm.nih.gov/pubmed/21386841>.

173. Bajetta E, Catena L, Procopio G, et al. Are capecitabine and oxaliplatin (XELOX) suitable treatments for progressing low-grade and high-grade neuroendocrine tumours? Cancer Chemother Pharmacol 2007;59:637-642. Available at: <https://www.ncbi.nlm.nih.gov/pubmed/16937105>.

174. Sun W, Lipsitz S, Catalano P, et al. Phase II/III study of doxorubicin with fluorouracil compared with streptozocin with fluorouracil or dacarbazine in the treatment of advanced carcinoid tumors: Eastern Cooperative Oncology Group Study E1281. J Clin Oncol 2005;23:4897-4904. Available at: <https://www.ncbi.nlm.nih.gov/pubmed/16051944>.

175. Ekeblad S, Sundin A, Janson ET, et al. Temozolomide as monotherapy is effective in treatment of advanced malignant neuroendocrine tumors. Clin Cancer Res 2007;13:2986-2991. Available at: <https://www.ncbi.nlm.nih.gov/pubmed/17505000>.

176. Mitry E, Walter T, Baudin E, et al. Bevacizumab plus capecitabine in patients with progressive advanced well-differentiated neuroendocrine

tumors of the gastro-intestinal (GI-NETs) tract (BETTER trial)--a phase II non-randomised trial. Eur J Cancer 2014;50:3107-3115. Available at: <https://www.ncbi.nlm.nih.gov/pubmed/25454413>.

177. Kunz PL, Balise RR, Fehrenbacher L, et al. Oxaliplatin-fluoropyrimidine chemotherapy plus bevacizumab in advanced neuroendocrine tumors: An analysis of 2 phase II trials. Pancreas 2016;45:1394-1400. Available at: <https://www.ncbi.nlm.nih.gov/pubmed/27171514>.

178. Crona J, Fanola I, Lindholm DP, et al. Effect of temozolomide in patients with metastatic bronchial carcinoids. Neuroendocrinology 2013;98:151-155. Available at: <https://www.ncbi.nlm.nih.gov/pubmed/23969949>.

179. Al-Toubah T, Morse B, Strosberg J. Capecitabine and temozolomide in advanced lung neuroendocrine neoplasms. Oncologist 2020;25:e48-e52. Available at: <https://www.ncbi.nlm.nih.gov/pubmed/31455747>.

180. Papaxoinis G, Kordatou Z, McCallum L, et al. Capecitabine and temozolomide in patients with advanced pulmonary carcinoid tumours. Neuroendocrinology 2020;110:413-421. Available at: <https://www.ncbi.nlm.nih.gov/pubmed/31437838>.

181. Imhof A, Brunner P, Marincek N, et al. Response, survival, and long-term toxicity after therapy with the radiolabeled somatostatin analogue [90Y-DOTA]-TOC in metastasized neuroendocrine cancers. J Clin Oncol 2011;29:2416-2423. Available at: <https://www.ncbi.nlm.nih.gov/pubmed/21555692>.

182. Krenning EP, Teunissen JJ, Valkema R, et al. Molecular radiotherapy with somatostatin analogs for (neuro-)endocrine tumors. J Endocrinol Invest 2005;28:146-150. Available at: <https://www.ncbi.nlm.nih.gov/pubmed/16625865>.

183. Kwekkeboom DJ, Bakker WH, Kam BL, et al. Treatment of patients with gastro-entero-pancreatic (GEP) tumours with the novel radiolabelled somatostatin analogue [177Lu-DOTA(0),Tyr3]octreotate. Eur J Nucl Med



NCCN Guidelines Version 4.2021

Neuroendocrine and Adrenal Tumors

Mol Imaging 2003;30:417-422. Available at:
<https://www.ncbi.nlm.nih.gov/pubmed/12634971>.

184. Kwekkeboom DJ, Teunissen JJ, Bakker WH, et al. Radiolabeled somatostatin analog [(177)Lu-DOTA0,Tyr3]octreotate in patients with endocrine gastroenteropancreatic tumors. J Clin Oncol 2005;23:2754-2762. Available at: <https://www.ncbi.nlm.nih.gov/pubmed/15837990>.

185. Kwekkeboom DJ, Teunissen JJM, Kam BL, et al. Treatment of patients who have endocrine gastroenteropancreatic tumors with radiolabeled somatostatin analogues. Hematol Oncol Clin North Am 2007;21:561-573. Available at:
<http://www.ncbi.nlm.nih.gov/pubmed/17548040>.

186. Bushnell DL, Jr., O'Dorisio TM, O'Dorisio MS, et al. 90Y-edotreotide for metastatic carcinoid refractory to octreotide. J Clin Oncol 2010;28:1652-1659. Available at:
<https://www.ncbi.nlm.nih.gov/pubmed/20194865>.

187. Kong G, Thompson M, Collins M, et al. Assessment of predictors of response and long-term survival of patients with neuroendocrine tumour treated with peptide receptor chemoradionuclide therapy (PRCRT). Eur J Nucl Med Mol Imaging 2014;41:1831-1844. Available at:
<https://www.ncbi.nlm.nih.gov/pubmed/24844348>.

188. Villard L, Romer A, Marincek N, et al. Cohort study of somatostatin-based radiopeptide therapy with [(90)Y-DOTA]-TOC versus [(90)Y-DOTA]-TOC plus [(177)Lu-DOTA]-TOC in neuroendocrine cancers. J Clin Oncol 2012;30:1100-1106. Available at:
<https://www.ncbi.nlm.nih.gov/pubmed/22393097>.

189. Horsch D, Ezziddin S, Haug A, et al. Peptide receptor radionuclide therapy for neuroendocrine tumors in Germany: first results of a multi-institutional cancer registry. Recent Results Cancer Res 2013;194:457-465. Available at: <https://www.ncbi.nlm.nih.gov/pubmed/22918775>.

190. Strosberg J, El-Haddad G, Wolin E, et al. Phase 3 trial of (177)Lu-Dotatate for midgut neuroendocrine tumors. N Engl J Med 2017;376:125-135. Available at: <https://www.ncbi.nlm.nih.gov/pubmed/28076709>.

191. Brabander T, van der Zwan WA, Teunissen JJM, et al. Long-term efficacy, survival, and safety of [(177)Lu-DOTA(0),Tyr(3)]octreotate in patients with gastroenteropancreatic and bronchial neuroendocrine tumors. Clin Cancer Res 2017;23:4617-4624. Available at:
<https://www.ncbi.nlm.nih.gov/pubmed/28428192>.

192. Mariniello A, Bodei L, Tinelli C, et al. Long-term results of PRRT in advanced bronchopulmonary carcinoid. Eur J Nucl Med Mol Imaging 2016;43:441-452. Available at:
<https://www.ncbi.nlm.nih.gov/pubmed/26392198>.

193. Ianniello A, Sansovini M, Severi S, et al. Peptide receptor radionuclide therapy with (177)Lu-DOTATATE in advanced bronchial carcinoids: prognostic role of thyroid transcription factor 1 and (18)F-FDG PET. Eur J Nucl Med Mol Imaging 2016;43:1040-1046. Available at:
<https://www.ncbi.nlm.nih.gov/pubmed/26611427>.

194. Lutetium Lu 177 dotatate [package insert]. Millburn, NJ: Advanced Accelerator Applications USA, Inc. 2018. Available at:
<https://dailymed.nlm.nih.gov/dailymed/drugInfo.cfm?setid=72d1a024-00b7-418a-b36e-b2cb48f2ab55>.

195. Saravana-Bawan B, Bajwa A, Paterson J, et al. Efficacy of 177Lu peptide receptor radionuclide therapy for the treatment of neuroendocrine tumors: A Meta-analysis. Clin Nucl Med 2019;44:719-727. Available at:
<https://www.ncbi.nlm.nih.gov/pubmed/31205149>.

196. Bonaccorsi-Riani E, Apestegui C, Jouret-Mourin A, et al. Liver transplantation and neuroendocrine tumors: lessons from a single centre experience and from the literature review. Transpl Int 2010;23:668-678. Available at: <https://www.ncbi.nlm.nih.gov/pubmed/20478000>.

197. Gedaly R, Daily MF, Davenport D, et al. Liver transplantation for the treatment of liver metastases from neuroendocrine tumors: an analysis of the UNOS database. Arch Surg 2011;146:953-958. Available at:
<https://www.ncbi.nlm.nih.gov/pubmed/21844436>.



NCCN Guidelines Version 4.2021

Neuroendocrine and Adrenal Tumors

198. Lehnert T. Liver transplantation for metastatic neuroendocrine carcinoma: an analysis of 103 patients. *Transplantation* 1998;66:1307-1312. Available at: <https://www.ncbi.nlm.nih.gov/pubmed/9846513>.

199. Le Treut YP, Gregoire E, Belghiti J, et al. Predictors of long-term survival after liver transplantation for metastatic endocrine tumors: an 85-case French multicentric report. *Am J Transplant* 2008;8:1205-1213. Available at: <https://www.ncbi.nlm.nih.gov/pubmed/18444921>.

200. Le Treut YP, Gregoire E, Klempnauer J, et al. Liver transplantation for neuroendocrine tumors in Europe-results and trends in patient selection: a 213-case European liver transplant registry study. *Ann Surg* 2013;257:807-815. Available at: <https://www.ncbi.nlm.nih.gov/pubmed/23532105>.

201. Rosenau J, Bahr MJ, von Wasielewski R, et al. Ki67, E-cadherin, and p53 as prognostic indicators of long-term outcome after liver transplantation for metastatic neuroendocrine tumors. *Transplantation* 2002;73:386-394. Available at: <http://www.ncbi.nlm.nih.gov/pubmed/11884935>.

202. Sher LS, Levi DM, Wechsler JS, et al. Liver transplantation for metastatic neuroendocrine tumors: Outcomes and prognostic variables. *J Surg Oncol* 2015;112:125-132. Available at: <https://www.ncbi.nlm.nih.gov/pubmed/26171686>.

203. Rossi RE, Burroughs AK, Caplin ME. Liver transplantation for unresectable neuroendocrine tumor liver metastases. *Ann Surg Oncol* 2014;21:2398-2405. Available at: <https://www.ncbi.nlm.nih.gov/pubmed/24562931>.

204. Travis WD. Advances in neuroendocrine lung tumors. *Ann Oncol* 2010;21 Suppl 7:vii65-71. Available at: <https://www.ncbi.nlm.nih.gov/pubmed/20943645>.

205. Yao JC, Eisner MP, Leary C, et al. Population-based study of islet cell carcinoma. *Ann Surg Oncol* 2007;14:3492-3500. Available at: <https://www.ncbi.nlm.nih.gov/pubmed/17896148>.

206. Moore FD, Scoinski MA, Joste NE. Endocrine Tumors and Malignancies. In: Skarin A, ed. *Atlas of Diagnostic Oncology* (ed 3rd). Philadelphia: Elsevier Science Limited; 2003.

207. Rehfeld JF, Federspiel B, Bardram L. A neuroendocrine tumor syndrome from cholecystikinin secretion. *N Engl J Med* 2013;368:1165-1166. Available at: <https://www.ncbi.nlm.nih.gov/pubmed/23514309>.

208. Alexakis N, Neoptolemos JP. Pancreatic neuroendocrine tumours. *Best Pract Res Clin Gastroenterol* 2008;22:183-205. Available at: <https://www.ncbi.nlm.nih.gov/pubmed/18206821>.

209. James PD, Tsolakis AV, Zhang M, et al. Incremental benefit of preoperative EUS for the detection of pancreatic neuroendocrine tumors: a meta-analysis. *Gastrointest Endosc* 2015;81:848-856 e841. Available at: <https://www.ncbi.nlm.nih.gov/pubmed/25805462>.

210. Kulke MH, Bendell J, Kvols L, et al. Evolving diagnostic and treatment strategies for pancreatic neuroendocrine tumors. *J Hematol Oncol* 2011;4:29. Available at: <https://www.ncbi.nlm.nih.gov/pubmed/21672194>.

211. Bernini GP, Moretti A, Ferdeghini M, et al. A new human chromogranin 'A' immunoradiometric assay for the diagnosis of neuroendocrine tumours. *Br J Cancer* 2001;84:636-642. Available at: <https://www.ncbi.nlm.nih.gov/pubmed/11237384>.

212. Campana D, Nori F, Piscitelli L, et al. Chromogranin A: is it a useful marker of neuroendocrine tumors? *J Clin Oncol* 2007;25:1967-1973. Available at: <https://www.ncbi.nlm.nih.gov/pubmed/17513802>.

213. Nehar D, Lombard-Bohas C, Olivieri S, et al. Interest of Chromogranin A for diagnosis and follow-up of endocrine tumours. *Clin Endocrinol (Oxf)* 2004;60:644-652. Available at: <https://www.ncbi.nlm.nih.gov/pubmed/15104570>.

214. Yao JC, Pavel M, Phan AT, et al. Chromogranin A and neuron-specific enolase as prognostic markers in patients with advanced pNET



NCCN Guidelines Version 4.2021

Neuroendocrine and Adrenal Tumors

treated with everolimus. *J Clin Endocrinol Metab* 2011;96:3741-3749. Available at: <https://www.ncbi.nlm.nih.gov/pubmed/21994954>.

215. Jensen RT, Fraker DL. Zollinger-Ellison syndrome. Advances in treatment of gastric hypersecretion and the gastrinoma. *JAMA* 1994;271:1429-1435. Available at: <https://www.ncbi.nlm.nih.gov/pubmed/7513768>.

216. Osefo N, Ito T, Jensen RT. Gastric acid hypersecretory states: recent insights and advances. *Curr Gastroenterol Rep* 2009;11:433-441. Available at: <https://www.ncbi.nlm.nih.gov/pubmed/19903418>.

217. Cryer PE, Axelrod L, Grossman AB, et al. Evaluation and management of adult hypoglycemic disorders: an Endocrine Society Clinical Practice Guideline. *J Clin Endocrinol Metab* 2009;94:709-728. Available at: <https://www.ncbi.nlm.nih.gov/pubmed/19088155>.

218. Doppman JL, Chang R, Fraker DL, et al. Localization of insulinomas to regions of the pancreas by intra-arterial stimulation with calcium. *Ann Intern Med* 1995;123:269-273. Available at: <https://www.ncbi.nlm.nih.gov/pubmed/7611592>.

219. Stehouwer CD, Lems WF, Fischer HR, et al. Aggravation of hypoglycemia in insulinoma patients by the long-acting somatostatin analogue octreotide (Sandostatin). *Acta Endocrinol (Copenh)* 1989;121:34-40. Available at: <https://www.ncbi.nlm.nih.gov/pubmed/2545062>.

220. Lee LC, Grant CS, Salomao DR, et al. Small, nonfunctioning, asymptomatic pancreatic neuroendocrine tumors (PNETs): role for nonoperative management. *Surgery* 2012;152:965-974. Available at: <https://www.ncbi.nlm.nih.gov/pubmed/23102679>.

221. Strosberg JR, Cheema A, Kvols LK. Stage I nonfunctioning neuroendocrine tumors of the pancreas: Surgery or surveillance? *Journal of Clinical Oncology* 2011;29:349-349. Available at: http://ascopubs.org/doi/abs/10.1200/jco.2011.29.4_suppl.349.

222. Cherenfant J, Stocker SJ, Gage MK, et al. Predicting aggressive behavior in nonfunctioning pancreatic neuroendocrine tumors. *Surgery* 2013;154:785-791; discussion 791-783. Available at: <https://www.ncbi.nlm.nih.gov/pubmed/24074416>.

223. Haynes AB, Deshpande V, Ingkakul T, et al. Implications of incidentally discovered, nonfunctioning pancreatic endocrine tumors: short-term and long-term patient outcomes. *Arch Surg* 2011;146:534-538. Available at: <https://www.ncbi.nlm.nih.gov/pubmed/21576607>.

224. Kuo EJ, Salem RR. Population-level analysis of pancreatic neuroendocrine tumors 2 cm or less in size. *Ann Surg Oncol* 2013;20:2815-2821. Available at: <https://www.ncbi.nlm.nih.gov/pubmed/23771245>.

225. Regenet N, Carrere N, Boulanger G, et al. Is the 2-cm size cutoff relevant for small nonfunctioning pancreatic neuroendocrine tumors: A French multicenter study. *Surgery* 2016;159:901-907. Available at: <https://www.ncbi.nlm.nih.gov/pubmed/26590096>.

226. Sadot E, Reidy-Lagunes DL, Tang LH, et al. Observation versus resection for small asymptomatic pancreatic neuroendocrine tumors: A matched case-control study. *Ann Surg Oncol* 2016;23:1361-1370. Available at: <https://www.ncbi.nlm.nih.gov/pubmed/26597365>.

227. Ferrone CR, Tang LH, Tomlinson J, et al. Determining prognosis in patients with pancreatic endocrine neoplasms: can the WHO classification system be simplified? *J Clin Oncol* 2007;25:5609-5615. Available at: <https://www.ncbi.nlm.nih.gov/pubmed/18065733>.

228. Parekh JR, Wang SC, Bergsland EK, et al. Lymph node sampling rates and predictors of nodal metastases in pancreatic neuroendocrine tumor resections: the UCSF experience with 149 patients. *Pancreas* 2012;41:840-844. Available at: <http://www.ncbi.nlm.nih.gov/pubmed/22781907>.

229. Tsutsumi K, Ohtsuka T, Mori Y, et al. Analysis of lymph node metastasis in pancreatic neuroendocrine tumors (PNETs) based on the



NCCN Guidelines Version 4.2021

Neuroendocrine and Adrenal Tumors

tumor size and hormonal production. J Gastroenterol 2012;47:678-685. Available at: <https://www.ncbi.nlm.nih.gov/pubmed/22350698>.

230. Su AP, Ke NW, Zhang Y, et al. Is laparoscopic approach for pancreatic insulinomas safe? Results of a systematic review and meta-analysis. J Surg Res 2014;186:126-134. Available at: <https://www.ncbi.nlm.nih.gov/pubmed/23992857>.

231. Eldor R, Glaser B, Fraenkel M, et al. Glucagonoma and the glucagonoma syndrome - cumulative experience with an elusive endocrine tumour. Clin Endocrinol (Oxf) 2011;74:593-598. Available at: <https://www.ncbi.nlm.nih.gov/pubmed/21470282>.

232. Castro PG, de Leon AM, Trancon JG, et al. Glucagonoma syndrome: a case report. J Med Case Rep 2011;5:402. Available at: <https://www.ncbi.nlm.nih.gov/pubmed/21859461>.

233. Boninsegna L, Panzuto F, Partelli S, et al. Malignant pancreatic neuroendocrine tumour: lymph node ratio and Ki67 are predictors of recurrence after curative resections. Eur J Cancer 2012;48:1608-1615. Available at: <https://www.ncbi.nlm.nih.gov/pubmed/22129889>.

234. Casadei R, Ricci C, Pezzilli R, et al. Are there prognostic factors related to recurrence in pancreatic endocrine tumors? Pancreatolgy 2010;10:33-38. Available at: <http://www.ncbi.nlm.nih.gov/pubmed/20299821>.

235. Kim SJ, Kim JW, Oh DY, et al. Clinical course of neuroendocrine tumors with different origins (the pancreas, gastrointestinal tract, and lung). Am J Clin Oncol 2011;35:549-556. Available at: <http://www.ncbi.nlm.nih.gov/pubmed/21659833>.

236. Singh S, Moody L, Chan DL, et al. Follow-up recommendations for completely resected gastroenteropancreatic neuroendocrine tumors. JAMA Oncol 2018;4:1597-1604. Available at: <https://www.ncbi.nlm.nih.gov/pubmed/30054622>.

237. Strosberg JR, Cheema A, Weber JM, et al. Relapse-free survival in patients with nonmetastatic, surgically resected pancreatic neuroendocrine

tumors: an analysis of the AJCC and ENETS staging classifications. Ann Surg 2012;256:321-325. Available at: <https://www.ncbi.nlm.nih.gov/pubmed/22415420>.

238. De Jong MC, Farnell MB, Sclabas G, et al. Liver-directed therapy for hepatic metastases in patients undergoing pancreaticoduodenectomy: a dual-center analysis. Ann Surg 2010;252:142-148. Available at: <https://www.ncbi.nlm.nih.gov/pubmed/20531007>.

239. Yao JC, Shah MH, Ito T, et al. Everolimus for advanced pancreatic neuroendocrine tumors. N Engl J Med 2011;364:514-523. Available at: <https://www.ncbi.nlm.nih.gov/pubmed/21306238>.

240. Lombard-Bohas C, Yao JC, Hobday T, et al. Impact of prior chemotherapy use on the efficacy of everolimus in patients with advanced pancreatic neuroendocrine tumors: a subgroup analysis of the phase III RADIANT-3 trial. Pancreas 2015;44:181-189. Available at: <https://www.ncbi.nlm.nih.gov/pubmed/25479584>.

241. Pommier R, Pavel M, Lombard-Bohas C, et al. Everolimus for the treatment of advanced pancreatic neuroendocrine tumors (pNET): Final overall survival (OS) results of the RADIANT-3 study. Gastrointest Cancer Res 2014;7:S29-S31. Available at: <https://www.ncbi.nlm.nih.gov/pmc/articles/PMC4812836/pdf/gcrs29.pdf>.

242. Kulke MH, Bergsland EK, Yao JC. Glycemic control in patients with insulinoma treated with everolimus. N Engl J Med 2009;360:195-197. Available at: <https://www.ncbi.nlm.nih.gov/pubmed/19129539>.

243. Raymond E, Dahan L, Raoul JL, et al. Sunitinib malate for the treatment of pancreatic neuroendocrine tumors. N Engl J Med 2011;364:501-513. Available at: <https://www.ncbi.nlm.nih.gov/pubmed/21306237>.

244. Raymond E, Niccoli P, Raoul J, et al. Updated overall survival (OS) and progression-free survival (PFS) by blinded independent central review (BICR) of sunitinib (SU) versus placebo (PBO) for patients (Pts) with advanced unresectable pancreatic neuroendocrine tumors (NET). Journal



NCCN Guidelines Version 4.2021

Neuroendocrine and Adrenal Tumors

of Clinical Oncology 2011;29:4008-4008. Available at: http://ascopubs.org/doi/abs/10.1200/jco.2011.29.15_suppl.4008.

245. Valle JW, Borbath I, Rosbrook B, et al. Sunitinib in patients with pancreatic neuroendocrine tumors: update of safety data. *Future Oncol* 2019;15:1219-1230. Available at: <https://www.ncbi.nlm.nih.gov/pubmed/30701988>.

246. Richards CJ, Je Y, Schutz FA, et al. Incidence and risk of congestive heart failure in patients with renal and nonrenal cell carcinoma treated with sunitinib. *J Clin Oncol* 2011;29:3450-3456. Available at: <https://www.ncbi.nlm.nih.gov/pubmed/21810682>.

247. Sutent® (sunitinib malate) capsule [prescribing information]. New York, NY: Pfizer Laboratories. 2017. Available at: <http://labeling.pfizer.com/showlabeling.aspx?id=607>.

248. Schutz FA, Je Y, Richards CJ, Choueiri TK. Meta-analysis of randomized controlled trials for the incidence and risk of treatment-related mortality in patients with cancer treated with vascular endothelial growth factor tyrosine kinase inhibitors. *J Clin Oncol* 2012;30:871-877. Available at: <https://www.ncbi.nlm.nih.gov/pubmed/22312105>.

249. Safety information: Sutent (sunitinib malate) capsules. FDA; 2015. Available at: <https://wayback.archive-it.org/7993/20161023083541/http://www.fda.gov/Safety/MedWatch/SafetyInformation/ucm224050.htm>. Accessed March 27, 2017.

250. Jonasch E, Donskov F, Iliopoulos O, et al. Belzutifan for renal cell carcinoma in von Hippel-Lindau disease. *N Engl J Med* 2021;385:2036-2046. Available at: <https://www.ncbi.nlm.nih.gov/pubmed/34818478>.

251. Moertel CG, Lefkopoulo M, Lipsitz S, et al. Streptozocin-doxorubicin, streptozocin-fluorouracil or chlorozotocin in the treatment of advanced islet-cell carcinoma. *N Engl J Med* 1992;326:519-523. Available at: <https://www.ncbi.nlm.nih.gov/pubmed/1310159>.

252. Kouvaraki MA, Ajani JA, Hoff P, et al. Fluorouracil, doxorubicin, and streptozocin in the treatment of patients with locally advanced and

metastatic pancreatic endocrine carcinomas. *J Clin Oncol* 2004;22:4762-4771. Available at: <https://www.ncbi.nlm.nih.gov/pubmed/15570077>.

253. Ducreux M, Dahan L, Smith D, et al. Bevacizumab combined with 5-FU/streptozocin in patients with progressive metastatic well-differentiated pancreatic endocrine tumours (BETTER trial)--a phase II non-randomised trial. *Eur J Cancer* 2014;50:3098-3106. Available at: <https://www.ncbi.nlm.nih.gov/pubmed/25454412>.

254. Chan JA, Stuart K, Earle CC, et al. Prospective study of bevacizumab plus temozolomide in patients with advanced neuroendocrine tumors. *J Clin Oncol* 2012;30:2963-2968. Available at: <https://www.ncbi.nlm.nih.gov/pubmed/22778320>.

255. Kulke MH, Stuart K, Enzinger PC, et al. Phase II study of temozolomide and thalidomide in patients with metastatic neuroendocrine tumors. *J Clin Oncol* 2006;24:401-406. Available at: <https://www.ncbi.nlm.nih.gov/pubmed/16421420>.

256. Kulke MH, Hornick JL, Fraumeni C, et al. O6-methylguanine DNA methyltransferase deficiency and response to temozolomide-based therapy in patients with neuroendocrine tumors. *Clin Cancer Res* 2009;15:338-345. Available at: <https://www.ncbi.nlm.nih.gov/pubmed/19118063>.

257. Strosberg JR, Fine RL, Choi J, et al. First-line chemotherapy with capecitabine and temozolomide in patients with metastatic pancreatic endocrine carcinomas. *Cancer* 2011;117:268-275. Available at: <https://www.ncbi.nlm.nih.gov/pubmed/20824724>.

258. Fine RL, Gulati AP, Krantz BA, et al. Capecitabine and temozolomide (CAPTEM) for metastatic, well-differentiated neuroendocrine cancers: The Pancreas Center at Columbia University experience. *Cancer Chemother Pharmacol* 2013;71:663-670. Available at: <https://www.ncbi.nlm.nih.gov/pubmed/23370660>.

259. Lu Y, Zhao Z, Wang J, et al. Safety and efficacy of combining capecitabine and temozolomide (CAPTEM) to treat advanced neuroendocrine neoplasms: A meta-analysis. *Medicine (Baltimore)*



NCCN Guidelines Version 4.2021

Neuroendocrine and Adrenal Tumors

2018;97:e12784. Available at:

<https://www.ncbi.nlm.nih.gov/pubmed/30313101>.

260. Sahu A, Jefford M, Lai-Kwon J, et al. CAPTEM in metastatic well-differentiated intermediate to high grade neuroendocrine tumors: A single centre experience. *J Oncol* 2019;2019:9032753. Available at:

<https://www.ncbi.nlm.nih.gov/pubmed/30915122>.

261. Chan JA, Blaszkowsky L, Stuart K, et al. A prospective, phase 1/2 study of everolimus and temozolomide in patients with advanced pancreatic neuroendocrine tumor. *Cancer* 2013;119:3212-3218. Available at: <https://www.ncbi.nlm.nih.gov/pubmed/23733618>.

262. Clewemar Antonodimitrakakis P, Sundin A, Wassberg C, et al. Streptozocin and 5-fluorouracil for the treatment of pancreatic neuroendocrine tumors: Efficacy, prognostic factors and toxicity. *Neuroendocrinology* 2016;103:345-353. Available at:

<https://www.ncbi.nlm.nih.gov/pubmed/26279284>.

263. Dilz LM, Denecke T, Steffen IG, et al. Streptozocin/5-fluorouracil chemotherapy is associated with durable response in patients with advanced pancreatic neuroendocrine tumours. *Eur J Cancer* 2015;51:1253-1262. Available at:

<https://www.ncbi.nlm.nih.gov/pubmed/25935542>.

264. Girot P, Baudin E, Senellart H, et al. Oxaliplatin and 5-fluorouracil (FOLFOX) in advanced well-differentiated digestive neuroendocrine tumors: A multicenter national retrospective study from the French Group of Endocrine Tumors (GTE). *J Clin Oncol* 2019;37. Available at:

265. Faure M, Niccoli P, Autret A, et al. Systemic chemotherapy with FOLFOX in metastatic grade 1/2 neuroendocrine cancer. *Mol Clin Oncol* 2017;6:44-48. Available at:

<https://www.ncbi.nlm.nih.gov/pubmed/28123727>.

266. Spada F, Antonuzzo L, Marconcini R, et al. Oxaliplatin-based chemotherapy in advanced neuroendocrine tumors: Clinical outcomes and preliminary correlation with biological factors. *Neuroendocrinology*

2016;103:806-814. Available at:

<https://www.ncbi.nlm.nih.gov/pubmed/26789262>.

267. Gulenchyn KY, Yao X, Asa SL, et al. Radionuclide therapy in neuroendocrine tumours: a systematic review. *Clin Oncol (R Coll Radiol)* 2012;24:294-308. Available at:

<https://www.ncbi.nlm.nih.gov/pubmed/22221516>.

268. Bloomston M, Muscarella P, Shah MH, et al. Cytoreduction results in high perioperative mortality and decreased survival in patients undergoing pancreatectomy for neuroendocrine tumors of the pancreas. *J Gastrointest Surg* 2006;10:1361-1370. Available at:

<https://www.ncbi.nlm.nih.gov/pubmed/17175455>.

269. Gomez D, Malik HZ, Al-Mukthar A, et al. Hepatic resection for metastatic gastrointestinal and pancreatic neuroendocrine tumours: outcome and prognostic predictors. *HPB (Oxford)* 2007;9:345-351. Available at:

<https://www.ncbi.nlm.nih.gov/pubmed/18345317>.

270. Pederzoli P, Falconi M, Bonora A, et al. Cytoreductive surgery in advanced endocrine tumours of the pancreas. *Ital J Gastroenterol Hepatol* 1999;31 Suppl 2:S207-212. Available at:

<https://www.ncbi.nlm.nih.gov/pubmed/10604132>.

271. Perry LJ, Stuart K, Stokes KR, Clouse ME. Hepatic arterial chemoembolization for metastatic neuroendocrine tumors. *Surgery* 1994;116:1111-1116; discussion 1116-1117. Available at:

<https://www.ncbi.nlm.nih.gov/pubmed/7985095>.

272. Devulapalli KK, Fidelman N, Soulen MC, et al. (90)Y Radioembolization for Hepatic Malignancy in Patients with Previous Biliary Intervention: Multicenter Analysis of Hepatobiliary Infections. *Radiology* 2018;288:774-781. Available at:

<https://www.ncbi.nlm.nih.gov/pubmed/29737954>.

273. Mathe Z, Tagkalos E, Paul A, et al. Liver transplantation for hepatic metastases of neuroendocrine pancreatic tumors: a survival-based analysis. *Transplantation* 2011;91:575-582. Available at:

<https://www.ncbi.nlm.nih.gov/pubmed/21200365>.



National
Comprehensive
Cancer
Network®

NCCN Guidelines Version 4.2021

Neuroendocrine and Adrenal Tumors

274. Klimstra DS, Modlin IR, Coppola D, et al. The pathologic classification of neuroendocrine tumors: a review of nomenclature, grading, and staging systems. *Pancreas* 2010;39:707-712. Available at: <https://www.ncbi.nlm.nih.gov/pubmed/20664470>.

275. Bellizzi AM. Assigning site of origin in metastatic neuroendocrine neoplasms: a clinically significant application of diagnostic immunohistochemistry. *Adv Anat Pathol* 2013;20:285-314. Available at: <https://www.ncbi.nlm.nih.gov/pubmed/23939147>.

276. Polish A, Vergo MT, Agulnik M. Management of neuroendocrine tumors of unknown origin. *J Natl Compr Canc Netw* 2011;9:1397-1402; quiz 1403. Available at: <https://www.ncbi.nlm.nih.gov/pubmed/22157557>.

277. Meko JB, Doherty GM, Siegel BA, Norton JA. Evaluation of somatostatin-receptor scintigraphy for detecting neuroendocrine tumors. *Surgery* 1996;120:975-983; discussion 983-974. Available at: <https://www.ncbi.nlm.nih.gov/pubmed/8957483>.

278. Wang SC, Parekh JR, Zuraek MB, et al. Identification of unknown primary tumors in patients with neuroendocrine liver metastases. *Arch Surg* 2010;145:276-280. Available at: <https://www.ncbi.nlm.nih.gov/pubmed/20231629>.

279. Coriat R, Walter T, Terris B, et al. Gastroenteropancreatic well-differentiated grade 3 neuroendocrine tumors: Review and position statement. *Oncologist* 2016;21:1191-1199. Available at: <https://www.ncbi.nlm.nih.gov/pubmed/27401895>.

280. Velayoudom-Cephise FL, Duvillard P, Foucan L, et al. Are G3 ENETS neuroendocrine neoplasms heterogeneous? *Endocr Relat Cancer* 2013;20:649-657. Available at: <https://www.ncbi.nlm.nih.gov/pubmed/23845449>.

281. Heetfeld M, Chougnet CN, Olsen IH, et al. Characteristics and treatment of patients with G3 gastroenteropancreatic neuroendocrine neoplasms. *Endocr Relat Cancer* 2015;22:657-664. Available at: <https://www.ncbi.nlm.nih.gov/pubmed/26113608>.

282. Tang LH, Basturk O, Sue JJ, Klimstra DS. A practical approach to the classification of WHO grade 3 (G3) well-differentiated neuroendocrine tumor (WD-NET) and poorly differentiated neuroendocrine carcinoma (PD-NEC) of the pancreas. *Am J Surg Pathol* 2016;40:1192-1202. Available at: <https://www.ncbi.nlm.nih.gov/pubmed/27259015>.

283. Tang LH, Untch BR, Reidy DL, et al. Well-differentiated neuroendocrine tumors with a morphologically apparent high-grade component: A pathway distinct from poorly differentiated neuroendocrine carcinomas. *Clin Cancer Res* 2016;22:1011-1017. Available at: <https://www.ncbi.nlm.nih.gov/pubmed/26482044>.

284. Yachida S, Vakiani E, White CM, et al. Small cell and large cell neuroendocrine carcinomas of the pancreas are genetically similar and distinct from well-differentiated pancreatic neuroendocrine tumors. *Am J Surg Pathol* 2012;36:173-184. Available at: <https://www.ncbi.nlm.nih.gov/pubmed/22251937>.

285. Konukiewicz B, Schlitter AM, Jesinghaus M, et al. Somatostatin receptor expression related to TP53 and RB1 alterations in pancreatic and extrapancreatic neuroendocrine neoplasms with a Ki67-index above 20. *Mod Pathol* 2017;30:587-598. Available at: <https://www.ncbi.nlm.nih.gov/pubmed/28059098>.

286. Merola E, Rinke A, Partelli S, et al. Surgery with Radical Intent: Is There an Indication for G3 Neuroendocrine Neoplasms? *Ann Surg Oncol* 2020;27:1348-1355. Available at: <https://www.ncbi.nlm.nih.gov/pubmed/31720931>.

287. Marabelle A, Fakih M, Lopez J, et al. Association of tumour mutational burden with outcomes in patients with advanced solid tumours treated with pembrolizumab: prospective biomarker analysis of the multicohort, open-label, phase 2 KEYNOTE-158 study. *Lancet Oncol* 2020;21:1353-1365. Available at: <https://www.ncbi.nlm.nih.gov/pubmed/32919526>.

288. Merino DM, McShane LM, Fabrizio D, et al. Establishing guidelines to harmonize tumor mutational burden (TMB): in silico assessment of variation in TMB quantification across diagnostic platforms: phase I of the



NCCN Guidelines Version 4.2021

Neuroendocrine and Adrenal Tumors

Friends of Cancer Research TMB Harmonization Project. J Immunother Cancer 2020;8. Available at:

<https://www.ncbi.nlm.nih.gov/pubmed/32217756>.

289. McGrail DJ, Pilie PG, Rashid NU, et al. High tumor mutation burden fails to predict immune checkpoint blockade response across all cancer types. Ann Oncol 2021;32:661-672. Available at:

<https://www.ncbi.nlm.nih.gov/pubmed/33736924>.

290. Rousseau B, Foote MB, Maron SB, et al. The spectrum of benefit from checkpoint blockade in hypermutated tumors. N Engl J Med 2021;384:1168-1170. Available at:

<https://www.ncbi.nlm.nih.gov/pubmed/33761214>.

291. Klein O, Kee D, Markman B, et al. Immunotherapy of ipilimumab and nivolumab in patients with advanced neuroendocrine tumors: A subgroup analysis of the CA209-538 clinical trial for rare cancers. Clin Cancer Res 2020;26:4454-4459. Available at:

<https://www.ncbi.nlm.nih.gov/pubmed/32532787>.

292. Hijioka S, Hosoda W, Matsuo K, et al. Rb Loss and KRAS mutation are predictors of the response to platinum-based chemotherapy in pancreatic neuroendocrine neoplasm with grade 3: A Japanese multicenter pancreatic NEN-G3 study. Clin Cancer Res 2017;23:4625-4632. Available at: <https://www.ncbi.nlm.nih.gov/pubmed/28455360>.

293. Dasari A, Mehta K, Byers LA, et al. Comparative study of lung and extrapulmonary poorly differentiated neuroendocrine carcinomas: A SEER database analysis of 162,983 cases. Cancer 2018;124:807-815. Available at: <https://www.ncbi.nlm.nih.gov/pubmed/29211313>.

294. Iwasa S, Morizane C, Okusaka T, et al. Cisplatin and etoposide as first-line chemotherapy for poorly differentiated neuroendocrine carcinoma of the hepatobiliary tract and pancreas. Jpn J Clin Oncol 2010;40:313-318. Available at: <https://www.ncbi.nlm.nih.gov/pubmed/20047862>.

295. Zhang P, Li J, Li J, et al. Etoposide and cisplatin versus irinotecan and cisplatin as the first-line therapy for patients with advanced, poorly differentiated gastroenteropancreatic neuroendocrine carcinoma: A

randomized phase 2 study. Cancer 2020;126 Suppl 9:2086-2092. Available at: <https://www.ncbi.nlm.nih.gov/pubmed/32293725>.

296. Frizziero M, Spada F, Lamarca A, et al. Carboplatin in combination with oral or intravenous etoposide for extra-pulmonary, poorly-differentiated neuroendocrine carcinomas. Neuroendocrinology 2019;109:100-112. Available at:

<https://www.ncbi.nlm.nih.gov/pubmed/30703770>.

297. Hadoux J, Malka D, Planchard D, et al. Post-first-line FOLFOX chemotherapy for grade 3 neuroendocrine carcinoma. Endocr Relat Cancer 2015;22:289-298. Available at:

<https://www.ncbi.nlm.nih.gov/pubmed/25770151>.

298. Hentic O, Hammel P, Couvelard A, et al. FOLFIRI regimen: an effective second-line chemotherapy after failure of etoposide-platinum combination in patients with neuroendocrine carcinomas grade 3. Endocr Relat Cancer 2012;19:751-757. Available at:

<https://www.ncbi.nlm.nih.gov/pubmed/22940375>.

299. Rogowski W, Wachula E, Gorzelak A, et al. Capecitabine and temozolomide combination for treatment of high-grade, well-differentiated neuroendocrine tumour and poorly-differentiated neuroendocrine carcinoma - retrospective analysis. Endokrynol Pol 2019;70:313-317. Available at: <https://www.ncbi.nlm.nih.gov/pubmed/30843182>.

300. Zhu J, Strosberg JR, Dropkin E, Strickler JH. Treatment of high-grade metastatic pancreatic neuroendocrine carcinoma with FOLFIRINOX. J Gastrointest Cancer 2015;46:166-169. Available at: <https://www.ncbi.nlm.nih.gov/pubmed/25662891>.

301. Borghesani M, Reni A, Zaninotto E, et al. Outcomes of upfront treatment with mFOLFIRINOX regimen in G3 GEP- NENs: A monocentric retrospective experience. 18th Annual ENETS Conference for the Diagnosis and Treatment of Neuroendocrine Tumor Disease. Virtual Conference; 2021. Available at:

302. McGarrah PW, Leventakos K, Hobday TJ, et al. Efficacy of second-line chemotherapy in extrapulmonary neuroendocrine carcinoma.



NCCN Guidelines Version 4.2021

Neuroendocrine and Adrenal Tumors

Pancreas 2020;49:529-533. Available at:

<https://www.ncbi.nlm.nih.gov/pubmed/32282766>.

303. Patel SP, Othus M, Chae YK, et al. A phase II basket trial of dual anti-CTLA-4 and anti-PD-1 blockade in rare tumors (DART SWOG 1609) in patients with nonpancreatic neuroendocrine tumors. Clin Cancer Res 2020;26:2290-2296. Available at:

<https://www.ncbi.nlm.nih.gov/pubmed/31969335>.

304. Patel SP, Mayerson E, Chae YK, et al. A phase II basket trial of dual anti-CTLA-4 and anti-PD-1 blockade in rare tumors (DART) SWOG S1609: High-grade neuroendocrine neoplasm cohort. Cancer 2021.

Available at: <https://www.ncbi.nlm.nih.gov/pubmed/33882143>.

305. Capdevila J, Teule A, López C, et al. A multi-cohort phase II study of durvalumab plus tremelimumab for the treatment of patients (pts) with advanced neuroendocrine neoplasms (NENs) of gastroenteropancreatic or lung origin: The DUNE trial (GETNE 1601) [Abstract]. Ann Oncol 2020;31:S711-S724. Available at: <https://oncologypro.esmo.org/meeting-resources/esmo-virtual-congress-2020/a-multi-cohort-phase-ii-study-of-durvalumab-plus-tremelimumab-for-the-treatment-of-patients-pts-with-advanced-neuroendocrine-neoplasms-nens-of>.

306. Marabelle A, Le DT, Ascierto PA, et al. Efficacy of pembrolizumab in patients with noncolorectal high microsatellite instability/mismatch repair-deficient cancer: Results from the phase II KEYNOTE-158 study. J Clin Oncol 2020;38:1-10. Available at:

<https://www.ncbi.nlm.nih.gov/pubmed/31682550>.

307. Fassnacht M, Kroiss M, Allolio B. Update in adrenocortical carcinoma. J Clin Endocrinol Metab 2013;98:4551-4564. Available at:

<https://www.ncbi.nlm.nih.gov/pubmed/24081734>.

308. Fassnacht M, Dekkers OM, Else T, et al. European Society of Endocrinology Clinical Practice Guidelines on the management of adrenocortical carcinoma in adults, in collaboration with the European Network for the Study of Adrenal Tumors. Eur J Endocrinol 2018;179:G1-G46. Available at: <https://www.ncbi.nlm.nih.gov/pubmed/30299884>.

309. Else T, Kim AC, Sabolch A, et al. Adrenocortical carcinoma. Endocr Rev 2014;35:282-326. Available at:

<https://www.ncbi.nlm.nih.gov/pubmed/24423978>.

310. Koch CA, Pacak K, Chrousos GP. The molecular pathogenesis of hereditary and sporadic adrenocortical and adrenomedullary tumors. J Clin Endocrinol Metab 2002;87:5367-5384. Available at:

<https://www.ncbi.nlm.nih.gov/pubmed/12466322>.

311. Lynch HT, Radford B, Lynch JF. SBLA syndrome revisited. Oncology 1990;47:75-79. Available at:

<https://www.ncbi.nlm.nih.gov/pubmed/2300390>.

312. Soon PS, McDonald KL, Robinson BG, Sidhu SB. Molecular markers and the pathogenesis of adrenocortical cancer. Oncologist 2008;13:548-561. Available at: <https://www.ncbi.nlm.nih.gov/pubmed/18515740>.

313. Brandi ML, Gagel RF, Angeli A, et al. Guidelines for diagnosis and therapy of MEN type 1 and type 2. J Clin Endocrinol Metab 2001;86:5658-5671. Available at: <https://www.ncbi.nlm.nih.gov/pubmed/11739416>.

314. Raymond VM, Everett JN, Furtado LV, et al. Adrenocortical carcinoma is a lynch syndrome-associated cancer. J Clin Oncol 2013;31:3012-3018. Available at:

<https://www.ncbi.nlm.nih.gov/pubmed/23752102>.

315. Petr EJ, Else T. Genetic predisposition to endocrine tumors: Diagnosis, surveillance and challenges in care. Semin Oncol 2016;43:582-590. Available at: <https://www.ncbi.nlm.nih.gov/pubmed/27899191>.

316. Ohgaki H, Kleihues P, Heitz PU. p53 mutations in sporadic adrenocortical tumors. Int J Cancer 1993;54:408-410. Available at:

<https://www.ncbi.nlm.nih.gov/pubmed/8509216>.

317. Reincke M, Karl M, Travis WH, et al. p53 mutations in human adrenocortical neoplasms: immunohistochemical and molecular studies. J Clin Endocrinol Metab 1994;78:790-794. Available at:

<https://www.ncbi.nlm.nih.gov/pubmed/8126158>.



NCCN Guidelines Version 4.2021

Neuroendocrine and Adrenal Tumors

318. Gicquel C, Bertagna X, Schneid H, et al. Rearrangements at the 11p15 locus and overexpression of insulin-like growth factor-II gene in sporadic adrenocortical tumors. *J Clin Endocrinol Metab* 1994;78:1444-1453. Available at: <http://www.ncbi.nlm.nih.gov/pubmed/7911125>.

319. Gicquel C, Raffin-Sanson ML, Gaston V, et al. Structural and functional abnormalities at 11p15 are associated with the malignant phenotype in sporadic adrenocortical tumors: study on a series of 82 tumors. *J Clin Endocrinol Metab* 1997;82:2559-2565. Available at: <http://www.ncbi.nlm.nih.gov/pubmed/9253334>.

320. Lenders JW, Duh QY, Eisenhofer G, et al. Pheochromocytoma and paraganglioma: an endocrine society clinical practice guideline. *J Clin Endocrinol Metab* 2014;99:1915-1942. Available at: <https://www.ncbi.nlm.nih.gov/pubmed/24893135>.

321. Nieman LK, Biller BM, Findling JW, et al. The diagnosis of Cushing's syndrome: an Endocrine Society Clinical Practice Guideline. *J Clin Endocrinol Metab* 2008;93:1526-1540. Available at: <https://www.ncbi.nlm.nih.gov/pubmed/18334580>.

322. Funder JW, Carey RM, Mantero F, et al. The management of primary aldosteronism: Case detection, diagnosis, and treatment: An Endocrine Society Clinical Practice Guideline. *J Clin Endocrinol Metab* 2016;101:1889-1916. Available at: <https://www.ncbi.nlm.nih.gov/pubmed/26934393>.

323. Plouin PF, Amar L, Dekkers OM, et al. European Society of Endocrinology Clinical Practice Guideline for long-term follow-up of patients operated on for a pheochromocytoma or a paraganglioma. *Eur J Endocrinol* 2016;174:G1-G10. Available at: <https://www.ncbi.nlm.nih.gov/pubmed/27048283>.

324. Fassnacht M, Arlt W, Bancos I, et al. Management of adrenal incidentalomas: European Society of Endocrinology Clinical Practice Guideline in collaboration with the European Network for the Study of Adrenal Tumors. *Eur J Endocrinol* 2016;175:G1-G34. Available at: <https://www.ncbi.nlm.nih.gov/pubmed/27390021>.

325. Ng CS, Altinmakas E, Wei W, et al. Combining washout and noncontrast data from adrenal protocol CT: Improving diagnostic performance. *Acad Radiol* 2018;25:861-868. Available at: <https://www.ncbi.nlm.nih.gov/pubmed/29398440>.

326. Caoili EM, Korobkin M, Francis IR, et al. Adrenal masses: characterization with combined unenhanced and delayed enhanced CT. *Radiology* 2002;222:629-633. Available at: <https://www.ncbi.nlm.nih.gov/pubmed/11867777>.

327. Williams TA, Reincke M. MANAGEMENT OF ENDOCRINE DISEASE: Diagnosis and management of primary aldosteronism: the Endocrine Society guideline 2016 revisited. *Eur J Endocrinol* 2018;179:R19-R29. Available at: <https://www.ncbi.nlm.nih.gov/pubmed/29674485>.

328. Vaidya A, Carey RM. Evolution of the primary aldosteronism syndrome: Updating the approach. *J Clin Endocrinol Metab* 2020;105. Available at: <https://www.ncbi.nlm.nih.gov/pubmed/32865201>.

329. Guignat L, Bertherat J. The diagnosis of Cushing's syndrome: an Endocrine Society Clinical Practice Guideline: commentary from a European perspective. *Eur J Endocrinol* 2010;163:9-13. Available at: <https://www.ncbi.nlm.nih.gov/pubmed/20375177>.

330. Nieman LK, Biller BM, Findling JW, et al. Treatment of Cushing's Syndrome: An Endocrine Society Clinical Practice Guideline. *J Clin Endocrinol Metab* 2015;100:2807-2831. Available at: <https://www.ncbi.nlm.nih.gov/pubmed/26222757>.

331. Zeiger MA, Thompson GB, Duh QY, et al. The American Association of Clinical Endocrinologists and American Association of Endocrine Surgeons medical guidelines for the management of adrenal incidentalomas. *Endocr Pract* 2009;15 Suppl 1:1-20. Available at: <https://www.ncbi.nlm.nih.gov/pubmed/19632967>.

332. Raymond VM, Else T, Everett JN, et al. Prevalence of germline TP53 mutations in a prospective series of unselected patients with



NCCN Guidelines Version 4.2021

Neuroendocrine and Adrenal Tumors

adrenocortical carcinoma. J Clin Endocrinol Metab 2013;98:E119-125. Available at: <https://www.ncbi.nlm.nih.gov/pubmed/23175693>.

333. Gaujoux S, Mihai R, joint working group of E, Ensaf. European Society of Endocrine Surgeons (ESES) and European Network for the Study of Adrenal Tumours (ENSAT) recommendations for the surgical management of adrenocortical carcinoma. Br J Surg 2017;104:358-376. Available at: <https://www.ncbi.nlm.nih.gov/pubmed/28199015>.

334. Autorino R, Bove P, De Sio M, et al. Open versus laparoscopic adrenalectomy for adrenocortical carcinoma: A meta-analysis of surgical and oncological outcomes. Ann Surg Oncol 2016;23:1195-1202. Available at: <https://www.ncbi.nlm.nih.gov/pubmed/26480850>.

335. Tang Y, Liu Z, Zou Z, et al. Benefits of adjuvant mitotane after resection of adrenocortical carcinoma: A systematic review and meta-analysis. Biomed Res Int 2018;2018:9362108. Available at: <https://www.ncbi.nlm.nih.gov/pubmed/29967789>.

336. Barzon L, Fallo F, Sonino N, et al. Adrenocortical carcinoma: experience in 45 patients. Oncology 1997;54:490-496. Available at: <https://www.ncbi.nlm.nih.gov/pubmed/9394846>.

337. Baudin E, Pellegriti G, Bonnay M, et al. Impact of monitoring plasma 1,1-dichlorodiphenildichloroethane (o,p'DDD) levels on the treatment of patients with adrenocortical carcinoma. Cancer 2001;92:1385-1392. Available at: <https://www.ncbi.nlm.nih.gov/pubmed/11745214>.

338. Haak HR, Hermans J, van de Velde CJ, et al. Optimal treatment of adrenocortical carcinoma with mitotane: results in a consecutive series of 96 patients. Br J Cancer 1994;69:947-951. Available at: <https://www.ncbi.nlm.nih.gov/pubmed/8180029>.

339. Veytsman I, Nieman L, Fojo T. Management of endocrine manifestations and the use of mitotane as a chemotherapeutic agent for adrenocortical carcinoma. J Clin Oncol 2009;27:4619-4629. Available at: <https://www.ncbi.nlm.nih.gov/pubmed/19667279>.

340. Raj N, Zheng Y, Kelly V, et al. PD-1 blockade in advanced adrenocortical carcinoma. J Clin Oncol 2020;38:71-80. Available at: <https://www.ncbi.nlm.nih.gov/pubmed/31644329>.

341. Habra MA, Stephen B, Campbell M, et al. Phase II clinical trial of pembrolizumab efficacy and safety in advanced adrenocortical carcinoma. J Immunother Cancer 2019;7:253. Available at: <https://www.ncbi.nlm.nih.gov/pubmed/31533818>.

342. Naing A, Meric-Bernstam F, Stephen B, et al. Phase 2 study of pembrolizumab in patients with advanced rare cancers. J Immunother Cancer 2020;8. Available at: <https://www.ncbi.nlm.nih.gov/pubmed/32188704>.

343. Berruti A, Terzolo M, Sperone P, et al. Etoposide, doxorubicin and cisplatin plus mitotane in the treatment of advanced adrenocortical carcinoma: a large prospective phase II trial. Endocr Relat Cancer 2005;12:657-666. Available at: <https://www.ncbi.nlm.nih.gov/pubmed/16172198>.

344. Khan TS, Imam H, Juhlin C, et al. Streptozocin and o,p'DDD in the treatment of adrenocortical cancer patients: long-term survival in its adjuvant use. Ann Oncol 2000;11:1281-1287. Available at: <http://www.ncbi.nlm.nih.gov/pubmed/11106117>.

345. Fassnacht M, Terzolo M, Allolio B, et al. Combination chemotherapy in advanced adrenocortical carcinoma. N Engl J Med 2012;366:2189-2197. Available at: <https://www.ncbi.nlm.nih.gov/pubmed/22551107>.

346. Chen H, Sippel RS, O'Dorisio MS, et al. The North American Neuroendocrine Tumor Society consensus guideline for the diagnosis and management of neuroendocrine tumors: pheochromocytoma, paraganglioma, and medullary thyroid cancer. Pancreas 2010;39:775-783. Available at: <https://www.ncbi.nlm.nih.gov/pubmed/20664475>.

347. Lenders JWM, Eisenhofer G. Update on modern management of pheochromocytoma and paraganglioma. Endocrinol Metab (Seoul) 2017;32:152-161. Available at: <https://www.ncbi.nlm.nih.gov/pubmed/28685506>.



NCCN Guidelines Version 4.2021

Neuroendocrine and Adrenal Tumors

348. Turkova H, Prodanov T, Maly M, et al. Characteristics and outcomes of metastatic Sdhb and sporadic pheochromocytoma/paraganglioma: An National Institutes of Health study. *Endocr Pract* 2016;22:302-314. Available at: <https://www.ncbi.nlm.nih.gov/pubmed/26523625>.

349. King KS, Prodanov T, Kantorovich V, et al. Metastatic pheochromocytoma/paraganglioma related to primary tumor development in childhood or adolescence: significant link to SDHB mutations. *J Clin Oncol* 2011;29:4137-4142. Available at: <https://www.ncbi.nlm.nih.gov/pubmed/21969497>.

350. Hamidi O, Young WF, Jr., Gruber L, et al. Outcomes of patients with metastatic pheochromocytoma and paraganglioma: A systematic review and meta-analysis. *Clin Endocrinol (Oxf)* 2017;87:440-450. Available at: <https://www.ncbi.nlm.nih.gov/pubmed/28746746>.

351. Nicolas M, Dahia P. Predictors of outcome in pheochromocytomas and paragangliomas. *F1000Res* 2017;6:2160. Available at: <https://www.ncbi.nlm.nih.gov/pubmed/29333259>.

352. Hamidi O, Young WF, Jr., Iniguez-Ariza NM, et al. Malignant pheochromocytoma and paraganglioma: 272 patients over 55 years. *J Clin Endocrinol Metab* 2017;102:3296-3305. Available at: <https://www.ncbi.nlm.nih.gov/pubmed/28605453>.

353. Neary NM, King KS, Pacak K. Drugs and pheochromocytoma--don't be fooled by every elevated metanephrine. *N Engl J Med* 2011;364:2268-2270. Available at: <http://www.ncbi.nlm.nih.gov/pubmed/21651412>.

354. Pacak K. Pheochromocytoma: a catecholamine and oxidative stress disorder. *Endocr Regul* 2011;45:65-90. Available at: <https://www.ncbi.nlm.nih.gov/pubmed/21615192>.

355. Fishbein L, Merrill S, Fraker DL, et al. Inherited mutations in pheochromocytoma and paraganglioma: why all patients should be offered genetic testing. *Ann Surg Oncol* 2013;20:1444-1450. Available at: <https://www.ncbi.nlm.nih.gov/pubmed/23512077>.

356. Pacak K, Jochmanova I, Prodanov T, et al. New syndrome of paraganglioma and somatostatinoma associated with polycythemia. *J Clin Oncol* 2013;31:1690-1698. Available at: <https://www.ncbi.nlm.nih.gov/pubmed/23509317>.

357. Zhuang Z, Yang C, Lorenzo F, et al. Somatic HIF2A gain-of-function mutations in paraganglioma with polycythemia. *N Engl J Med* 2012;367:922-930. Available at: <https://www.ncbi.nlm.nih.gov/pubmed/22931260>.

358. Burnichon N, Cascon A, Schiavi F, et al. MAX mutations cause hereditary and sporadic pheochromocytoma and paraganglioma. *Clin Cancer Res* 2012;18:2828-2837. Available at: <https://www.ncbi.nlm.nih.gov/pubmed/22452945>.

359. Cascon A, Comino-Mendez I, Curras-Freixes M, et al. Whole-exome sequencing identifies MDH2 as a new familial paraganglioma gene. *J Natl Cancer Inst* 2015;107. Available at: <https://www.ncbi.nlm.nih.gov/pubmed/25766404>.

360. van Hulsteijn LT, Dekkers OM, Hes FJ, et al. Risk of malignant paraganglioma in SDHB-mutation and SDHD-mutation carriers: a systematic review and meta-analysis. *J Med Genet* 2012;49:768-776. Available at: <https://www.ncbi.nlm.nih.gov/pubmed/23099648>.

361. Else T, S. G, Fishbein L. Hereditary Paraganglioma-Pheochromocytoma Syndromes. 2008 May 21 [Updated 2018 Oct 4]. In: Adam MP, Ardinger HH, Pagon RA, et al., editors. *GeneReviews®* [Internet]. Seattle (WA): University of Washington, Seattle; 1993-2018. Available at: <http://www.ncbi.nlm.nih.gov/books/NBK1548/>. Accessed October 30, 2018.

362. Conzo G, Musella M, Corcione F, et al. Laparoscopic adrenalectomy, a safe procedure for pheochromocytoma. A retrospective review of clinical series. *Int J Surg* 2013;11:152-156. Available at: <https://www.ncbi.nlm.nih.gov/pubmed/23267853>.

363. Grant CS. Pheochromocytoma. In: Clark OH, Duh QY, eds. *Textbook of Endocrine Surgery*. Philadelphia, PA: WB Saunders 1997.



NCCN Guidelines Version 4.2021

Neuroendocrine and Adrenal Tumors

364. Wang W, Li P, Wang Y, et al. Effectiveness and safety of laparoscopic adrenalectomy of large pheochromocytoma: a prospective, nonrandomized, controlled study. *Am J Surg* 2015;210:230-235. Available at: <https://www.ncbi.nlm.nih.gov/pubmed/25952614>.

365. Krempf M, Lumbroso J, Mornex R, et al. Use of m-[131I]iodobenzylguanidine in the treatment of malignant pheochromocytoma. *J Clin Endocrinol Metab* 1991;72:455-461. Available at: <http://www.ncbi.nlm.nih.gov/pubmed/1991814>.

366. Rose B, Matthay KK, Price D, et al. High-dose 131I-metaiodobenzylguanidine therapy for 12 patients with malignant pheochromocytoma. *Cancer* 2003;98:239-248. Available at: <https://www.ncbi.nlm.nih.gov/pubmed/12872341>.

367. Pryma D, Chin B, Noto R, et al. Azedra (iobenguane I 131) in patients with malignant, recurrent and/or unresectable pheochromocytoma or paraganglioma (PPGL): Updated efficacy and safety results from a multi-center, open-label, pivotal phase 2 study. *Journal of Clinical Oncology* 2018;36:4005-4005. Available at: http://ascopubs.org/doi/abs/10.1200/JCO.2018.36.15_suppl.4005.

368. Jimenez C CB, Noto RB et al. Azedra® (iobenguane I 131) in patients with metastatic and/or recurrent and/or unresectable pheochromocytoma or paraganglioma: biochemical tumor marker results of a multicenter, open-label pivotal phase 2b study. Abstract OR02-5. *Endocrine Reviews* 2018;39. Available at: <https://www.endocrine.org/meetings/endo-annual-meetings/abstract-details?ID=43345>.

369. Pryma DA, Chin BB, Noto RB, et al. Efficacy and safety of high-specific-activity (131)I-MIBG therapy in patients with advanced pheochromocytoma or paraganglioma. *J Nucl Med* 2019;60:623-630. Available at: <https://www.ncbi.nlm.nih.gov/pubmed/30291194>.

370. Kong G, Grozinsky-Glasberg S, Hofman MS, et al. Efficacy of peptide receptor radionuclide therapy for functional metastatic paraganglioma and pheochromocytoma. *J Clin Endocrinol Metab* 2017;102:3278-3287. Available at: <https://www.ncbi.nlm.nih.gov/pubmed/28605448>.

371. Satapathy S, Mittal BR, Bhansali A. 'Peptide receptor radionuclide therapy in the management of advanced pheochromocytoma and paraganglioma: A systematic review and meta-analysis'. *Clin Endocrinol (Oxf)* 2019;91:718-727. Available at: <https://www.ncbi.nlm.nih.gov/pubmed/31569282>.

372. Nastos K, Cheung VTF, Toumpanakis C, et al. Peptide receptor radionuclide treatment and (131)I-MIBG in the management of patients with metastatic/progressive phaeochromocytomas and paragangliomas. *J Surg Oncol* 2017;115:425-434. Available at: <https://www.ncbi.nlm.nih.gov/pubmed/28166370>.

373. Loh L, Lim D, Loke K, Ng D. PRRT for malignant pheochromocytomas and paragangliomas: The Singapore General Hospital Experience. Abstract N9. *Neuroendocrinology* 2016;103:93. Available at: <https://www.karger.com/Journal/Issue/272015>

<https://www.enets.org/1538592159241.d.f.613.pdf>.

374. Smit Duijzentkunst D, Kwekkeboom D. Treatment of paragangliomas with lutetium-177-octreotate based peptide receptor radionuclide therapy. Abstract N16. *Neuroendocrinology* 2017;105:254. Available at: <https://www.karger.com/Article/Abstract/484263>

<https://www.karger.com/Article/Pdf/484263>.

375. Prasad V, Zachert C, Schuchardt C, et al. Peptide receptor radionuclide therapy (PRRT) for progressive, somatostatin receptor positive pheochromocytoma/paraganglioma. Abstract from the Society of Nuclear Medicine, Inc. *J Nucl Med* 2008;49:101. Available at: http://jnm.snmjournals.org/content/49/supplement_1/101P.4.

376. Pinato DJ, Black JR, Ramaswami R, et al. Peptide receptor radionuclide therapy for metastatic paragangliomas. *Med Oncol* 2016;33:47. Available at: <https://www.ncbi.nlm.nih.gov/pubmed/27059363>.

377. van Essen M, Krenning EP, Kooij PP, et al. Effects of therapy with [177Lu-DOTA0, Tyr3]octreotate in patients with paraganglioma, meningioma, small cell lung carcinoma, and melanoma. *J Nucl Med*



NCCN Guidelines Version 4.2021

Neuroendocrine and Adrenal Tumors

2006;47:1599-1606. Available at:

<https://www.ncbi.nlm.nih.gov/pubmed/17015894>.

378. Averbuch SD, Steakley CS, Young RC, et al. Malignant pheochromocytoma: effective treatment with a combination of cyclophosphamide, vincristine, and dacarbazine. *Ann Intern Med* 1988;109:267-273. Available at:

<https://www.ncbi.nlm.nih.gov/pubmed/3395037>.

379. Ayala-Ramirez M, Feng L, Habra MA, et al. Clinical benefits of systemic chemotherapy for patients with metastatic pheochromocytomas or sympathetic extra-adrenal paragangliomas: insights from the largest single-institutional experience. *Cancer* 2012;118:2804-2812. Available at:

<https://www.ncbi.nlm.nih.gov/pubmed/22006217>.

380. Hadoux J, Favier J, Scoazec JY, et al. SDHB mutations are associated with response to temozolomide in patients with metastatic pheochromocytoma or paraganglioma. *Int J Cancer* 2014;135:2711-2720. Available at: <https://www.ncbi.nlm.nih.gov/pubmed/24752622>.

381. Tanabe A, Naruse M, Nomura K, et al. Combination chemotherapy with cyclophosphamide, vincristine, and dacarbazine in patients with malignant pheochromocytoma and paraganglioma. *Horm Cancer* 2013;4:103-110. Available at:

<https://www.ncbi.nlm.nih.gov/pubmed/23361939>.

382. Yoshinaga K, Oriuchi N, Wakabayashi H, et al. Effects and safety of (1)(3)(1)I-metaiodobenzylguanidine (MIBG) radiotherapy in malignant neuroendocrine tumors: results from a multicenter observational registry. *Endocr J* 2014;61:1171-1180. Available at:

<https://www.ncbi.nlm.nih.gov/pubmed/25214026>.

383. van Hulsteijn LT, Niemeijer ND, Dekkers OM, Corssmit EP. (131)I-MIBG therapy for malignant paraganglioma and pheochromocytoma: systematic review and meta-analysis. *Clin Endocrinol (Oxf)* 2014;80:487-501. Available at: <https://www.ncbi.nlm.nih.gov/pubmed/24118038>.

384. Larsson C, Skogseid B, Oberg K, et al. Multiple endocrine neoplasia type 1 gene maps to chromosome 11 and is lost in insulinoma. *Nature*

1988;332:85-87. Available at:

<https://www.ncbi.nlm.nih.gov/pubmed/2894610>.

385. Minoletti F, Butti MG, Coronelli S, et al. The two genes generating RET/PTC3 are localized in chromosomal band 10q11.2. *Genes Chromosomes Cancer* 1994;11:51-57. Available at:

<https://www.ncbi.nlm.nih.gov/pubmed/7529046>.

386. Hofstra RM, Landsvater RM, Ceccherini I, et al. A mutation in the RET proto-oncogene associated with multiple endocrine neoplasia type 2B and sporadic medullary thyroid carcinoma. *Nature* 1994;367:375-376.

Available at: <https://www.ncbi.nlm.nih.gov/pubmed/7906866>.

387. Giusti F, Marini F, Brandi ML. Multiple Endocrine Neoplasia Type 1. 2005 Aug 31 [Updated 2017 Dec 14]. In: Adam MP, Ardinger HH, Pagon RA, et al., editors. *GeneReviews®* [Internet]. Seattle (WA): University of Washington, Seattle; 1993-2018. Available at:

<http://www.ncbi.nlm.nih.gov/books/NBK1538/>. Accessed March 19, 2018.

388. Thakker RV, Newey PJ, Walls GV, et al. Clinical practice guidelines for multiple endocrine neoplasia type 1 (MEN1). *J Clin Endocrinol Metab* 2012;97:2990-3011. Available at:

<https://www.ncbi.nlm.nih.gov/pubmed/22723327>.

389. Niederle B, Selberherr A, Bartsch D, et al. Multiple endocrine neoplasia type 1 (MEN1) and the pancreas - Diagnosis and treatment of functioning and non-functioning pancreatic and duodenal neuroendocrine neoplasia within the MEN1 syndrome - An international consensus statement. *Neuroendocrinology* 2020. Available at:

<https://www.ncbi.nlm.nih.gov/pubmed/32971521>.

390. Mitchell BK, Merrell RC, Kinder BK. Localization studies in patients with hyperparathyroidism. *Surg Clin North Am* 1995;75:483-498. Available at: <https://www.ncbi.nlm.nih.gov/pubmed/7747254>.

391. Wei JP, Burke GJ, Mansberger AR, Jr. Preoperative imaging of abnormal parathyroid glands in patients with hyperparathyroid disease using combination Tc-99m-pertechnetate and Tc-99m-sestamibi



NCCN Guidelines Version 4.2021

Neuroendocrine and Adrenal Tumors

radionuclide scans. *Ann Surg* 1994;219:568-572; discussion 572-563. Available at: <https://www.ncbi.nlm.nih.gov/pubmed/8185405>.

392. Lavelly WC, Goetze S, Friedman KP, et al. Comparison of SPECT/CT, SPECT, and planar imaging with single- and dual-phase (99m)Tc-sestamibi parathyroid scintigraphy. *J Nucl Med* 2007;48:1084-1089. Available at: <https://www.ncbi.nlm.nih.gov/pubmed/17574983>.

393. Bann DV, Zacharia T, Goldenberg D, Goyal N. Parathyroid localization using 4D-computed tomography. *Ear Nose Throat J* 2015;94:E55-57. Available at: <https://www.ncbi.nlm.nih.gov/pubmed/25923289>.

394. Kebebew E, Clark OH. Parathyroid adenoma, hyperplasia, and carcinoma: localization, technical details of primary neck exploration, and treatment of hypercalcemic crisis. *Surg Oncol Clin N Am* 1998;7:721-748. Available at: <https://www.ncbi.nlm.nih.gov/pubmed/9735131>.

395. Wells SA, Jr., Ellis GJ, Gunnells JC, et al. Parathyroid autotransplantation in primary parathyroid hyperplasia. *N Engl J Med* 1976;295:57-62. Available at: <https://www.ncbi.nlm.nih.gov/pubmed/1272325>.

396. Wilhelm SM, Wang TS, Ruan DT, et al. The American association of endocrine surgeons guidelines for definitive management of primary hyperparathyroidism. *JAMA Surgery* 2016;151:959-968. Available at: <http://dx.doi.org/10.1001/jamasurg.2016.2310>.

397. Lairmore TC, Govednik CM, Quinn CE, et al. A randomized, prospective trial of operative treatments for hyperparathyroidism in patients with multiple endocrine neoplasia type 1. *Surgery* 2014;156:1326-1334; discussion 1334-1325. Available at: <https://www.ncbi.nlm.nih.gov/pubmed/25262224>.

398. Adkisson CD, Stauffer JA, Bowers SP, et al. What extent of pancreatic resection do patients with MEN-1 require? *JOP* 2012;13:402-408. Available at: <https://www.ncbi.nlm.nih.gov/pubmed/22797396>.

399. Montenegro FL, Lourenco DM, Jr., Tavares MR, et al. Total parathyroidectomy in a large cohort of cases with hyperparathyroidism associated with multiple endocrine neoplasia type 1: experience from a single academic center. *Clinics (Sao Paulo)* 2012;67 Suppl 1:131-139. Available at: <https://www.ncbi.nlm.nih.gov/pubmed/22584718>.

400. Faggiano A, Modica R, Lo Calzo F, et al. Lanreotide Therapy vs Active Surveillance in MEN1-Related Pancreatic Neuroendocrine Tumors < 2 Centimeters. *J Clin Endocrinol Metab* 2020;105. Available at: <https://www.ncbi.nlm.nih.gov/pubmed/31586182>.

401. Eng C, Smith DP, Mulligan LM, et al. A novel point mutation in the tyrosine kinase domain of the RET proto-oncogene in sporadic medullary thyroid carcinoma and in a family with FMTC. *Oncogene* 1995;10:509-513. Available at: <https://www.ncbi.nlm.nih.gov/pubmed/7845675>.

402. American Thyroid Association Guidelines Task F, Kloos RT, Eng C, et al. Medullary thyroid cancer: management guidelines of the American Thyroid Association. *Thyroid* 2009;19:565-612. Available at: <https://www.ncbi.nlm.nih.gov/pubmed/19469690>.

403. Marquard J, Eng C. Multiple Endocrine Neoplasia Type 2. 1999 Sep 27 [Updated 2015 Jun 25]. In: Adam MP, Ardinger HH, Pagon RA, et al., editors. *GeneReviews®* [Internet]. Seattle (WA): University of Washington, Seattle; 1993-2018. Available at: <http://www.ncbi.nlm.nih.gov/books/NBK1257/>. Accessed March 19, 2018.

404. Wells SA, Jr., Asa SL, Dralle H, et al. Revised American Thyroid Association guidelines for the management of medullary thyroid carcinoma. *Thyroid* 2015;25:567-610. Available at: <https://www.ncbi.nlm.nih.gov/pubmed/25810047>.

405. Machens A, Niccoli-Sire P, Hoegel J, et al. Early malignant progression of hereditary medullary thyroid cancer. *N Engl J Med* 2003;349:1517-1525. Available at: <https://www.ncbi.nlm.nih.gov/pubmed/14561794>.

406. Shepet K, Alhefdhi A, Lai N, et al. Hereditary medullary thyroid cancer: age-appropriate thyroidectomy improves disease-free survival.



Ann Surg Oncol 2013;20:1451-1455. Available at:
<https://www.ncbi.nlm.nih.gov/pubmed/23188542>.

407. Skinner MA, Moley JA, Dilley WG, et al. Prophylactic thyroidectomy in multiple endocrine neoplasia type 2A. N Engl J Med 2005;353:1105-1113. Available at: <https://www.ncbi.nlm.nih.gov/pubmed/16162881>.

408. Castinetti F, Qi XP, Walz MK, et al. Outcomes of adrenal-sparing surgery or total adrenalectomy in pheochromocytoma associated with multiple endocrine neoplasia type 2: an international retrospective population-based study. Lancet Oncol 2014;15:648-655. Available at: <https://www.ncbi.nlm.nih.gov/pubmed/24745698>.

409. Kulke MH, Siu LL, Tepper JE, et al. Future directions in the treatment of neuroendocrine tumors: consensus report of the National Cancer Institute Neuroendocrine Tumor clinical trials planning meeting. J Clin Oncol 2011;29:934-943. Available at: <https://www.ncbi.nlm.nih.gov/pubmed/21263089>.